

## PATIENT

Fluffy II Guido

## PRESENTING CLINICAL SIGNS

History: Heart murmur, hx of urinary bladder stones, elevated ALKP. No current meds  
Abnormal PE/Chem/CBC/UA Results: ALKP 537

## SPECIES

Canine

## ULTRASONOGRAPHIC EXAMINATION OF THE HEART

The echocardiogram in this patient demonstrated normal **left atrial** size based on 3 different LA measurement methods. Chamber volumes and echogenicity were normal. The cranial and caudal **mitral** valve leaflets presented vegetative thickening consistent with endocardiosis. Doppler indicated measurable insufficiency that is peripheral and considered mild. The **left ventricle** presented thicknesses with linear contour and was not dilated nor restricted. The **myocardium** presented normal echogenicity without subjective evidence of significant fibrotic or ischemic disease. **Contractility** of the ventricular walls was adequate and in normal range for this patient evidenced by the fractional shortening measurement and subjective evaluation of the different regions of the myocardium. **Aortic** insufficiency was noted and considered minor. The **right atrium** and auricle revealed normal size, structure and content. No evidence of masses was noted or chamber overload. **Tricuspid** insufficiency jet was peripheral and mild. The **right ventricle** was of normal size (1/3 diameter of LV), chordae structure, myocardial echogenicity and thickness. **Pulmonic** tract assessment revealed normal valve structure, laminar flow, and diameter (approx. 1:1 pa/ao ratio). No visible **pericardial** or free pleura fluid was noted. No echographically detectable evidence of infiltrative disease was visible. The cranial **mediastinum and pericardial regions** were free of masses in the visible window.

## BREED

Norwich Terrier Mix

## SEX

Neutered male

## AGE

8 years

## WEIGHT

27 lbs

## INTERPRETED BY

Eric Lindquist, DMV  
DABVP, Cert. IVUSS

## IMAGING PERFORMED BY

Shari Reffi, CVT

## HOSPITAL NAME

Animal Hospital of  
Roxbury

## REFERRING VET

Dr. Hickenbottom

CANINE CARDIAC PARAMETERS	MR VMAX (m/s)	TR VMAX (m/s)	LA/AO (Boon method)	LA/AO (Heart Base; Swe)	FS (%)	EF (%)	EPSS (cm)
NORMAL PARAMETER	4.5-5.5	<2.7	1.3	<1.6	28-40	40-100	<0.6
PATIENT	5.3	2.29	1.32	1.38			NM
CANINE CARDIAC PARAMETERS	HR (BPM)	AV VMAX (m/s)	PV MAX (m/s)	BODY WEIGHT	LA 2D short axis Base view (cm)	LVIDd Avg; 2D and m- mode short axis (cm)	LVIDs Avg; 2D and m-mode short axis (cm)
NORMAL PARAMETER	50-100	0.7-1.7	0.7-1.6	BELOW	BELOW	BELOW	BELOW
PATIENT		>5.0		27 lbs	1.92		

## INVOICE

31676

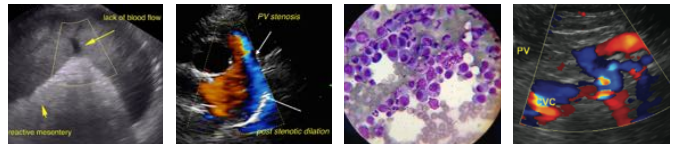
## DATE

6/30/22

## ULTRASONOGRAPHIC EXAMINATION OF THE ABDOMEN

### Urinary System

The apical **urinary bladder** wall was thickened and measured 0.65 cm. There were at least two calculi that measured up to 0.5 cm. Ureteral papillae were normal.



**PATIENT**

Fluffy II Guido

**SPECIES**

Canine

**BREED**

Norwich Terrier Mix

**SEX**

Neutered male

**AGE**

8 years

**WEIGHT**

27 lbs

**INTERPRETED BY**

Eric Lindquist, DMV  
DABVP, Cert. IVUSS

**IMAGING PERFORMED BY**

Shari Reffi, CVT

**HOSPITAL NAME**

Animal Hospital of  
Roxbury

**REFERRING VET**

Dr. Hickenbottom

**INVOICE**

31676

**DATE**

6/30/22

The **kidneys** revealed largely normal size and structure, corticomedullary definition and ratio (cortex 1/3 of medulla) were essentially maintained with some age-related loss of curvilinear patterns regarding the capsule and C/M junction. The cortices presented largely uniform texture with some increased echogenicity expected for his age patient. Medullary structure differed distinctly from that of the cortex and no evidence of pelvic dilation was present. Slight mineralization was noted in the kidneys. The right kidney measured 4.44 cm. The left kidney measured 4.22 cm.

**Adrenal Glands**

Both **adrenal glands** were visualized and recognized as having normal shape, size, position and echogenicity for this breed. The phrenic vasculature, glandular echogenicity and detail were unremarkable. Capsule, cortex, and medullary definition were normal for this age patient. The right adrenal gland measured 1.96 x 0.94 cm at the cranial pole and 0.63 cm at the caudal pole. The left adrenal gland measured 2.04 x 0.43 cm at the cranial pole and 0.52 cm at the caudal pole.

**Spleen**

The **spleen** was expansive with mixed, hypoechoic mass that measured 3.0 cm and was deriving from the mid caudal body.

**Liver**

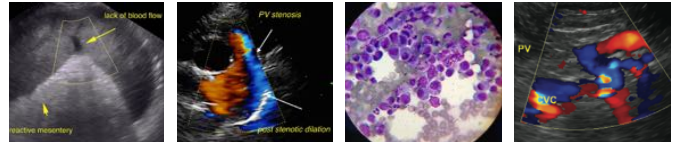
The **liver** images submitted revealed subjectively normal liver size, contour, and structure. Parenchymal echogenicity was naturally coarse and hypoechoic to the spleen. Vascular and biliary tracts were of normal volume with no evidence of congestion. The gallbladder presented acceptably thin walls with primarily anechoic content. The cystic and common bile ducts were normal. No pathological hepatic lymphadenopathy was evident. No overt structural evidence of inflammatory, infiltrative or regenerative pathology was evident.

**Gastrointestinal**

Examination of the **gastrointestinal tract** revealed a stomach and intestine free of stasis, of normal wall thickness, acceptable curvilinear mural detail, and peristaltic activity. Small and large intestine demonstrated normal luminal chyme and stool consistency respectively. No obstructive or overt infiltrative disease was noted. No associated abnormal lymphatic activity was noted.

**Pancreas**

The base and limbs of the **pancreas** were observed to be largely isoechoic to surrounding omental fat. Pancreatic duct and capsular contour were acceptably normal and parenchyma respected normal curvilinear patterns. No overt evidence of active inflammatory or neoplastic disease was noted.



**PATIENT**  
Fluffy II Guido

**SPECIES**  
Canine

**BREED**  
Norwich Terrier Mix

**SEX**  
Neutered male

**AGE**  
8 years

**WEIGHT**  
27 lbs

**ULTRASONOGRAPHIC FINDINGS**

Stage B1 valvular disease, compensated.

Splenic mass. Differentials include hemangiosarcoma, benign hematoma or hyperplasia with a less likely potential of round cell neoplasia.

Bladder calculi.

Chronic cystitis bladder pattern.

**INTERPRETATION OF THE FINDINGS & FURTHER RECOMMENDATIONS**

The heart is stable without clinical disease. No overt contraindication for anesthesia of brief to moderate duration. I suggest Torbutrol premed, Propofol induction, Isoflor maintenance or similar protocol if anesthesia is desired. Blood pressure recommended if not already performed and target white coat negative systolic pressure of < 160 mmHg. If higher than this ACE-inhibitor is suggested to reach this level. Recheck echocardiogram is recommended in 6 months, earlier if murmur grade increases or clinical signs initiate.

I recommend splenectomy, cystotomy, stone analysis and culture. Apical resection of the cranial third of the urinary bladder may be appropriate in this patient given the chronic thickening. Bladder lavage is recommended at the time of surgery.

**INTERPRETED BY**

Eric Lindquist, DMV  
DABVP, Cert. IVUSS

**IMAGING PERFORMED BY**

Shari Reffi, CVT

**HOSPITAL NAME**

Animal Hospital of  
Roxbury

**REFERRING VET**

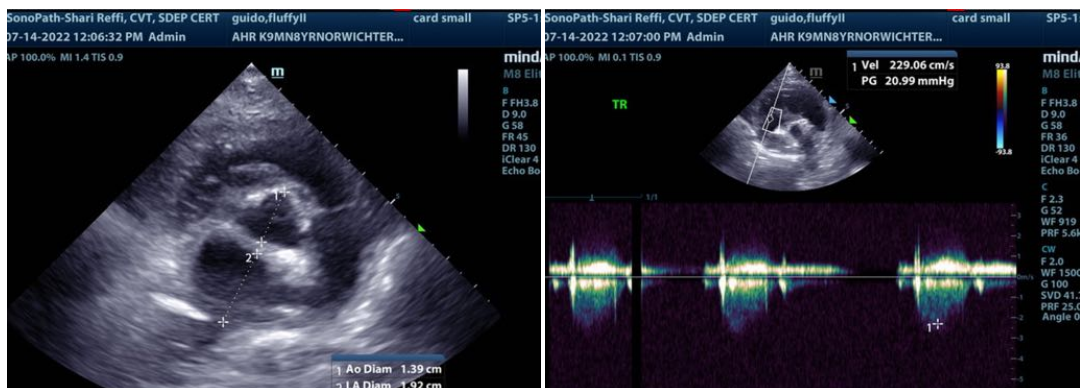
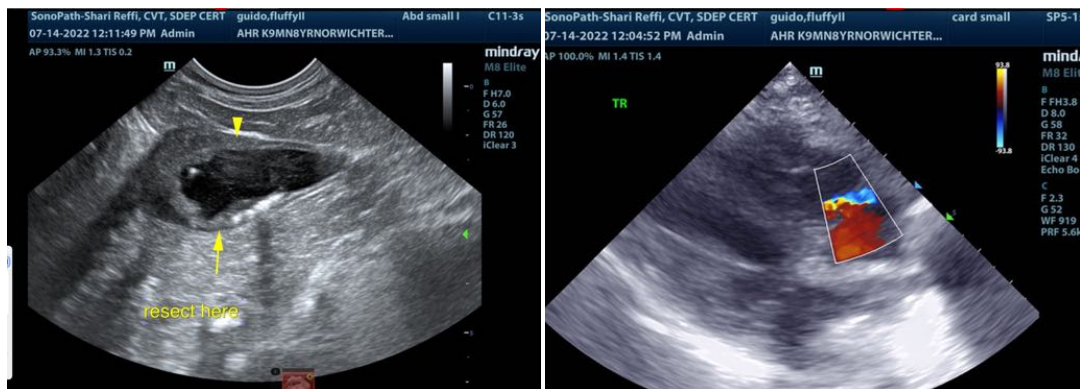
Dr. Hickenbottom

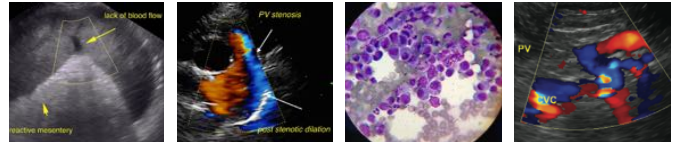
**INVOICE**

31676

**DATE**

6/30/22





**PATIENT**

Fluffy II Guido

**SPECIES**

Canine

**BREED**

Norwich Terrier Mix

**SEX**

Neutered male

**AGE**

8 years

**WEIGHT**

27 lbs

**INTERPRETED BY**

Eric Lindquist, DMV  
DABVP, Cert. IVUSS

**IMAGING PERFORMED BY**

Shari Reffi, CVT

**HOSPITAL NAME**

Animal Hospital of  
Roxbury

**REFERRING VET**

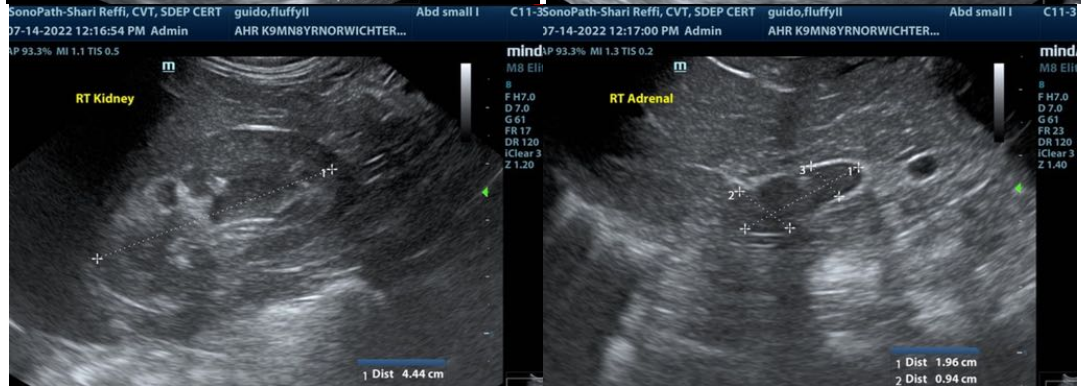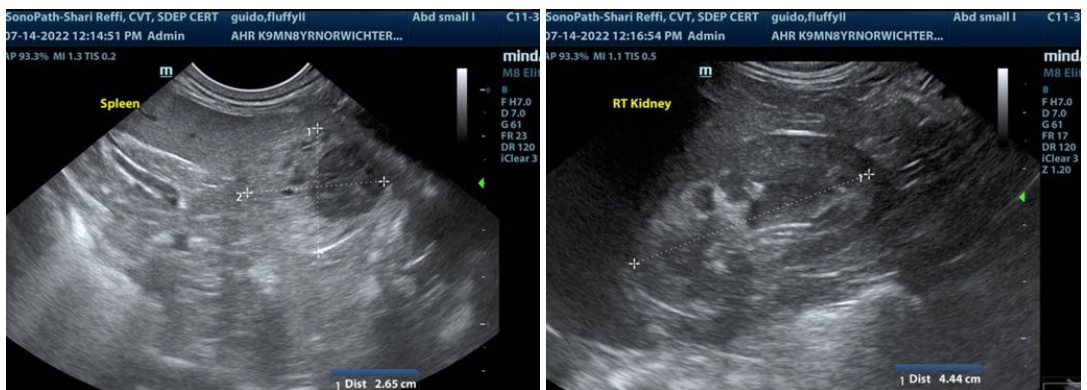
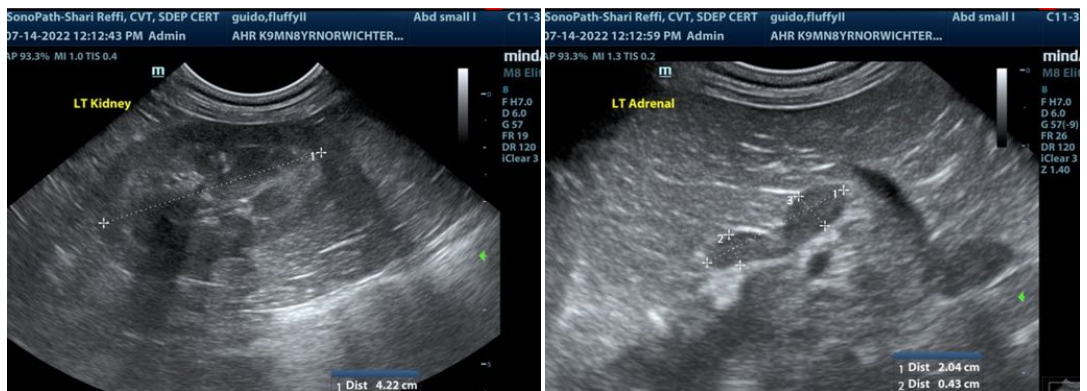
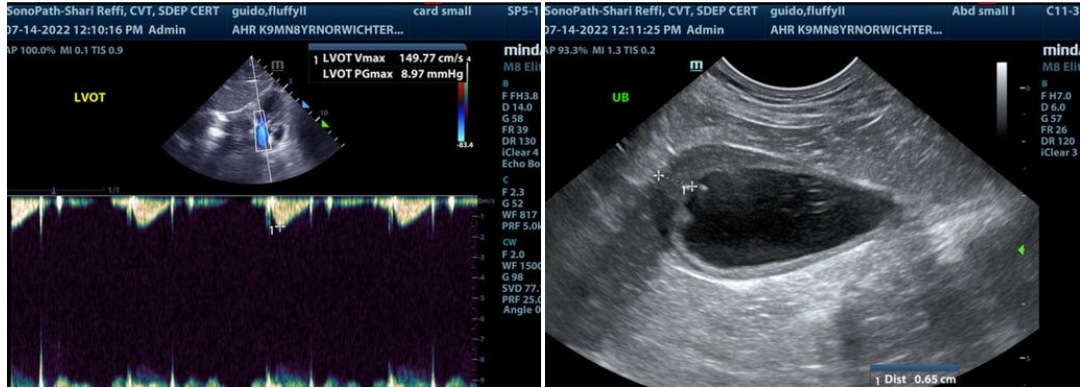
Dr. Hickenbottom

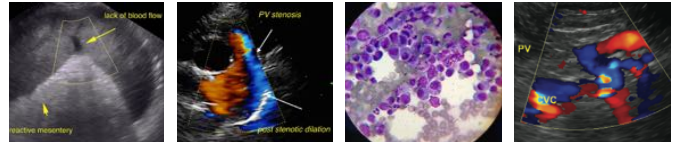
**INVOICE**

31676

**DATE**

6/30/22





**PATIENT**

Fluffy II Guido

**SPECIES**

Canine

**BREED**

Norwich Terrier Mix

**SEX**

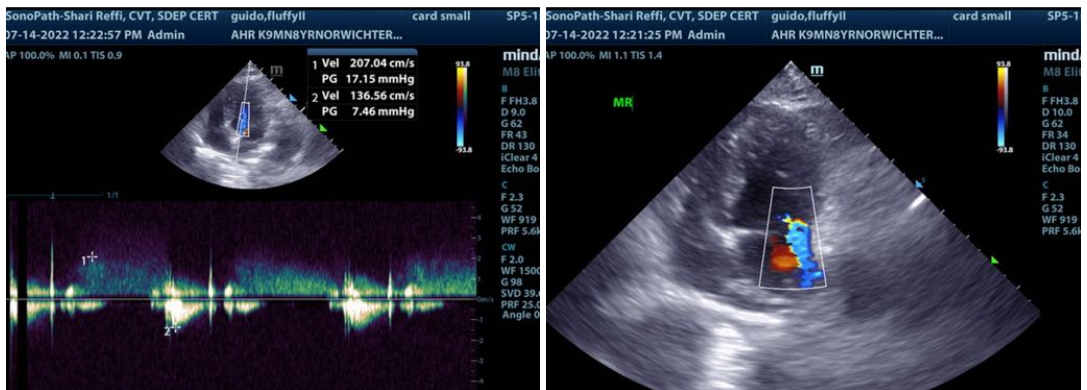
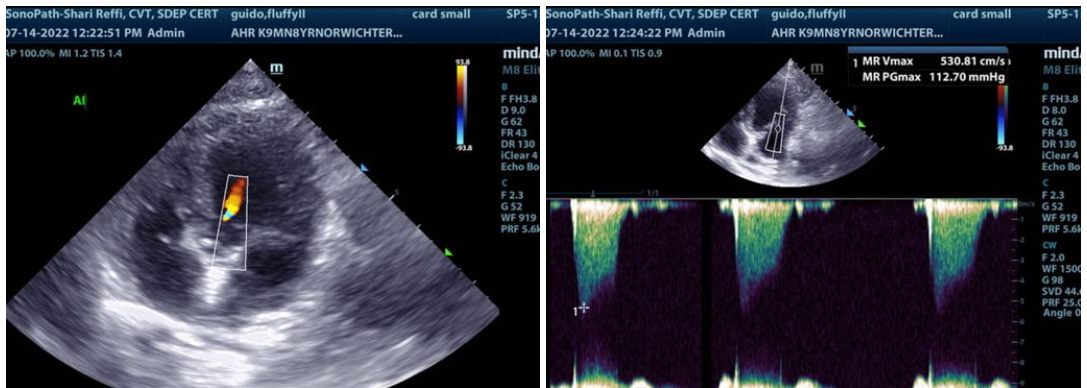
Neutered male

**AGE**

8 years

**WEIGHT**

27 lbs



**INTERPRETED BY**

Eric Lindquist, DMV  
DABVP, Cert. IVUSS

**IMAGING PERFORMED BY**

Shari Reffi, CVT

**HOSPITAL NAME**

Animal Hospital of  
Roxbury

**REFERRING VET**

Dr. Hickenbottom

**INVOICE**

31676

**DATE**

6/30/22

The information and recommendations provided are based on the images presented by the referring veterinarian/sonographer. No evaluation can be communicated regarding pathology that was not visible in the image/video clips provided.

Thank you for this referral. If the clinical or image interpretation does not parallel your findings or if I can be of any further assistance please contact me.

**Eric Lindquist, DMV, DABVP, Cert. IVUSS, CEO of SonoPath.com**  
Info@SonoPath.com

