

**PATIENT**

Spartacus Ravindra

**PRESENTING CLINICAL SIGNS**

Cytology

**SPECIES**

Feline

**ULTRASONOGRAPHIC EXAMINATION OF THE ABDOMEN**

**Urinary System**

**BREED**

Domestic Shorthair

The **urinary bladder**, trigone, and pelvic urethra presented normal thicknesses and normal tone. The ureters were not visible which is normal. A trace amount of sand was noted in bladder and measured approximately 0.4 cm. The sand was non-obstructive at the time of the sonogram. No evidence of inflammatory or neoplastic changes was noted. Ureteral papillae were normal.

**SEX**

Neutered male

The **kidneys** revealed largely normal size and structure, corticomedullary definition and ratio (cortex 1/3 of medulla) were essentially maintained with some age-related loss of curvilinear patterns regarding the capsule and C/M junction. The cortices presented largely uniform texture with some increased echogenicity expected for his age patient. Medullary structure differed distinctly from that of the cortex and no evidence of pelvic dilation was present. A slight cortical infarct was noted at the caudal pole of the right kidney with regional free fluid in the retroperitoneal space. The right kidney measured 4.3 cm. The left kidney measured 3.96 cm.

**AGE**

7 years

**WEIGHT**

11 lbs

**Adrenal Glands**

Both **adrenal glands** were visualized and recognized as having normal shape, size, position and echogenicity for this breed. The phrenic vasculature, glandular echogenicity and detail were unremarkable. Capsule, cortex, and medullary definition were normal for this age patient. The left adrenal gland measured 0.48 cm.

**INTERPRETED BY**

Eric Lindquist, DMV  
DABVP, Cert. IVUSS

**Spleen**

The **spleen** presented a smooth homogeneous parenchyma hyperechoic to liver and renal cortical parenchyma. The capsule was smooth without noticeable expansion or deviation from within the spleen or adjacent pathology. The splenic vasculature demonstrated normal volume without signs of congestion or thrombosis. No sonographic evidence of acute or chronic inflammatory, neoplastic, or infarctual changes was noted.

**IMAGING PERFORMED BY**

Jessica Miller, RDMS

**HOSPITAL NAME**

Summit Dog and Cat  
Hospital

**REFERRING VET**

Dr. Vogler

**Liver**

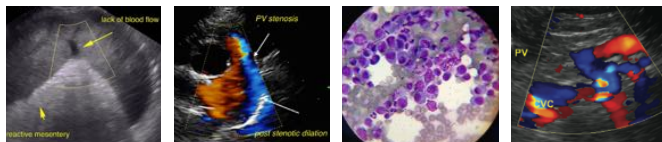
The **liver** images submitted revealed subjectively normal liver size, contour, and structure. Parenchymal echogenicity was naturally coarse and hypoechoic to the spleen. Vascular and biliary tracts were of normal volume with no evidence of congestion. The gallbladder presented acceptably thin walls with primarily anechoic content. The cystic and common bile ducts were normal. No pathological hepatic lymphadenopathy was evident. No overt structural evidence of inflammatory, infiltrative or regenerative pathology was evident.

**INVOICE**

31645

**DATE**

7/12/22



## PATIENT

Spartacus Ravindra

## SPECIES

Feline

## BREED

Domestic Shorthair

## SEX

Neutered male

## AGE

7 years

## WEIGHT

11 lbs

## INTERPRETED BY

Eric Lindquist, DMV  
DABVP, Cert. IVUSS

## IMAGING PERFORMED BY

Jessica Miller, RDMS

## HOSPITAL NAME

Summit Dog and Cat  
Hospital

## REFERRING VET

Dr. Vogler

## INVOICE

31645

## DATE

7/12/22

## Gastrointestinal

Examination of the **gastrointestinal tract** revealed a stomach and intestine free of stasis, of normal wall thickness, acceptable curvilinear mural detail, and peristaltic activity. Small and large intestine demonstrated normal luminal chyme and stool consistency respectively. No obstructive or overt infiltrative disease was noted. No associated abnormal lymphatic activity was noted.

## Pancreas

The base and limbs of the **pancreas** were observed to be largely isoechoic to surrounding omental fat. Pancreatic duct and capsular contour were acceptably normal and parenchyma respected normal curvilinear patterns. No overt evidence of active inflammatory or neoplastic disease was noted.

## ULTRASONOGRAPHIC FINDINGS

Trace bladder sand.

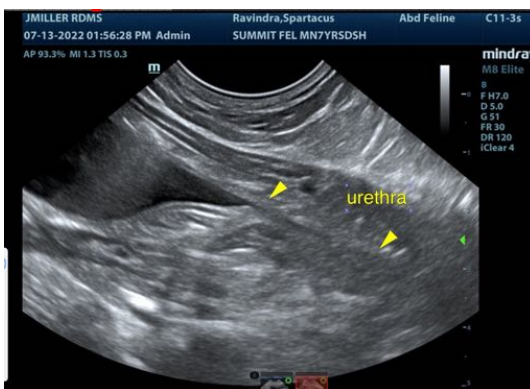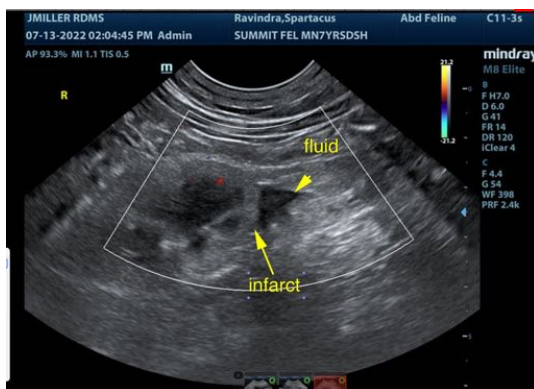
Right renal infarct, mild remodeling.

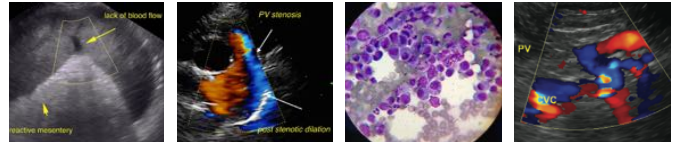
Retroperitoneal fluid.

Otherwise, unremarkable abdomen.

## INTERPRETATION OF THE FINDINGS & FURTHER RECOMMENDATIONS

Fresh infarct with secondary fluid accumulation is likely. Ultrasound-guided centesis was performed without complication. The cause of infarct is unclear. The patient may have recently passed sand or calculus causing an infarct. Supportive care and coverage for underlying infection/UTI and a recheck sonogram is recommended in 7-10 days if the patient is stable.





**PATIENT**

Spartacus Ravindra

**SPECIES**

Feline

**BREED**

Domestic Shorthair

**SEX**

Neutered male

**AGE**

7 years

**WEIGHT**

11 lbs

**INTERPRETED BY**

Eric Lindquist, DMV  
DABVP, Cert. IVUSS

**IMAGING PERFORMED BY**

Jessica Miller, RDMS

**HOSPITAL NAME**

Summit Dog and Cat  
Hospital

**REFERRING VET**

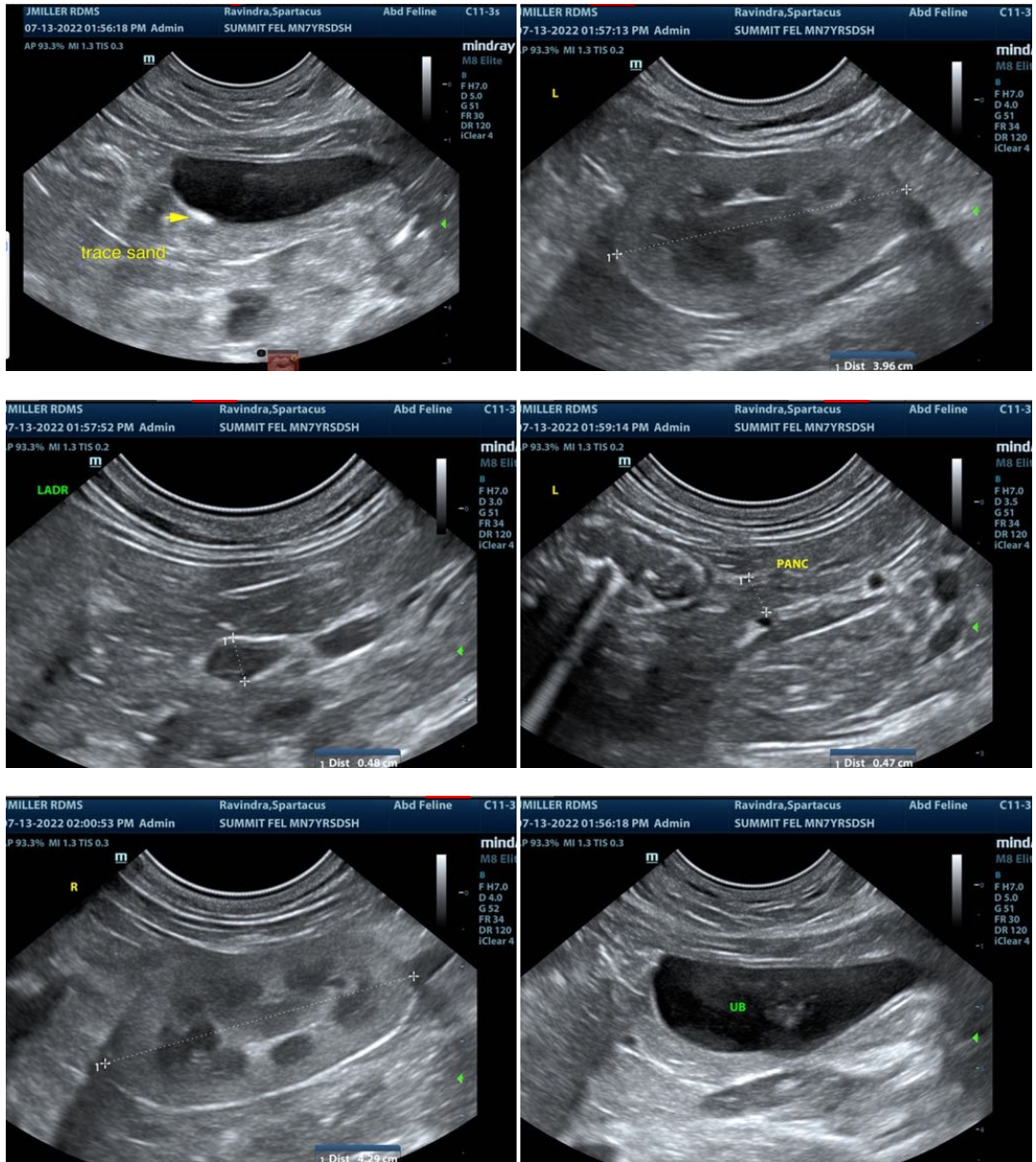
Dr. Vogler

**INVOICE**

31645

**DATE**

7/12/22



The information and recommendations provided are based on the images presented by the referring veterinarian/sonographer. No evaluation can be communicated regarding pathology that was not visible in the image/video clips provided.

Thank you for this referral. If the clinical or image interpretation does not parallel your findings or if I can be of any further assistance please contact me.

**Eric Lindquist**, DMV, DABVP, Cert. IVUSS, CEO of SonoPath.com  
info@SonoPath.com