

PATIENT

Loki Wiener

PRESENTING CLINICAL SIGNS

Patient presents for vomiting, no weight loss, and good appetite. Vomits after eating. No improvement with Pepcid trial, starting hydrolyzed diet.
Abnormal PE/Chem/CBC/UA Results: MCH 25.4, heartworm (neg).

SPECIES

Canine

ULTRASONOGRAPHIC EXAMINATION OF THE ABDOMEN

Urinary System

The **urinary bladder**, trigone, and pelvic urethra presented normal thicknesses and normal tone. The ureters were not visible which is normal. No uroliths or sediment were visualized and anechoic urine was present. No evidence of inflammatory or neoplastic changes was noted. Ureteral papillae were normal.

BREED

French Bulldog

SEX

Neutered male

The **kidneys** revealed normal size and structure, corticomedullary definition and ratio for this age. The cortices presented largely uniform texture with normal echogenic relationship to liver and spleen. Medullary structure differed distinctly from the cortex and no evidence of pelvic dilation was present. The capsules were acceptably uniform without significant irregularities. The right kidney measured 4.58 cm. The left kidney measured 4.87 cm.

AGE

1 year

WEIGHT

Adrenal Glands

Both **adrenal glands** were visualized and recognized as having normal shape, size, position and echogenicity for this breed. The phrenic vasculature, glandular echogenicity and detail were unremarkable. Capsule, cortex, and medullary definition were normal for this age patient. The right adrenal gland measured 2.29 x 0.42 cm at the caudal pole and 0.63 cm at the cranial pole. The left adrenal gland measured 1.94 x 0.36 cm at the caudal pole and 0.27 cm at the cranial pole.

INTERPRETED BY

Eric Lindquist, DMV,
DABVP, Cert. IVUSS,
CEO of SonoPath.com

IMAGING PERFORMED BY

Kelly Vazquez, CVT

Spleen

The **spleen** presented a smooth homogeneous parenchyma hyperechoic to liver and renal cortical parenchyma. The capsule was smooth without noticeable expansion or deviation from within the spleen or adjacent pathology. The splenic vasculature demonstrated normal volume without signs of congestion or thrombosis. No sonographic evidence of acute or chronic inflammatory, neoplastic, or infarctual changes was noted.

HOSPITAL NAME

The Ventrueing Vet

REFERRING VET

Dr. Herzog

Liver

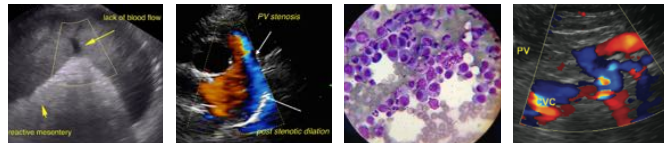
The **liver** images submitted revealed subjectively normal liver size, contour, and structure. Parenchymal echogenicity was naturally coarse and hypoechoic to the spleen. Vascular and biliary tracts were of normal volume with no evidence of congestion. The gallbladder presented acceptably thin walls with primarily anechoic content. The cystic and common bile ducts were normal. No pathological hepatic lymphadenopathy was evident. No overt structural evidence of inflammatory, infiltrative or regenerative pathology was evident.

INVOICE

31637

DATE

7/13/22



PATIENT

Gastrointestinal

Loki Wiener

The **stomach** was empty. Minor, hypertrophy was noted, which is typical for the breed, yet there was no evidence of obstructive disease.

SPECIES

Canine

Pancreas

The base and limbs of the **pancreas** were observed to be largely isoechoic to surrounding omental fat. Pancreatic duct and capsular contour were acceptably normal and parenchyma respected normal curvilinear patterns. No overt evidence of active inflammatory or neoplastic disease was noted.

BREED

French Bulldog

SEX

Neutered male

ULTRASONOGRAPHIC FINDINGS

Structurally unremarkable abdomen.

AGE

1 year

Minor pyloric hypertrophy.

INTERPRETATION OF THE FINDINGS & FURTHER RECOMMENDATIONS

Underlying food intolerance, occult parasitism, dietary indiscretion and Helicobacter are all potentials in this patient. Endoscopy is warranted if empirical measures are not effective. Canned b.i.d. feedings are likely recommended. Hydrolyzed diet and a clinical trial of the following is recommended.

WEIGHT

Helicobacter/Gastritis protocol

A clinical trial of **Zithromax (Dogs: 5-10 mg/kg p.o. q24h. May increase dosing interval to q48h after 3-5 days of treatment)**, **Metronidazole (10-20 mg/kg p.o. b.i.d.)**, **Pepcid (0.5-1 mg/kg s.i.d.)** and **Sucralfate (0.5-2 g/dog PO) or Omeprazole (1 mg/kg p.o. s.i.d.)** over the next 3 weeks along with a **novel-protein or hydrolyzed diet** with slurry feeding b.i.d./t.i.d. over the next 2-4 days and then increase to canned diet bid. Dry food should be avoided over the next 4 weeks. A recheck sonogram to assess GI improvement or progression would be ideal in 4 weeks.

INTERPRETED BY

Eric Lindquist, DMV,
DABVP, Cert. IVUSS,
CEO of SonoPath.com

IMAGING PERFORMED BY

Kelly Vazquez, CVT

HOSPITAL NAME

The Ventruing Vet

REFERRING VET

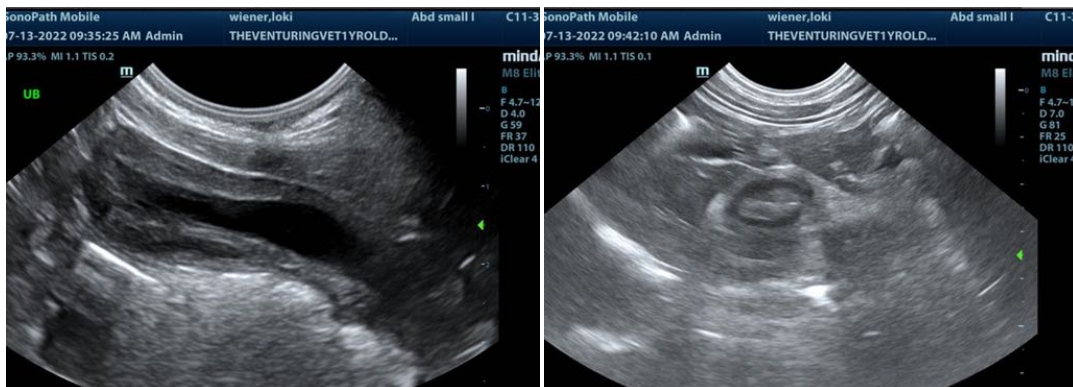
Dr. Herzog

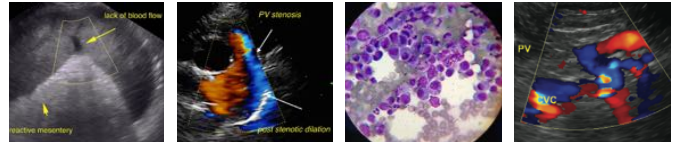
INVOICE

31637

DATE

7/13/22





PATIENT

Loki Wiener

SPECIES

Canine

BREED

French Bulldog

SEX

Neutered male

AGE

1 year

WEIGHT

INTERPRETED BY

Eric Lindquist, DMV,
DABVP, Cert. IVUSS,
CEO of SonoPath.com

IMAGING PERFORMED BY

Kelly Vazquez, CVT

HOSPITAL NAME

The Ventruing Vet

REFERRING VET

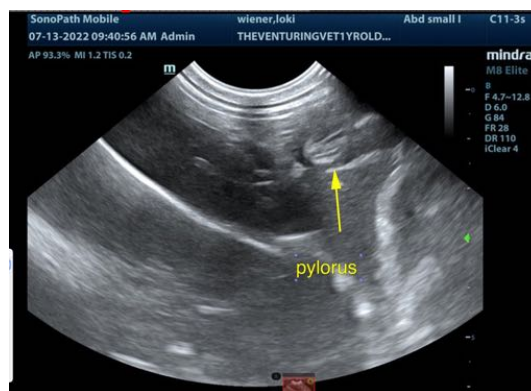
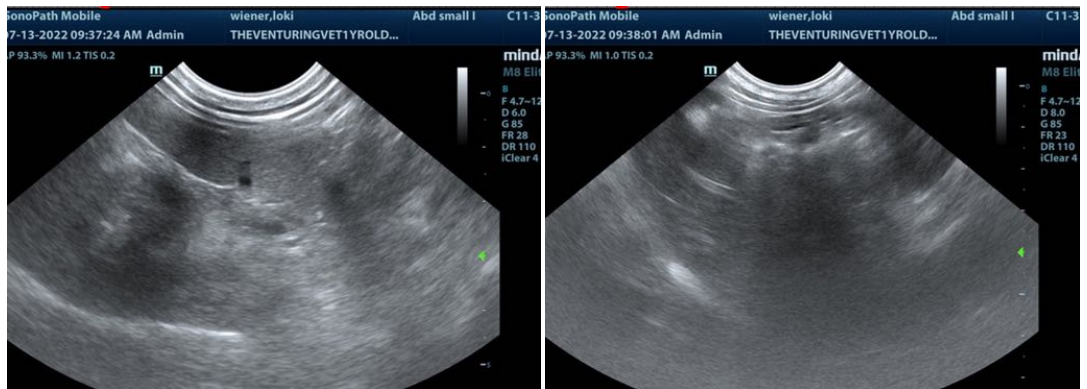
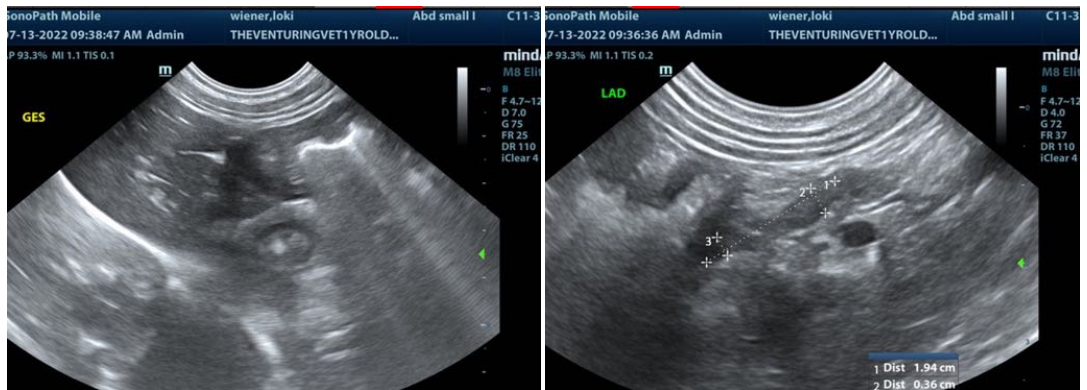
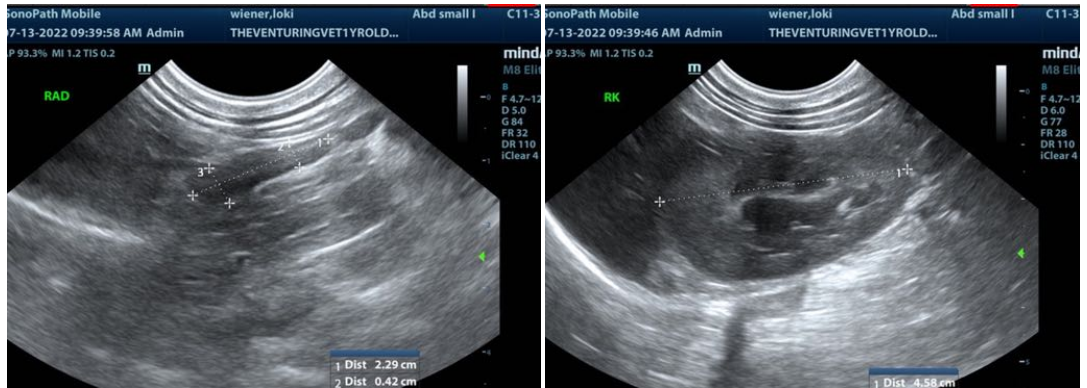
Dr. Herzog

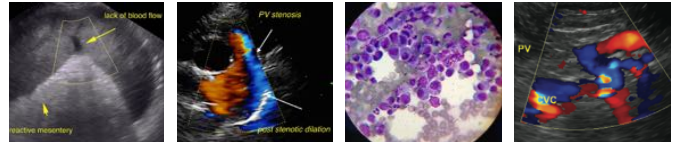
INVOICE

31637

DATE

7/13/22





PATIENT

Loki Wiener

The information and recommendations provided are based on the images presented by the referring veterinarian/sonographer. No evaluation can be communicated regarding pathology that was not visible in the image/video clips provided.

SPECIES

Canine

Thank you for this referral. If the clinical or image interpretation does not parallel your findings or if I can be of any further assistance please contact me.

Eric Lindquist, DMV, DABVP, Cert. IVUSS, CEO of SonoPath.com

Info@SonoPath.com

BREED

French Bulldog

SEX

Neutered male

AGE

1 year

WEIGHT

INTERPRETED BY

Eric Lindquist, DMV,
DABVP, Cert. IVUSS,
CEO of SonoPath.com

**IMAGING
PERFORMED BY**

Kelly Vazquez, CVT

HOSPITAL NAME

The Ventruing Vet

REFERRING VET

Dr. Herzog

INVOICE

31637

DATE

7/13/22