

## PATIENT PRESENTING CLINICAL SIGNS

Milo Leone Pro BNP 456, creatinine kinase 1001, elevated BP

## SPECIES BREED SEX AGE ULTRASONOGRAPHIC EXAMINATION OF THE HEART

Feline

BREED

Domestic Longhair

SEX

Neutered male

AGE

9 years

The echocardiogram in this patient demonstrated normal **left atrial** size based on 3 separate LA measurements. The cranial and caudal **mitral** valve leaflets presented normal linear structure and kinetics. The **left ventricle** presented minor sectorial concentric hypertrophy with remodeling and prominent papillary muscles. There was no evidence of volume overload noted. The **myocardium** presented normal echogenicity without subjective evidence of significant fibrotic or ischemic disease. **Contractility** of the ventricular walls was adequate and in normal range for this patient evidenced by the fractional shortening measurement and subjective evaluation of the different regions and angles of the myocardium. The **left ventricular outflow** tract demonstrated normal laminar flow and subjective structural integrity. The **right atrium** and auricle revealed normal size, structure and content. No evidence of masses was noted or chamber overload. Trivial **tricuspid** insufficiency was noted. The **right ventricle** was of normal size (1/3 diameter of LV), chordae structure, myocardial echogenicity and thickness. **Pulmonic** tract assessment revealed normal valve structure, laminar flow, and diameter (approx. 1:1 pa/ao ratio). No visible **pericardial** or free pleura fluid was noted or extra cardiac pathology in the visible planes. The cranial **mediastinum and pericardial regions** were free of masses in the visible window.

## INTERPRETED BY

Eric Lindquist, DMV  
DABVP, Cert. IVUSS

## IMAGING PERFORMED BY

Eric Lindquist, DMV  
DABVP, Cert. IVUSS

## HOSPITAL NAME

Butler VH

## REFERRING VET

Dr. Garro

## INVOICE

31593

## DATE

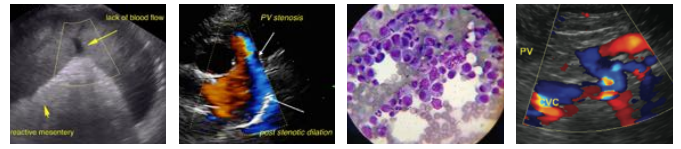
7/12/22

FELINE CARDIAC PARAMETERS	BODY WEIGHT (kg)	HR (BPM)	IVSd (cm)	LVIDd (cm)	LVWd (cm)	FS (%)	EF (%)
NORMAL PARAMETER	-----	150-240	0.3-0.6	1.0-2.1	0.25-0.6	35-67	80-100
PATIENT		215	0.54	1.62	0.64	55	88
FELINE CARDIAC PARAMETERS	LA/AO (Boon)	LA/AO HEART BASE (Sisson)	LA 2D 4-chamber long axis AS to FW (Sisson) (cm)	LVOT VEL. (m/s)	RVOT VEL. (m/s)	IVRT (m/)	
NORMAL PARAMETER	<1.5	0.88-1.79	0.7-1.7	<1.6	<1.3	40-60	
PATIENT	1.3	1.15	1.3	1.4	0.95	NM	
Adapted from June Boon, Veterinary Echocardiography, 1998 Sisson D et al. JVIM 1991; 5: 232, Jacobs et al. Am J Vet Res 1985; 46:1705							

## ULTRASONOGRAPHIC FINDINGS

Myocardial remodeling.

Minor sectorial hypertrophy, not clinically significant.



**PATIENT**

Milo Leone

**SPECIES**

Feline

**BREED**

Domestic Longhair

**SEX**

Neutered male

**AGE**

9 years

**INTERPRETED BY**

Eric Lindquist, DMV  
DABVP, Cert. IVUSS

**IMAGING PERFORMED BY**

Eric Lindquist, DMV  
DABVP, Cert. IVUSS

**HOSPITAL NAME**

Butler VH

**REFERRING VET**

Dr. Garro

**INVOICE**

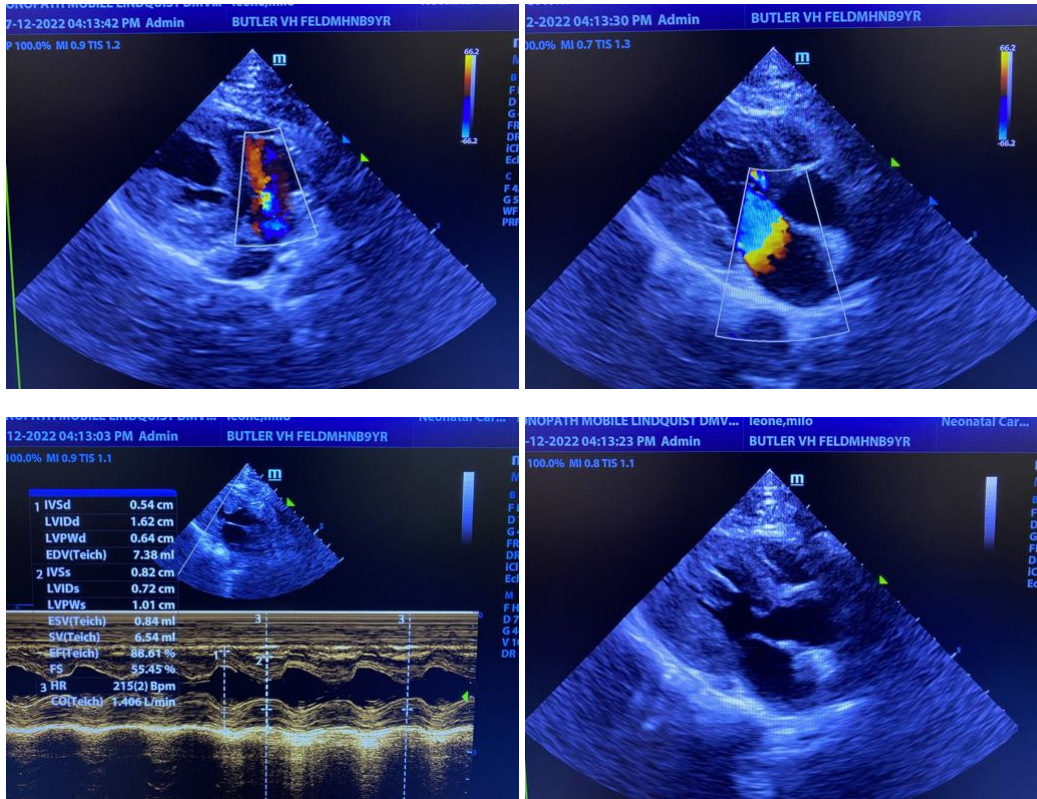
31593

**DATE**

7/12/22

**INTERPRETATION OF THE FINDINGS & FURTHER RECOMMENDATIONS**

Periodic monitoring of blood pressure measurements and thyroid are warranted. There is no overt contraindication to anesthetic procedure. Torbutrol pre med, Propofol induction with Isoflurane maintenance is suggested protocol. Recheck echocardiogram is recommended in 6-12 months.



The information and recommendations provided are based on the images presented by the referring veterinarian/sonographer. No evaluation can be communicated regarding pathology that was not visible in the image/video clips provided.

Thank you for this referral. If the clinical or image interpretation does not parallel your findings or if I can be of any further assistance please contact me.

**Eric Lindquist**, DMV, DABVP, Cert. IVUSS, CEO of SonoPath.com  
Info@SonoPath.com