

**PATIENT**

Harley Root

**PRESENTING CLINICAL SIGNS**

History: Elevated Alk. Phos., low USG, normal bile acids. No current meds.  
Abnormal PE/Chem/CBC/UA Results: Alk. Phos. 1585.

**SPECIES**

Canine

**ULTRASONOGRAPHIC EXAMINATION OF THE ABDOMEN**

**Urinary System**

**BREED**

Mini Bernadoodle

The **urinary bladder**, trigone, and pelvic urethra presented normal thicknesses and normal tone. The ureters were not visible which is normal. No uroliths or sediment were visualized and anechoic urine was present. No evidence of inflammatory or neoplastic changes was noted. Ureteral papillae were normal.

**SEX**

Intact female

The uterus was uniform measuring 0.5 cm.

**AGE**

5 months

The **kidneys** revealed normal size and structure, corticomedullary definition and ratio for this age. The cortices presented largely uniform texture with normal echogenic relationship to liver and spleen. Medullary structure differed distinctly from the cortex and no evidence of pelvic dilation was present. The capsules were acceptably uniform without significant irregularities. The right kidney measured 4.03 cm. The left kidney measured 5.0 cm.

**WEIGHT**

30 lbs

**Adrenal Glands**

Both **adrenal glands** were visualized and recognized as having normal shape, size, position and echogenicity for this breed. The phrenic vasculature, glandular echogenicity and detail were unremarkable. Capsule, cortex, and medullary definition were normal for this age patient. The right adrenal gland measured 2.33 x 0.65 cm at the cranial pole and 0.34 cm at the caudal pole. The left adrenal gland measured 2.33 x 0.46 cm at the caudal pole and 0.36 cm at the cranial pole.

**INTERPRETED BY**

Eric Lindquist, DMV,  
DABVP, Cert. IVUSS,  
CEO of SonoPath.com

**Spleen**

The **spleen** presented a smooth homogeneous parenchyma hyperechoic to liver and renal cortical parenchyma. The capsule was smooth without noticeable expansion or deviation from within the spleen or adjacent pathology. The splenic vasculature demonstrated normal volume without signs of congestion or thrombosis. No sonographic evidence of acute or chronic inflammatory, neoplastic, or infarctual changes was noted.

**IMAGING PERFORMED BY**

Kelly Vazquez, CVT

**HOSPITAL NAME**

Marsh Hospital for  
Animals

**Liver**

The **liver** images submitted revealed subjectively normal liver size, contour, and structure. Parenchymal echogenicity was naturally coarse and hypoechoic to the spleen. The portal vein to vena cava ratio was 1:1 with no evidence of extrahepatic shunting. The gallbladder presented acceptably thin walls with primarily anechoic content. The cystic and common bile ducts were normal. No pathological hepatic lymphadenopathy was evident. No overt structural evidence of inflammatory, infiltrative or regenerative pathology was evident.

**REFERRING VET**

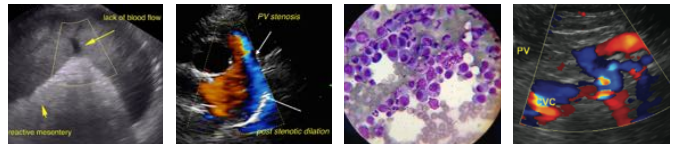
Dr. Milwicki

**INVOICE**

31596

**DATE**

7/12/22



**PATIENT**

Harley Root

**Gastrointestinal**

**SPECIES**

Canine

There was some residual chyme and gas was noted in the **stomach**, yet not pathological. This is consistent with end post prandial presentation. Transit of chyme into the small intestine was normal. Curvilinear patterns were maintained throughout the GI tract. No evidence of pathology. Small and large intestine demonstrated normal luminal chyme and stool consistency respectively. No obstructive or overt infiltrative disease was noted. The mesenteric lymph nodes were reactive and measured 1.05 x 0.7 cm.

**BREED**

Mini Bernadoodle

**Pancreas**

**SEX**

Intact female

The base and limbs of the **pancreas** were observed to be largely isoechoic to surrounding omental fat. Pancreatic duct and capsular contour were acceptably normal and parenchyma respected normal curvilinear patterns. No overt evidence of active inflammatory or neoplastic disease was noted.

**AGE**

5 months

**ULTRASONOGRAPHIC EXAMINATION OF THE HEART**

**WEIGHT**

30 lbs

The echocardiogram in this patient demonstrated normal **left atrial** size based on 3 separate methods of LA evaluation. The cranial and caudal **mitral** valve leaflets presented normal linear structure, extension in systole, and union in diastole with normal kinesis. The **left ventricle** presented thicknesses with linear contour and was not dilated nor restricted. The **myocardium** presented normal echogenicity without subjective evidence of significant fibrotic or ischemic disease. **Contractility** of the ventricular walls was adequate and in normal range for this patient evidenced by the fractional shortening measurement and subjective evaluation of the different regions of the myocardium. The **left ventricular outflow** tract demonstrated normal laminar flow and subjective structural integrity. The **right atrium** and auricle revealed normal size, structure and content. No evidence of masses was noted. **Tricuspid** valvular assessment demonstrated adequate linear morphology and kinesis. The **right ventricle** was of normal size (1/3 diameter of LV), chordae structure, myocardial echogenicity and thickness. **Pulmonary outflow** tract assessment revealed normal valve structure, laminar flow, and diameter (approx. 1:1 pa/ao ratio). No visible **pericardial** or free pleura fluid was noted. The cranial **mediastinum and pericardial and extra-cardiac regions** were free of masses in the visible window.

**INTERPRETED BY**

Eric Lindquist, DMV,  
DABVP, Cert. IVUSS,  
CEO of SonoPath.com

**IMAGING PERFORMED BY**

Kelly Vazquez, CVT

**HOSPITAL NAME**

Marsh Hospital for  
Animals

**REFERRING VET**

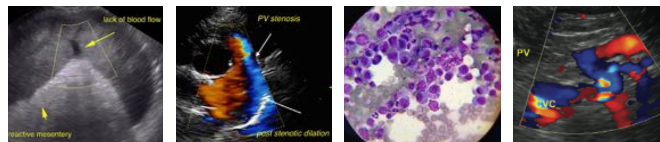
Dr. Milwicki

**INVOICE**

31596

**DATE**

7/12/22



**PATIENT**

Harley Root

**SPECIES**

Canine

**BREED**

Mini Bernadoodle

**SEX**

Intact female

**AGE**

5 months

**WEIGHT**

30 lbs

**INTERPRETED BY**

Eric Lindquist, DMV,  
DABVP, Cert. IVUSS,  
CEO of SonoPath.com

**IMAGING PERFORMED BY**

Kelly Vazquez, CVT

**HOSPITAL NAME**

Marsh Hospital for  
Animals

**REFERRING VET**

Dr. Milwicki

**INVOICE**

31596

**DATE**

7/12/22

CANINE CARDIAC PARAMETERS	MR VMAX (m/s)	TR VMAX (m/s)	LA/AO (Boon method)	LA/AO (Heart Base; Swe)	FS (%)	EF (%)	EPSS (cm)
NORMAL PARAMETER	4.5-5.5	<2.7	1.3	<1.6	28-40	40-100	<0.6
PATIENT	-	-	1.0	1.1	38	71	NM
CANINE CARDIAC PARAMETERS	HR (BPM)	AV VMAX (m/s)	PV MAX (m/s)	BODY WEIGHT (kg)	LA 2D short axis Base view (cm)	LVIDd Avg; 2D and m- mode short axis (cm)	LVIDs Avg; 2D and m- mode short axis (cm)
NORMAL PARAMETER	50-100	0.7-1.7	0.7-1.6	BELOW	BELOW	BELOW	BELOW
PATIENT	92	-	1.26	30 lbs	2.16	2.47	

**ULTRASONOGRAPHIC FINDINGS**

Normal echocardiogram.

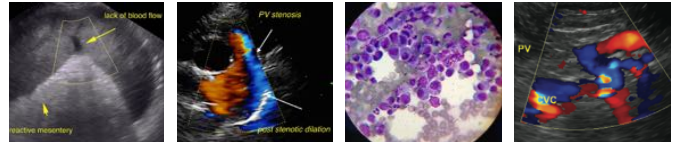
Normal abdomen.

**INTERPRETATION OF THE FINDINGS & FURTHER RECOMMENDATIONS**

The cause of ALKP is not evident from a visceral standpoint. This may be a spurious growth phase elevation. Isoenzymes of ALKP would be necessary to assess for hepatic, bone or GI orientation if available.

Internal medicine consult can be utilized through SonoPath.com. You can select the internal medicine drop down at <http://spa.sonopath.com/>.

One of the world's top internists & SonoPath associate Dr. Remo Lobetti BVSc, MMedVet, PhD, DECVIM can evaluate your case through SonoPath. <https://sonopath.com/resources/sonopath-services/internal-medicine-teleconsultation-services>



**PATIENT**

Harley Root

**SPECIES**

Canine

**BREED**

Mini Bernadoodle

**SEX**

Intact female

**AGE**

5 months

**WEIGHT**

30 lbs

**INTERPRETED BY**

Eric Lindquist, DMV,  
DABVP, Cert. IVUSS,  
CEO of SonoPath.com

**IMAGING PERFORMED BY**

Kelly Vazquez, CVT

**HOSPITAL NAME**

Marsh Hospital for  
Animals

**REFERRING VET**

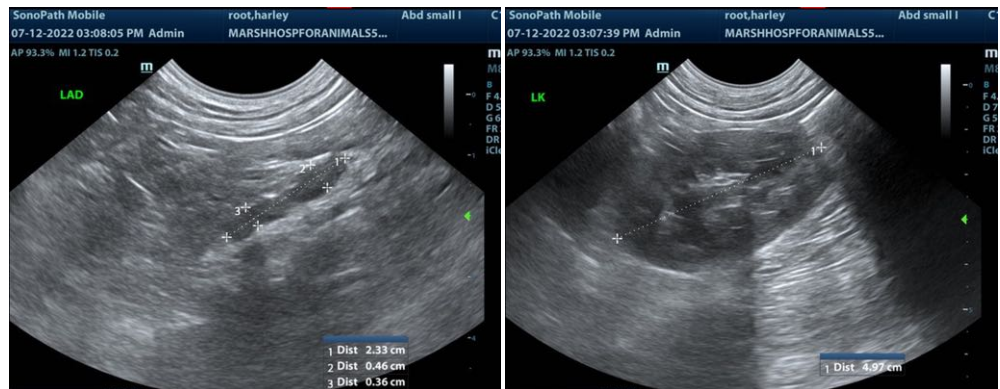
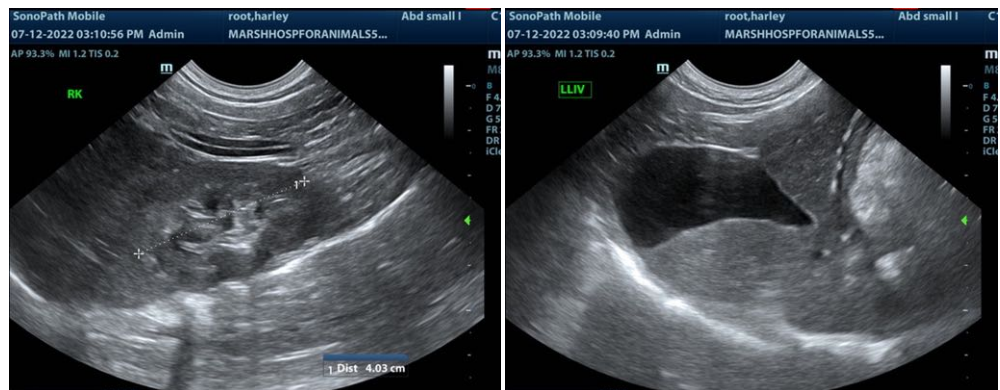
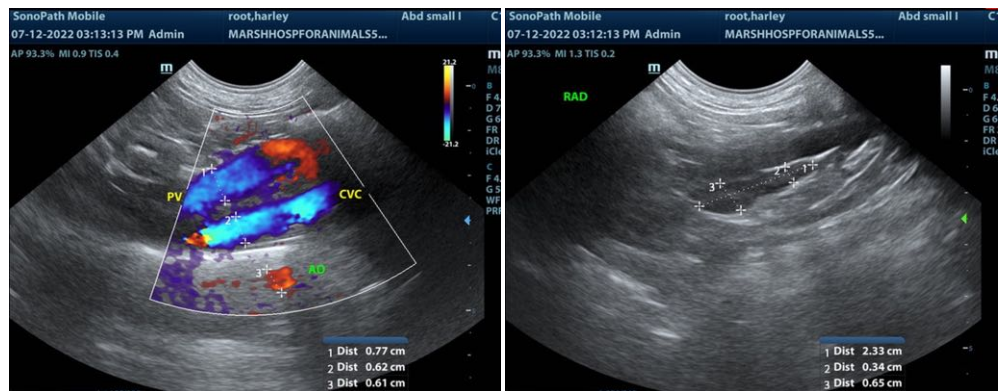
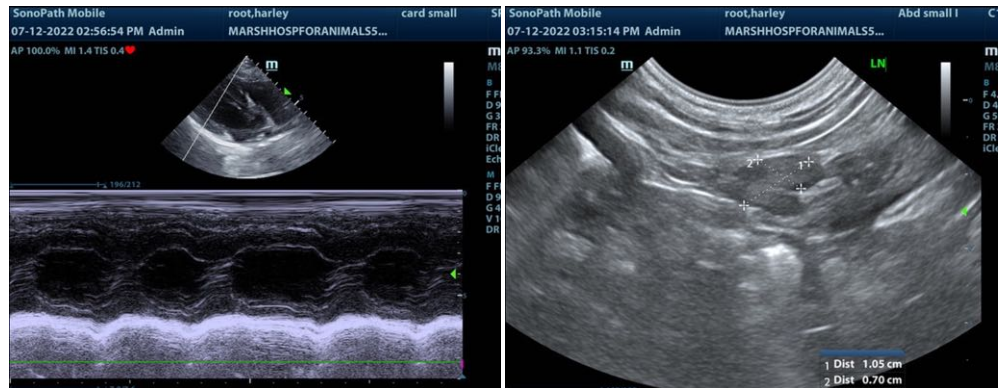
Dr. Milwicki

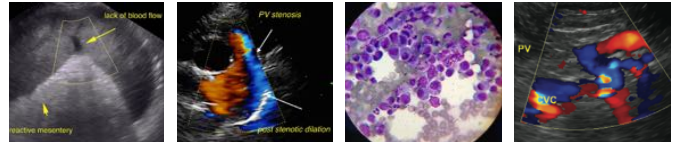
**INVOICE**

31596

**DATE**

7/12/22





**PATIENT**

Harley Root

**SPECIES**

Canine

**BREED**

Mini Bernadoodle

**SEX**

Intact female

**AGE**

5 months

**WEIGHT**

30 lbs

**INTERPRETED BY**

Eric Lindquist, DMV,  
DABVP, Cert. IVUSS,  
CEO of SonoPath.com

**IMAGING PERFORMED BY**

Kelly Vazquez, CVT

**HOSPITAL NAME**

Marsh Hospital for  
Animals

**REFERRING VET**

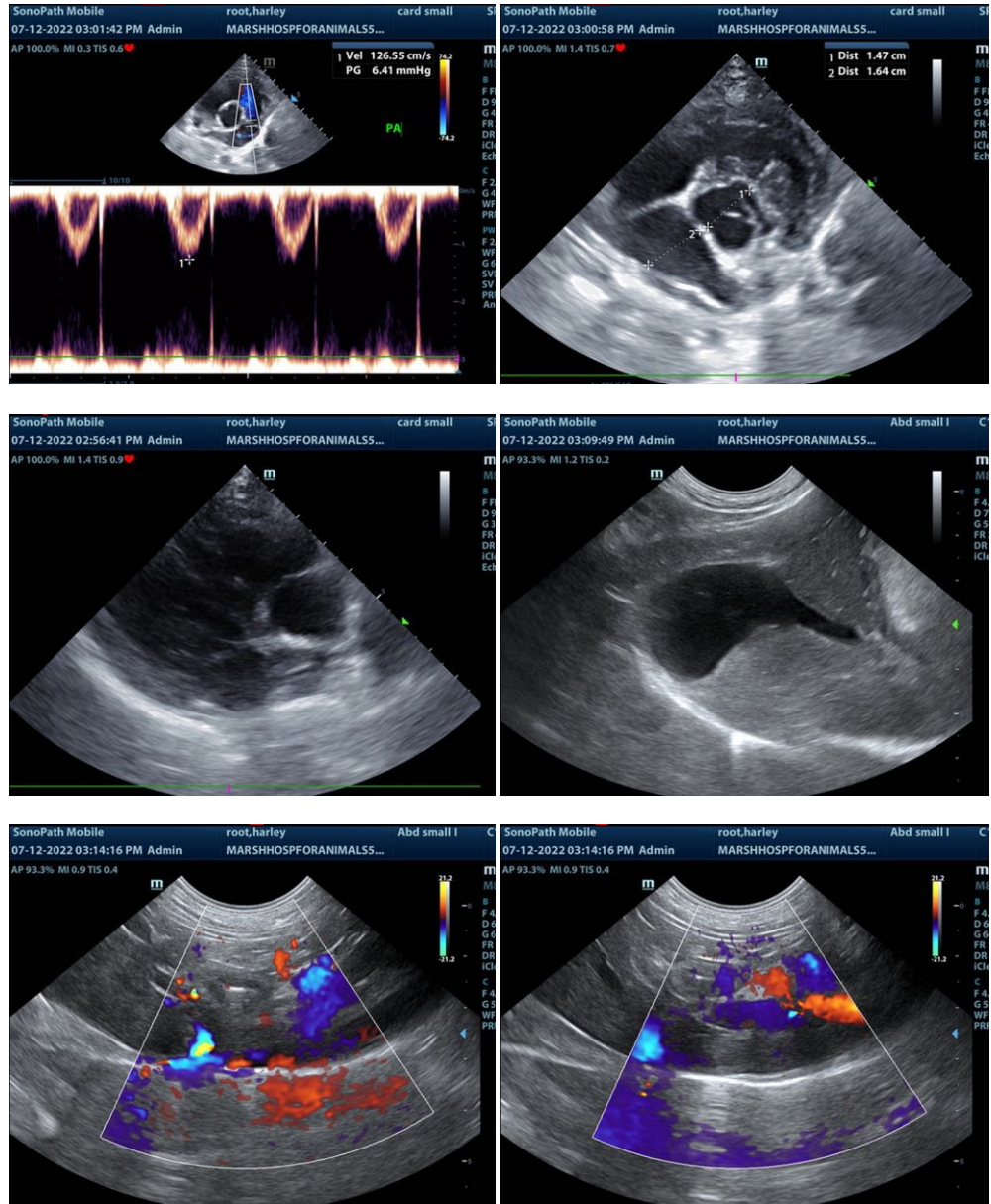
Dr. Milwicki

**INVOICE**

31596

**DATE**

7/12/22



The information and recommendations provided are based on the images presented by the referring veterinarian/sonographer. No evaluation can be communicated regarding pathology that was not visible in the image/video clips provided.

Thank you for this referral. If the clinical or image interpretation does not parallel your findings or if I can be of any further assistance please contact me.

Eric Lindquist, DMV, DABVP, Cert. IVUSS, CEO of SonoPath.com

Info@SonoPath.com