



**PATIENT**

Sunshite Sanchez

**PRESENTING CLINICAL SIGNS**

History: Patient presents for PU/PD and heart murmur. Current meds: Clavamox and Denamarin.

**SPECIES**

Canine

**ULTRASONOGRAPHIC EXAMINATION OF THE ABDOMEN**

**Urinary System**

**BREED**

Chihuahua

The **urinary bladder**, trigone, and pelvic urethra presented normal thicknesses and normal tone. The ureters were not visible which is normal. No uroliths or sediment were visualized and anechoic urine was present. No evidence of inflammatory or neoplastic changes was noted. Ureteral papillae were normal.

**SEX**

Spayed Female

The **kidneys** revealed largely normal size and structure, corticomedullary definition and ratio (cortex 1/3 of medulla) were essentially maintained with some age-related loss of curvilinear patterns regarding the capsule and C/M junction. The cortices presented largely uniform texture with some increased echogenicity expected for this age patient. Medullary structure differed distinctly from that of the cortex. The right kidney measured 3.59 cm with slight pyelectasia measuring 1.07 x 0.15 cm. The left kidney measured 3.26 cm.

**AGE**

10 years

**WEIGHT**

6.9 lbs

**Adrenal Glands**

Both **adrenal glands** appear mildly swollen. The right adrenal gland measured 1.54 x 0.48 cm at the caudal pole and 0.62 cm at the cranial pole. The left adrenal gland measured 1.44 x 0.67 cm at the caudal pole and 0.59 cm at the cranial pole.

**INTERPRETED BY**

Eric Lindquist, DMV,  
DABVP, Cert. IVUSS,  
CEO of SonoPath.com

**Spleen**

The **spleen** presented a smooth homogeneous parenchyma hyperechoic to liver and renal cortical parenchyma. The capsule was smooth without noticeable expansion or deviation from within the spleen or adjacent pathology. The splenic vasculature demonstrated normal volume without signs of congestion or thrombosis. No sonographic evidence of acute or chronic inflammatory, neoplastic, or infarctual changes was noted.

**IMAGING PERFORMED BY**

Kelly Vazquez, CVT

**HOSPITAL NAME**

North Jersey AH

**Liver**

The **liver** was uniformly swollen with minor, excessive gallbladder debris and over distension with dependent and suspended bile without evidence of overt mucocele formation. However, excessive sludge was present. The liver presented coarse architecture with mildly increased portal markings and subtle, mixed echogenic changes. This is consistent with vacuolar hepatopathy and some level of remodeling and history of inflammatory component. There was no overt suspicion of neoplasia.

**REFERRING VET**

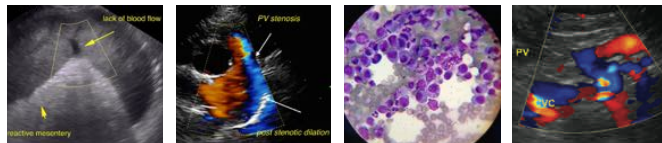
Dr. Riedel

**INVOICE**

31419

**DATE**

7/1/22



**PATIENT**

**Gastrointestinal**

Sunshite Sanchez

The **stomach** revealed a moderate amount of echogenic stasis. A fundic polyp was noted in this patient and measured 1.5 cm. Echogenic remodeling was noted throughout the stomach. The small intestines and colon were unremarkable.

**SPECIES**

Canine

**Pancreas**

**BREED**

Chihuahua

The base and limbs of the **pancreas** were observed to be largely isoechoic to surrounding omental fat. Some parenchymal remodeling, however, with mild deviation from curvilinear normalcy was observed. Pancreatic duct and capsular irregularities were present consistent with age related changes. If pain upon imaging (+ Murphy sign) was present or if the patient is focally painful in subxiphoid palpation then low-grade smoldering chronic pancreatitis should be suspected.

**SEX**

Spayed Female

**ULTRASONOGRAPHIC EXAMINATION OF THE HEART**

**AGE**

10 years

The echocardiogram in this patient demonstrated normal **left atrial** size based on 3 different LA measurement methods. Chamber volumes and echogenicity were normal. The cranial and caudal **mitral** valve leaflets presented vegetative thickening consistent with endocardiosis. Doppler indicated measurable insufficiency. The **left ventricle** presented thicknesses with linear contour and was not dilated nor restricted. The **myocardium** presented normal echogenicity without subjective evidence of significant fibrotic or ischemic disease. **Contractility** of the ventricular walls was adequate and in normal range for this patient evidenced by the fractional shortening measurement and subjective evaluation of the different regions of the myocardium. The **left ventricular outflow** tract demonstrated normal laminar flow and subjective structural integrity. The **right atrium** and auricle revealed normal size, structure and content. No evidence of masses was noted or chamber overload. **Tricuspid** valvular assessment demonstrated adequate linear morphology. The **right ventricle** was of normal size (1/3 diameter of LV), chordae structure, myocardial echogenicity and thickness. **Pulmonic** tract assessment revealed normal valve structure, laminar flow, and diameter (approx. 1:1 pa/ao ratio). No visible **pericardial** or free pleura fluid was noted. No echographically detectable evidence of infiltrative disease was visible. The cranial **mediastinum and pericardial regions** were free of masses in the visible window.

**WEIGHT**

6.9 lbs

**INTERPRETED BY**

Eric Lindquist, DMV,  
DABVP, Cert. IVUSS,  
CEO of SonoPath.com

**IMAGING PERFORMED BY**

Kelly Vazquez, CVT

**HOSPITAL NAME**

North Jersey AH

**REFERRING VET**

Dr. Riedel

**INVOICE**

31419

**DATE**

7/1/22


**PATIENT**

Sunshite Sanchez

**SPECIES**

Canine

**BREED**

Chihuahua

**SEX**

Spayed Female

**AGE**

10 years

**WEIGHT**

6.9 lbs

**INTERPRETED BY**

 Eric Lindquist, DMV,  
 DABVP, Cert. IVUSS,  
 CEO of SonoPath.com

**IMAGING PERFORMED BY**

Kelly Vazquez, CVT

**HOSPITAL NAME**

North Jersey AH

**REFERRING VET**

Dr. Riedel

**INVOICE**

31419

**DATE**

7/1/22

CANINE CARDIAC PARAMETERS	MR VMAX (m/s)	TR VMAX (m/s)	LA/AO (Boon method)	LA/AO (Heart Base; Swe)	FS (%)	EF (%)	EPSS (cm)
NORMAL PARAMETER	4.5-5.5	<2.7	1.3	<1.3	28-40	40-100	<0.6
PATIENT	5.5		1.1	1.2	35	69	NM
CANINE CARDIAC PARAMETERS	HR (BPM)	AV VMAX (m/s)	PV MAX (m/s)	BODY WEIGHT	LA (2D short axis Base view) (cm)	LVIDd (Avg; 2D and m-mode short axis) (cm)	LVIDs (Avg; 2D and m-mode short axis) (cm)
NORMAL PARAMETER	50-100	0.7-1.7	0.7-1.6				
PATIENT	116	1.2	0.73	6.9 lbs	1.3	1.27	

**ULTRASONOGRAPHIC FINDINGS**

Stage B1 valvular disease.

Gastritis pattern with polypoid change.

Subjectively swollen adrenal glands, yet measure normal.

Otherwise, geriatric abdomen.

**INTERPRETATION OF THE FINDINGS & FURTHER RECOMMENDATIONS**

B1: The heart is stable without clinical disease. No overt contraindication for anesthesia of brief to moderate duration. I suggest Torbutrol premed, Propofol induction, Isoflurane maintenance or similar protocol if anesthesia is desired. Blood pressure recommended if not already performed and target white coat negative systolic pressure of < 160 mmHg. If higher than this ACE-inhibitor is suggested to reach this level. Recheck echocardiogram is recommended in 6 months, earlier if murmur grade increases or clinical signs initiate.

Emerging PDH is a potential if the patient appears Cushingoid and the urine specific gravity is less than 1.020 repeatedly then work-up for PDH is indicated. The kidneys appear to have moderate degenerative changes.



**PATIENT**

Sunshite Sanchez

**SPECIES**

Canine

**BREED**

Chihuahua

**SEX**

Spayed Female

**AGE**

10 years

**WEIGHT**

6.9 lbs

**INTERPRETED BY**

Eric Lindquist, DMV,  
DABVP, Cert. IVUSS,  
CEO of SonoPath.com

**IMAGING PERFORMED BY**

Kelly Vazquez, CVT

**HOSPITAL NAME**

North Jersey AH

**REFERRING VET**

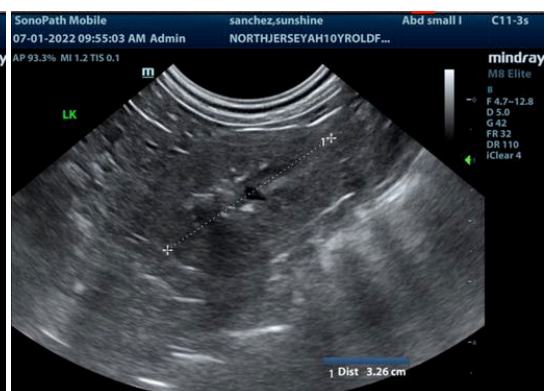
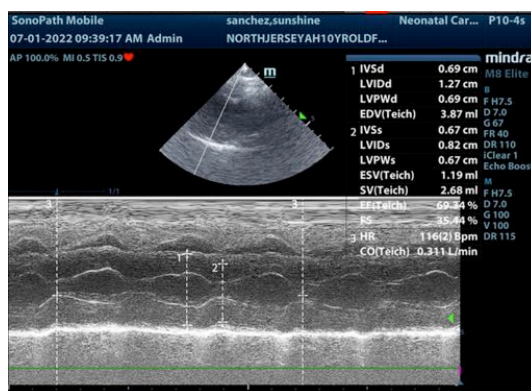
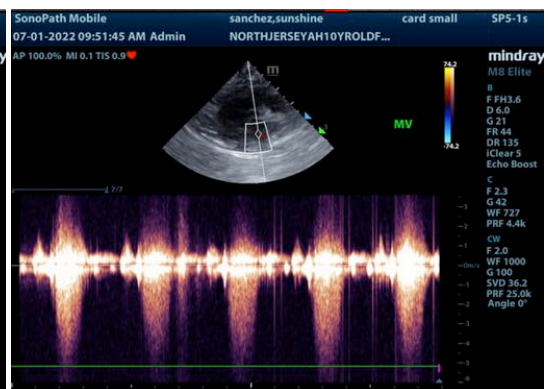
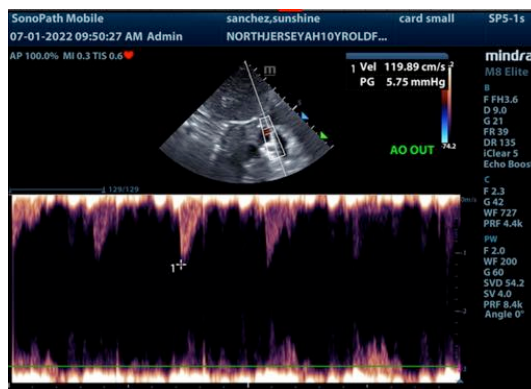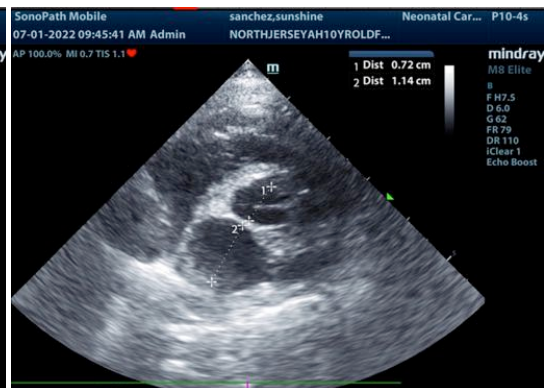
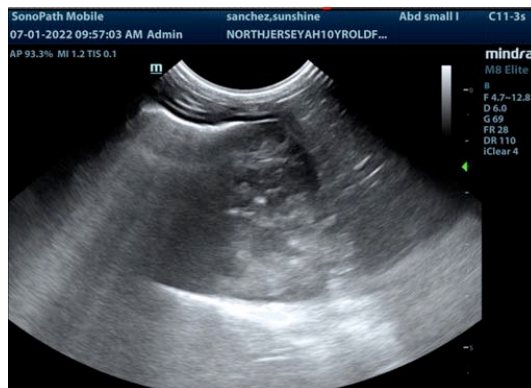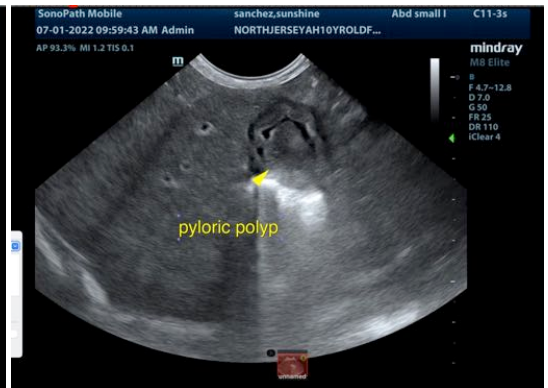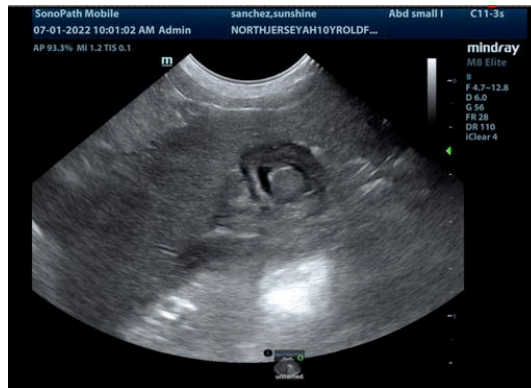Dr. Riedel

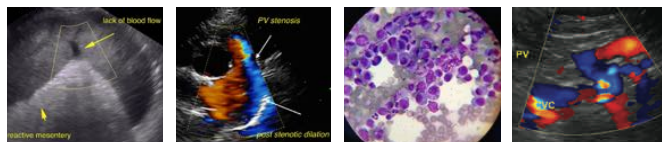
**INVOICE**

31419

**DATE**

7/1/22





**PATIENT**

Sunshite Sanchez

**SPECIES**

Canine

**BREED**

Chihuahua

**SEX**

Spayed Female

**AGE**

10 years

**WEIGHT**

6.9 lbs

**INTERPRETED BY**

Eric Lindquist, DMV,  
DABVP, Cert. IVUSS,  
CEO of SonoPath.com

**IMAGING PERFORMED BY**

Kelly Vazquez, CVT

**HOSPITAL NAME**

North Jersey AH

**REFERRING VET**

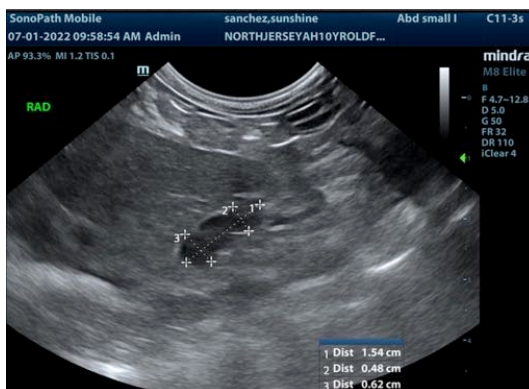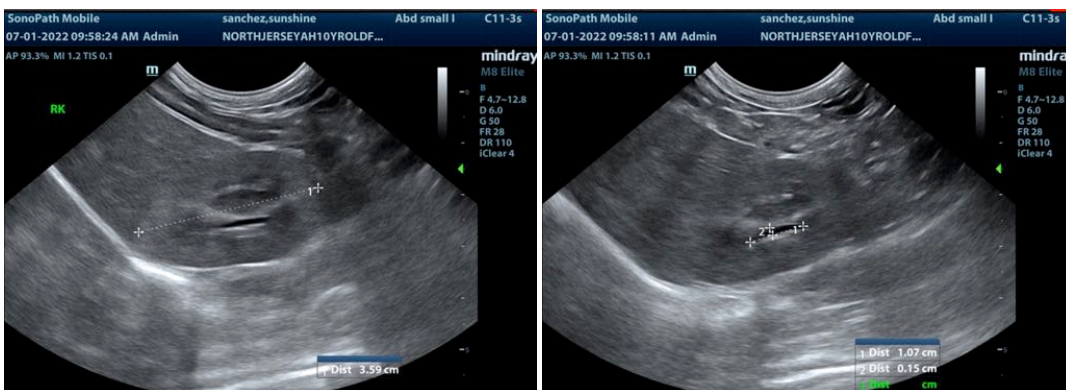
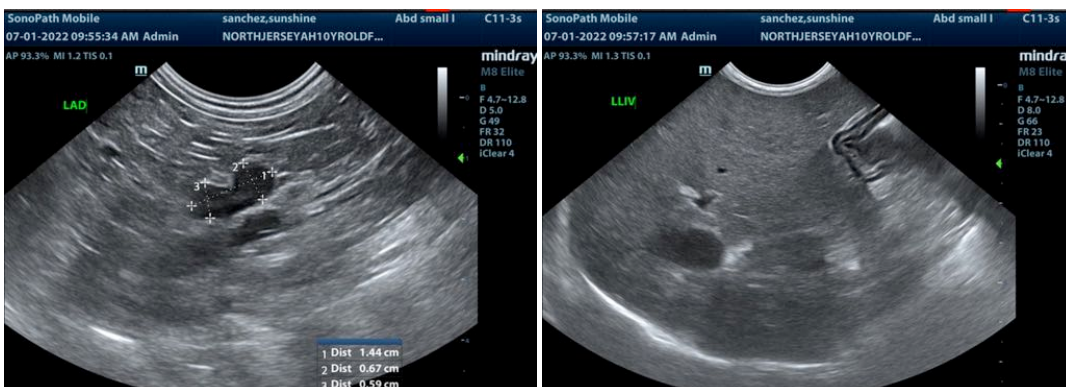
Dr. Riedel

**INVOICE**

31419

**DATE**

7/1/22



The information and recommendations provided are based on the images presented by the referring veterinarian/sonographer. No evaluation can be communicated regarding pathology that was not visible in the image/video clips provided.

Thank you for this referral. If the clinical or image interpretation does not parallel your findings or if I can be of any further assistance please contact me.

Eric Lindquist, DMV, DABVP, Cert. IVUSS, CEO of SonoPath.com

Info@SonoPath.com