



PATIENT PRESENTING CLINICAL SIGNS

Harry Ferrito History: heart murmur 2/6; asymptomatic

SPECIES BREED SEX AGE WEIGHT INTERPRETED BY

Feline

Domestic Shorthair

Neutered male

12 years

10.5 lbs

Eric Lindquist, DMV
DABVP, Cert. IVUSS

Diane McFadden, RVT

Newton VH

Dr. Wyman Greenwald

ULTRASONOGRAPHIC EXAMINATION OF THE ABDOMEN

The echocardiogram in this patient demonstrated normal **left atrial** size based on 3 separate LA measurements. The cranial and caudal **mitral** valve leaflets presented normal linear structure and kinetics. The **left ventricle** presented normal thicknesses with linear contour and was not dilated nor restricted. The **myocardium** presented normal echogenicity without subjective evidence of significant fibrotic or ischemic disease. **Contractility** of the ventricular walls was adequate and in normal range for this patient evidenced by the fractional shortening measurement and subjective evaluation of the different regions and angles of the myocardium. The **left ventricular outflow** tract demonstrated normal laminar flow and subjective structural integrity. The **right atrium** and auricle revealed normal size, structure and content. No evidence of masses was noted or chamber overload. **Tricuspid** valvular assessment demonstrated adequate linear morphology and kinetics. The **right ventricle** was of normal size (1/3 diameter of LV), chordae structure, myocardial echogenicity and thickness. **Pulmonic** tract assessment revealed normal valve structure, laminar flow, and diameter (approx. 1:1 pa/ao ratio). No visible **pericardial** or free pleura fluid was noted or extra cardiac pathology in the visible planes. The cranial **mediastinum and pericardial regions** were free of masses in the visible window.

FELINE CARDIAC PARAMETERS	BODY WEIGHT	HR (BPM)	IVSd (cm)	LVIDd (cm)	LVWd (cm)	FS (%)	EF (%)
NORMAL PARAMETER	-----	150-240	0.3-0.6	1.0-2.1	0.25-0.6	35-67	80-100
PATIENT	10.5 lbs	229	0.34	1.56	0.41	65	94
FELINE CARDIAC PARAMETERS	LA/AO (Boon)	LA/AO HEART BASE (Sisson)	LA 2D 4-chamber long axis AS to FW (Sisson) (cm)	LVOT VEL. (m/s)	RVOT VEL. (m/s)	IVRT (m/)	
NORMAL PARAMETER	<1.5	0.88-1.79	0.7-1.7	<1.6	<1.3	40-60	
PATIENT	1.13	1.03		1.0	0.9	NM	

Adapted from June Boon, Veterinary Echocardiography, 1998
Sisson D et al. JVIM 1991; 5: 232, Jacobs et al. Am J Vet Res 1985; 46:1705

INVOICE

45017

DATE

6/28/23

ULTRASONOGRAPHIC FINDINGS

Normal echocardiogram, no evidence of pathology.



PATIENT

Harry Ferrito

SPECIES

Feline

BREED

Domestic Shorthair

SEX

Neutered male

AGE

12 years

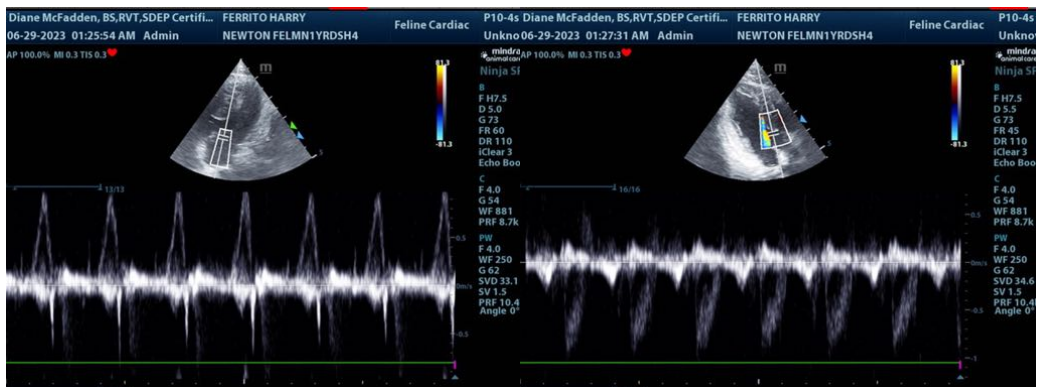
WEIGHT

10.5 lbs

INTERPRETATION OF THE FINDINGS & FURTHER RECOMMENDATIONS

This is most likely a flow murmur.

Benign flow murmurs are common in cats. This may be owing to volume shifts, tachycardia, benign (DRVOTO) right ventricular outflow changes, trivial turbulence in any of the valvular apparatuses, or possibly excessive stethoscope pressure against the chest according to a recent study These are physiologically benign and unrelated to specific pathology.



INTERPRETED BY

Eric Lindquist, DMV
DABVP, Cert. IVUS

IMAGING PERFORMED BY

Diane McFadden, RVT

HOSPITAL NAME

Newton VH

REFERRING VET

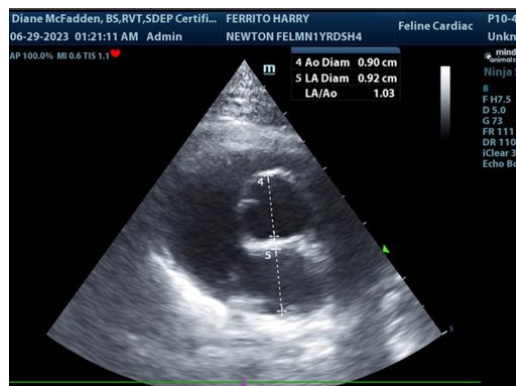
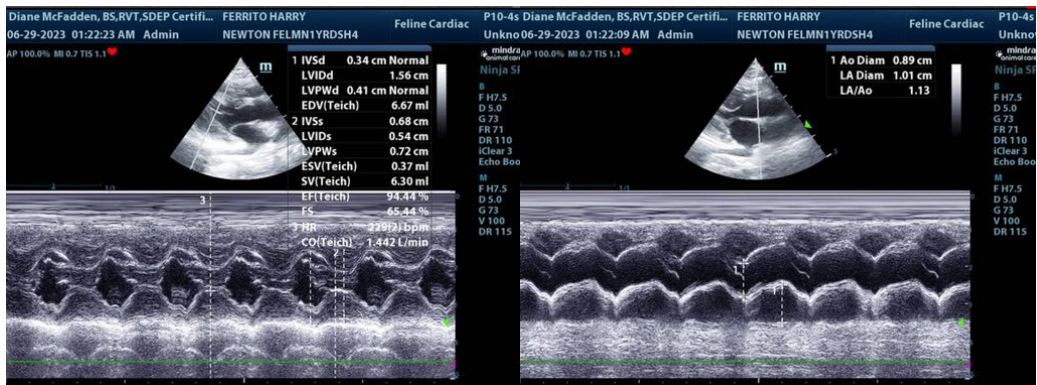
Dr. Wyman Greenwald

INVOICE

45017

DATE

6/28/23





PATIENT

Harry Ferrito

The information and recommendations provided are based on the images presented by the referring veterinarian/sonographer. No evaluation can be communicated regarding pathology that was not visible in the image/video clips provided.

SPECIES

Feline

Thank you for this referral. If the clinical or image interpretation does not parallel your findings or if I can be of any further assistance please contact me.

BREED

Domestic Shorthair

Eric Lindquist, DMV, DABVP, Cert. IVUSS, CEO of SonoPath.com
Info@SonoPath.com

SEX

Neutered male

AGE

12 years

WEIGHT

10.5 lbs

INTERPRETED BY

Eric Lindquist, DMV
DABVP, Cert. IVUSS

**IMAGING
PERFORMED BY**

Diane McFadden, RVT

HOSPITAL NAME

Newton VH

REFERRING VET

Dr. Wyman Greenwald

INVOICE

45017

DATE

6/28/23