



PATIENT PRESENTING CLINICAL SIGNS

Kiko Palmer Kehma

History: cardiac screen prior to doxorubicin administration- for nasal lymphoma. Meds include vinc, prednisone, cyclophosphamide

SPECIES

Feline

BREED

Siamese Mix

SEX

Neutered male

AGE

12 years

WEIGHT

15.1 lbs

INTERPRETED BY

Eric Lindquist, DMV
DABVP, Cert. IVUSS

IMAGING PERFORMED BY

Diane McFadden, RVT

HOSPITAL NAME

Rockaway AH

REFERRING VET

Dr. Gannon

ULTRASONOGRAPHIC EXAMINATION OF THE ABDOMEN

The echocardiogram in this patient demonstrated normal **left atrial** size based on 3 separate LA measurements. The cranial and caudal **mitral** valve leaflets presented normal linear structure and kinetics.. The **left ventricle** presented normal thicknesses with linear contour and was not dilated nor restricted. The **myocardium** presented normal echogenicity without subjective evidence of significant fibrotic or ischemic disease. **Contractility** of the ventricular walls was adequate and in normal range for this patient evidenced by the fractional shortening measurement and subjective evaluation of the different regions and angles of the myocardium. The **left ventricular outflow** tract demonstrated normal laminar flow and subjective structural integrity. The **right atrium** and auricle revealed normal size, structure and content. No evidence of masses was noted or chamber overload. Minor **tricuspid** insufficiency was noted and measured 2.0 m/sec. The **right ventricle** was of normal size (1/3 diameter of LV), chordae structure, myocardial echogenicity and thickness. **Pulmonic** tract assessment revealed normal valve structure, laminar flow, and diameter (approx.1:1 pa/ao ratio). No visible **pericardial** or free pleura fluid was noted or extra cardiac pathology in the visible planes. The cranial **mediastinum** and **pericardial regions** were free of masses in the visible window. Tachycardia was present.

FELINE CARDIAC PARAMETERS	BODY WEIGHT	HR (BPM)	IVSd (cm)	LVIDd (cm)	LVWd (cm)	FS (%)	EF (%)
NORMAL PARAMETER	-----	150-240	0.3-0.6	1.0-2.1	0.25-0.6	35-67	80-100
PATIENT	15.1 lbs	246	0.56	1.8	0.36	55	88
FELINE CARDIAC PARAMETERS	LA/AO (Boon)	LA/AO HEART BASE (Sisson)	LA 2D 4-chamber long axis AS to FW (Sisson) (cm)	LVOT VEL. (m/s)	RVOT VEL. (m/s)	IVRT (m/)	
NORMAL PARAMETER	<1.5	0.88-1.79	0.7-1.7	<1.6	<1.3	40-60	
PATIENT	1.3	1.42	1.6	1.0		NM	
Adapted from June Boon, Veterinary Echocardiography, 1998 Sisson D et al. JVIM 1991; 5: 232, Jacobs et al. Am J Vet Res 1985; 46:1705							

INVOICE

31227

DATE

6/24/22

ULTRASONOGRAPHIC FINDINGS

Trivial tricuspid insufficiency, not clinically significant.

Otherwise, unremarkable heart.

Persistent tachycardia was noted.



PATIENT

Kiko Palmer Kehma

SPECIES

Feline

BREED

Siamese Mix

SEX

Neutered male

AGE

12 years

WEIGHT

15.1 lbs

INTERPRETED BY

Eric Lindquist, DMV
DABVP, Cert. IVUSS

IMAGING PERFORMED BY

Diane McFadden, RVT

HOSPITAL NAME

Rockaway AH

REFERRING VET

Dr. Gannon

INVOICE

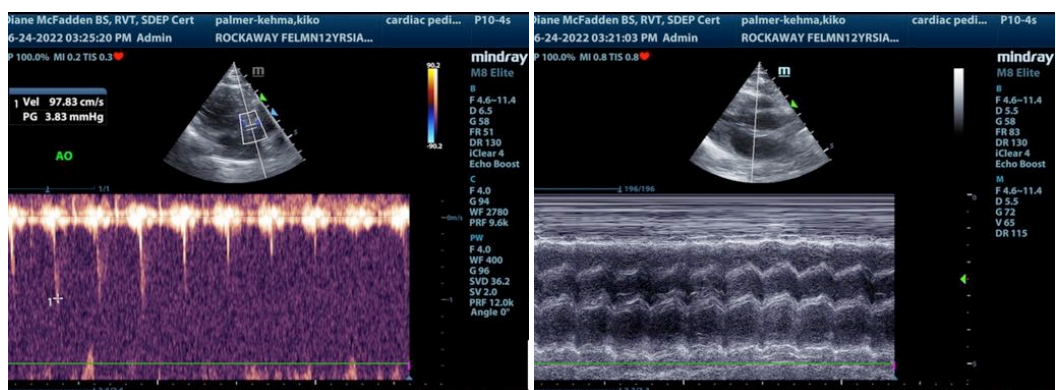
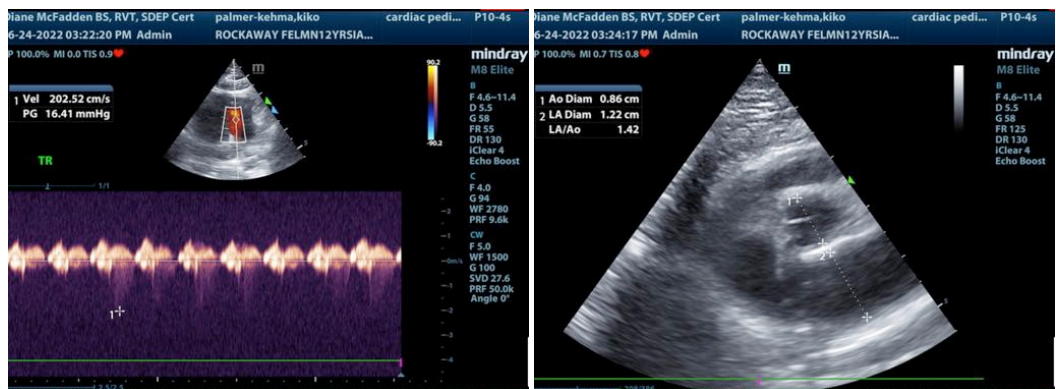
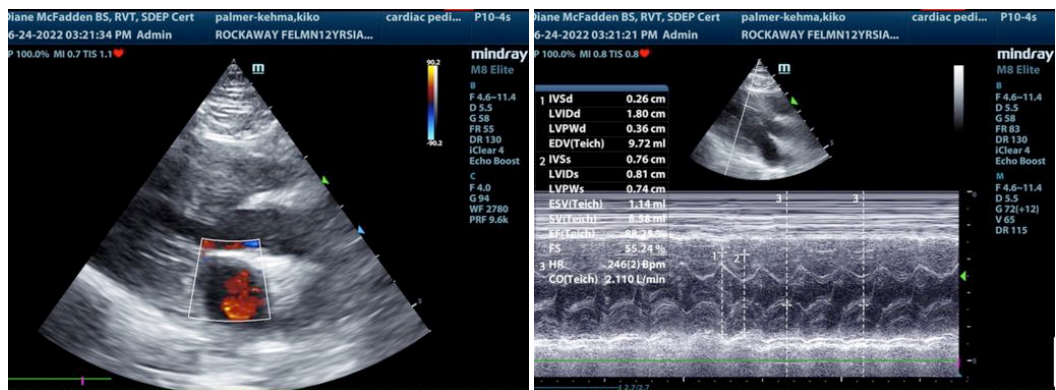
31227

DATE

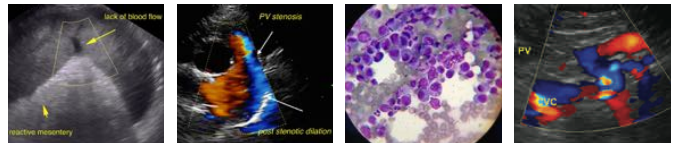
6/24/22

INTERPRETATION OF THE FINDINGS & FURTHER RECOMMENDATIONS

There is no contraindication to anesthetic procedure or Doxorubicin therapy. A recheck echocardiogram is recommended after 3 Doxorubicin treatments or earlier if any clinical signs develop. However, the heart appears largely unremarkable for this age patient. The tachycardia may be owing to excitement; however, assessment for hyperthyroidism is warranted if not already performed.



The information and recommendations provided are based on the images presented by the referring veterinarian/sonographer. No evaluation can be communicated regarding pathology that was not visible in the image/video clips provided.



PATIENT

Kiko Palmer Kehma

Thank you for this referral. If the clinical or image interpretation does not parallel your findings or if I can be of any further assistance please contact me.

SPECIES

Feline

Eric Lindquist, DMV, DABVP, Cert. IVUSS, CEO of SonoPath.com
Info@SonoPath.com

BREED

Siamese Mix

SEX

Neutered male

AGE

12 years

WEIGHT

15.1 lbs

INTERPRETED BY

Eric Lindquist, DMV
DABVP, Cert. IVUSS

**IMAGING
PERFORMED BY**

Diane McFadden, RVT

HOSPITAL NAME

Rockaway AH

REFERRING VET

Dr. Gannon

INVOICE

31227

DATE

6/24/22