



PATIENT

Maurice Rodriguez

PRESENTING CLINICAL SIGNS

History: recheck abdomen; defecated out more FB material; rads appear clear

SPECIES

Canine

ULTRASONOGRAPHIC EXAMINATION OF THE ABDOMEN

Urinary System

The **urinary bladder**, trigone, and pelvic urethra presented normal thicknesses and normal tone. The ureters were not visible which is normal. No uroliths or sediment were visualized and anechoic urine was present. No evidence of inflammatory or neoplastic changes was noted. Ureteral papillae were normal.

BREED

Pitbull Cross

The residual prostate was similar to the prior sonogram and measured 1.6 cm. The prostate was heterogenous and remodeled.

SEX

Neutered male

The **kidneys** revealed normal size and structure, corticomedullary definition and ratio for this age. The cortices presented largely uniform texture with normal echogenic relationship to liver and spleen. Medullary structure differed distinctly from the cortex and no evidence of pelvic dilation was present. The capsules were acceptably uniform without significant irregularities. The left kidney measured 6.86 cm. The right kidney measured 6.32 cm.

AGE

12 years

WEIGHT

53 lbs

Adrenal Glands

The left **adrenal gland** was uniform. The right adrenal gland was slightly swollen at the caudal pole. The right adrenal gland measured 3.38 x 1.09 cm at the caudal pole and 0.63 cm at the cranial pole. The left adrenal gland measured 2.5 x 1.21 cm at the cranial pole and 0.78 cm at the caudal pole.

INTERPRETED BY

Eric Lindquist, DMV
DABVP, Cert. IVUSS

Spleen

The **spleen** presented a smooth homogeneous parenchyma hyperechoic to liver and renal cortical parenchyma. The capsule was smooth without noticeable expansion or deviation from within the spleen or adjacent pathology. The splenic vasculature demonstrated normal volume without signs of congestion or thrombosis. No sonographic evidence of acute or chronic inflammatory, neoplastic, or infarctual changes was noted.

IMAGING PERFORMED BY

Diane McFadden, RVT

HOSPITAL NAME

Rockaway AH

Liver

The **liver** images submitted revealed subjectively normal liver size, contour, and structure. Parenchymal echogenicity was naturally coarse and hypoechoic to the spleen. Vascular and biliary tracts were of normal volume with no evidence of congestion. The gallbladder presented acceptably thin walls with primarily anechoic content. The cystic and common bile ducts were normal. No pathological hepatic lymphadenopathy was evident. No overt structural evidence of inflammatory, infiltrative or regenerative pathology was evident.

REFERRING VET

Dr. Manair

INVOICE

47901

DATE

6/22/23

Gastrointestinal

Examination of the **gastrointestinal tract** revealed a stomach and intestine free of stasis, of normal wall thickness, acceptable curvilinear mural detail, and peristaltic activity. Small and large intestine



PATIENT

Maurice Rodriguez

demonstrated normal luminal chyme and stool consistency respectively. The colon was mildly thickened, yet soft stool was present.

SPECIES

Canine

Pancreas

The base and limbs of the **pancreas** were observed to be largely isoechoic to surrounding omental fat. Pancreatic duct and capsular contour were acceptably normal and parenchyma respected normal curvilinear patterns. No overt evidence of active inflammatory or neoplastic disease was noted.

BREED

Pitbull Cross

ULTRASONOGRAPHIC FINDINGS

SEX

Neutered male

Minor colonic thickening.

INTERPRETATION OF THE FINDINGS & FURTHER RECOMMENDATIONS

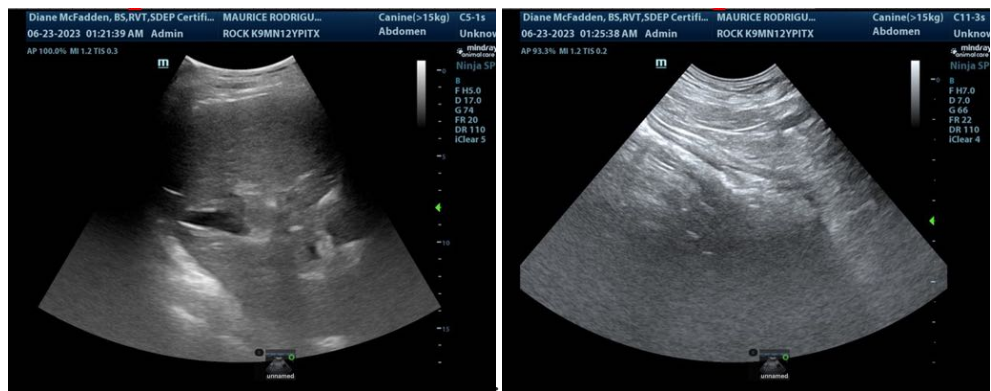AGE

12 years

There was no further evidence of foreign matter. Supportive care should prove effective.

WEIGHT

53 lbs

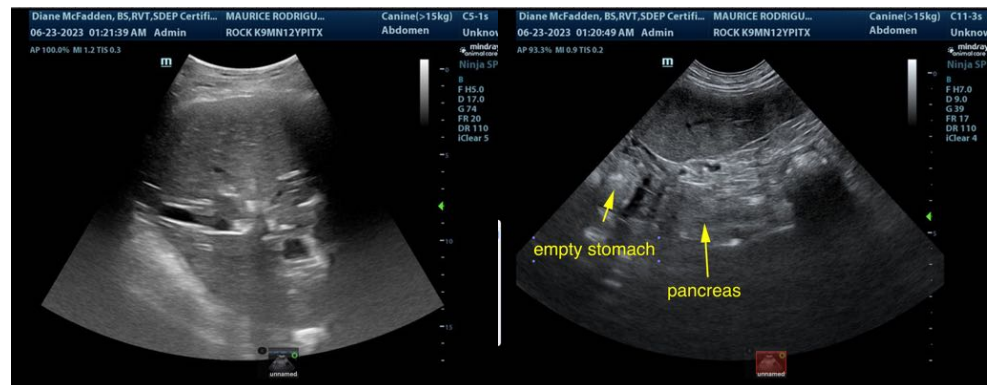


INTERPRETED BY

Eric Lindquist, DMV
DABVP, Cert. IVUSS

IMAGING PERFORMED BY

Diane McFadden, RVT



HOSPITAL NAME

Rockaway AH

REFERRING VET

Dr. Manair

INVOICE

47901

DATE

6/22/23



PATIENT

Maurice Rodriguez

SPECIES

Canine

BREED

Pitbull Cross

SEX

Neutered male

AGE

12 years

WEIGHT

53 lbs

INTERPRETED BY

Eric Lindquist, DMV
DABVP, Cert. IVUSS

IMAGING PERFORMED BY

Diane McFadden, RVT

HOSPITAL NAME

Rockaway AH

REFERRING VET

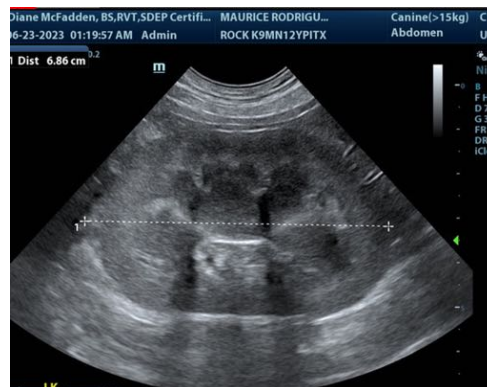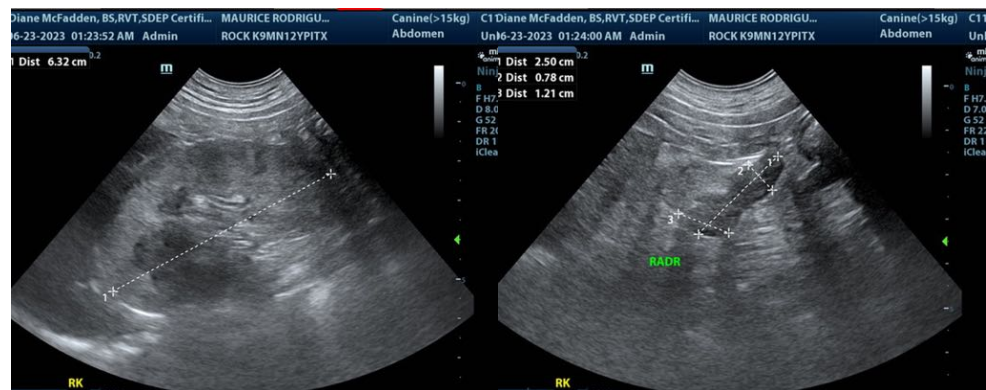
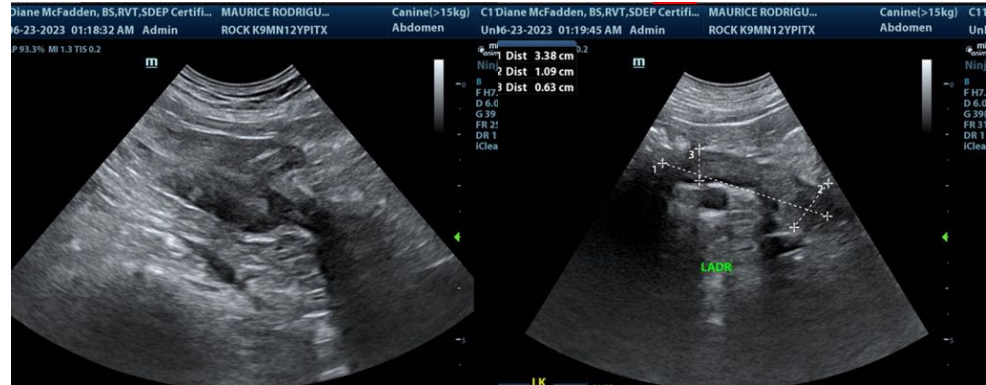
Dr. Manair

INVOICE

47901

DATE

6/22/23



The information and recommendations provided are based on the images presented by the referring veterinarian/sonographer. No evaluation can be communicated regarding pathology that was not visible in the image/video clips provided.

Thank you for this referral. If the clinical or image interpretation does not parallel your findings or if I can be of any further assistance please contact me.

Eric Lindquist, DMV, DABVP, Cert. IVUSS, CEO of SonoPath.com
Info@SonoPath.com