



**PATIENT**

Dakota Cottrell

**SPECIES**

Canine

**BREED**

Pitbull Mix

**SEX**

Spayed female

**AGE**

6 years

**WEIGHT**

81.9 lbs

**INTERPRETED BY**

Eric Lindquist, DMV  
DABVP, Cert. IVUSS

**IMAGING PERFORMED BY**

Valeryia Shumskaya

**HOSPITAL NAME**

Legacy AH

**REFERRING VET**

Dr. Potenzzone

**INVOICE**

47913

**DATE**

6/20/23

**PRESENTING CLINICAL SIGNS**

History: PU/PD, weight gain, enlarged liver on radiographs Current meds: Thyro tabs 0.3 BID, desmopressin 0.2 mg 1/4 BID

Abnormal PE/Chem/CBC/UA Results: Neg ACTH Stim, water dep test = consistent w DI. Desmopressin worked for 6 months no PU/PD and enlarged liver

**ULTRASONOGRAPHIC EXAMINATION OF THE ABDOMEN**

**Urinary System**

The **urinary bladder**, trigone, and pelvic urethra presented normal thicknesses and normal tone. The ureters were not visible which is normal. No uroliths or sediment were visualized and anechoic urine was present. No evidence of inflammatory or neoplastic changes was noted. Ureteral papillae were normal.

The **kidneys** revealed normal size and structure, corticomedullary definition and ratio for this age. The cortices presented largely uniform texture with normal echogenic relationship to liver and spleen. Medullary structure differed distinctly from the cortex and no evidence of pelvic dilation was present. The capsules were acceptably uniform without significant irregularities. The right kidney measured 8.6 cm. The left kidney measured 6.95 cm.

**Adrenal Glands**

Both **adrenal glands** were visualized and recognized as having normal shape, size, position and echogenicity for this breed. The phrenic vasculature, glandular echogenicity and detail were unremarkable. Capsule, cortex, and medullary definition were normal for this age patient. The left adrenal gland measured 1.78 x 0.5 cm at the cranial pole and 0.51 cm at the caudal pole. The right adrenal gland measured 2.79 x 1.58 cm at the cranial pole and 0.45 cm at the caudal pole.

**Spleen**

The **spleen** presented a smooth homogeneous parenchyma hyperechoic to liver and renal cortical parenchyma. The capsule was smooth without noticeable expansion or deviation from within the spleen or adjacent pathology. The splenic vasculature demonstrated normal volume without signs of congestion or thrombosis. No sonographic evidence of acute or chronic inflammatory, neoplastic, or infarctual changes was noted.

**Liver**

Exam of the cranial abdomen demonstrated excessive **liver** size, swollen contour, with conserved uniform architecture. Parenchymal echogenicity was diffusely isoechoic to the spleen and falciform fat. Minor excessive GB debris was noted with the presence gall bladder dilation and precipitate without the overt formation of mucocele but this may be an issue in the future. This type of liver presentation typically is associated with slow and gradual SAP elevations with low-grade ALT rise. USG-FNA sampling is encouraged if more aggressive LE profiles are present such as ALT > 200 or rapid rise in SAP. These presentations are usually reactive hepatopathies owing to other disease processes either



**PATIENT**

Dakota Cottrell

endocrine (Diabetes, Hypothyroidism, Cushing's disease), "antigen surveillance" from the gut/pancreas, or idiopathic breed predisposed progressions.

**SPECIES**

Canine

**Gastrointestinal**

**BREED**

Pitbull Mix

There was some residual chyme and gas was noted in the **stomach**, yet not pathological. This is consistent with end post prandial presentation. Transit of chyme into the small intestine was normal. Curvilinear patterns were maintained throughout the GI tract. Mucosal fogging was noted in portions of the small intestine and the changes were fairly minor. The albumin levels should be monitored in this patient periodically. No evidence of pathology. Small and large intestine demonstrated normal luminal chyme and stool consistency respectively. No obstructive or overt infiltrative disease was noted. No associated abnormal lymphatic activity was noted.

**SEX**

Spayed female

**Pancreas**

**AGE**

6 years

The base and limbs of the **pancreas** were observed to be largely isoechoic to surrounding omental fat. Pancreatic duct and capsular contour were acceptably normal and parenchyma respected normal curvilinear patterns. No overt evidence of active inflammatory or neoplastic disease was noted.

**WEIGHT**

81.9 lbs

**ULTRASONOGRAPHIC FINDINGS**

Structurally unremarkable abdomen with vacuolar hepatopathy liver pattern and minor intestinal mucosal fogging.

**INTERPRETED BY**

Eric Lindquist, DMV  
DABVP, Cert. IVUSS

Otherwise, structurally unremarkable abdomen.

**IMAGING PERFORMED BY**

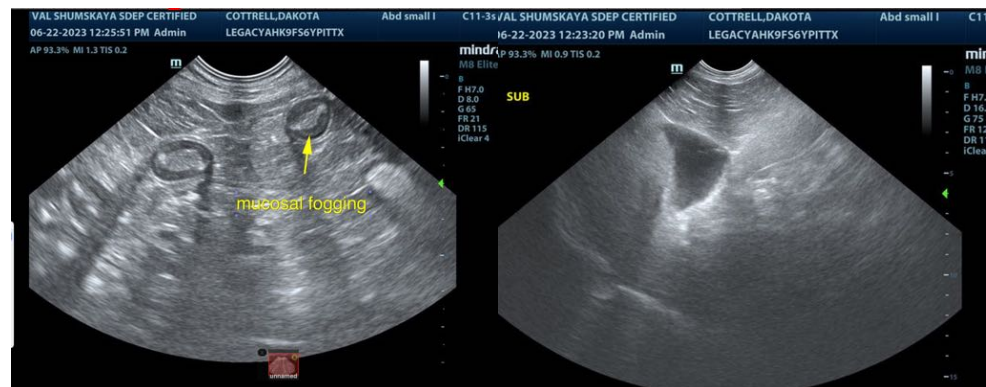
Valeryia Shumskaya

**INTERPRETATION OF THE FINDINGS & FURTHER RECOMMENDATIONS**

The albumin levels should be monitored periodically.

**HOSPITAL NAME**

Legacy AH



**REFERRING VET**

Dr. Potenzzone

**INVOICE**

47913

**DATE**

6/20/23



**PATIENT**

Dakota Cottrell

**SPECIES**

Canine

**BREED**

Pitbull Mix

**SEX**

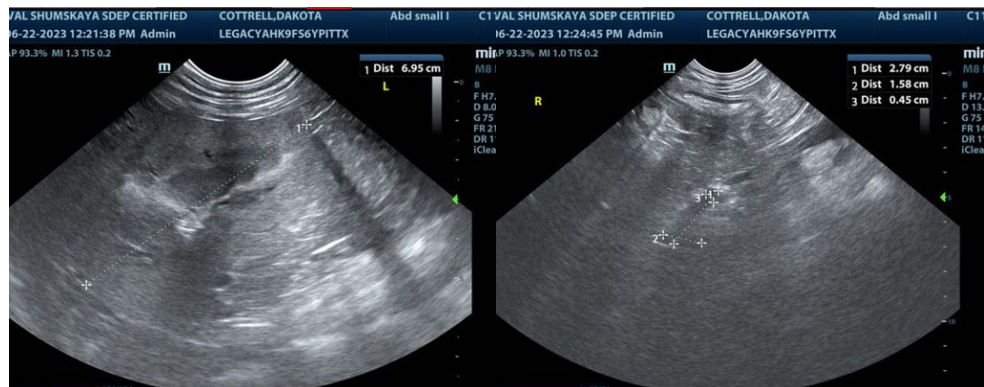
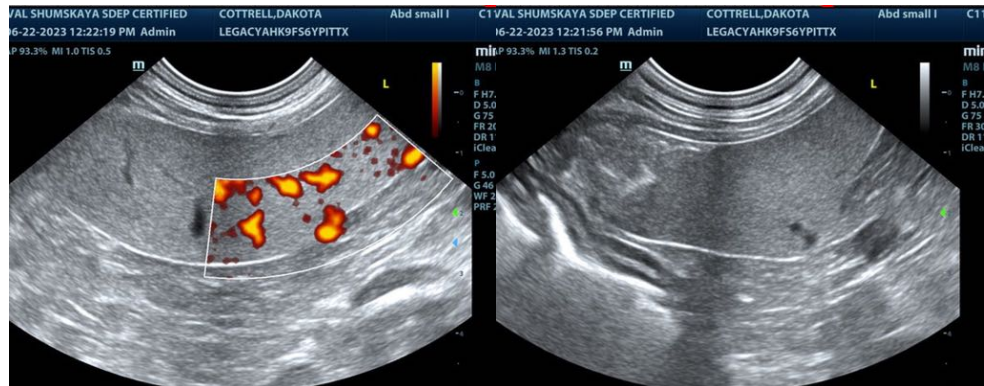
Spayed female

**AGE**

6 years

**WEIGHT**

81.9 lbs



**INTERPRETED BY**

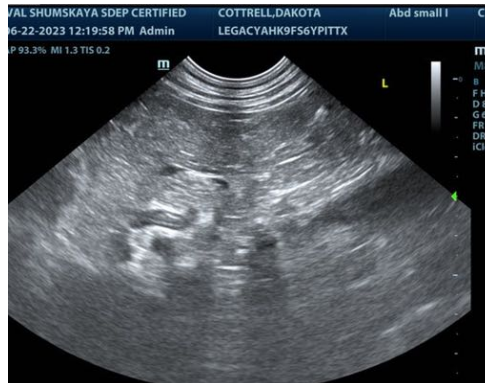Eric Lindquist, DMV  
DABVP, Cert. IVUSS

**IMAGING PERFORMED BY**

Valeryia Shumskaya

**HOSPITAL NAME**

Legacy AH



**REFERRING VET**

Dr. Potenzzone

The information and recommendations provided are based on the images presented by the referring veterinarian/sonographer. No evaluation can be communicated regarding pathology that was not visible in the image/video clips provided.

Thank you for this referral. If the clinical or image interpretation does not parallel your findings or if I can be of any further assistance please contact me.

**INVOICE**

47913

**DATE**

6/20/23

Eric Lindquist, DMV, DABVP, Cert. IVUSS  
info@SonoPath.com