



PATIENT

Mickey Rzucidlo

PRESENTING CLINICAL SIGNS

History: Recheck-microhepatica vs mvd vs shunt

SPECIES

Canine

ULTRASONOGRAPHIC EXAMINATION OF THE ABDOMEN

Urinary System

BREED

Chihuahua

The **urinary bladder**, trigone, and pelvic urethra presented normal thicknesses and normal tone. The ureters were not visible which is normal. No uroliths or sediment were visualized and anechoic urine was present. No evidence of inflammatory or neoplastic changes was noted. Ureteral papillae were normal.

SEX

Male

The residual prostate was uniform and measured 0.54 cm.

AGE

6 months

The **kidneys** revealed normal size and structure, corticomedullary definition and ratio for this age. The cortices presented largely uniform texture with normal echogenic relationship to liver and spleen. Medullary structure differed distinctly from the cortex and no evidence of pelvic dilation was present. The capsules were acceptably uniform without significant irregularities. The left kidney measured 3.62 cm. The right kidney measured 3.68 cm.

WEIGHT

7.2 lbs

Adrenal Glands

Both **adrenal glands** were visualized and recognized as having normal shape, size, position and echogenicity for this breed. The phrenic vasculature, glandular echogenicity and detail were unremarkable. Capsule, cortex, and medullary definition were normal for this age patient. The right adrenal gland measured 1.23 x 0.26 cm at the caudal pole and 0.29 cm at the cranial pole.

INTERPRETED BY

Eric Lindquist, DMV
DABVP, Cert. IVUSS

Spleen

IMAGING PERFORMED BY

Shari Reffi, CVT

The **spleen** presented a smooth homogeneous parenchyma hyperechoic to liver and renal cortical parenchyma. The capsule was smooth without noticeable expansion or deviation from within the spleen or adjacent pathology. The splenic vasculature demonstrated normal volume without signs of congestion or thrombosis. No sonographic evidence of acute or chronic inflammatory, neoplastic, or infarctual changes was noted.

HOSPITAL NAME

Rockaway AH

Liver

REFERRING VET

Dr. Maniar

The **liver** is persistently subnormal in size. Vascular and biliary tracts were of normal volume with no evidence of congestion. The portal vein to vena cava ratio was 1:1. The portal vein measured 0.5 cm and the vena cava measured 0.45 cm. There was no evidence of intrahepatic or extrahepatic shunting. The gallbladder presented acceptably thin walls with primarily anechoic content. The cystic and common bile ducts were normal. No pathological hepatic lymphadenopathy was evident. No overt structural evidence of inflammatory, infiltrative or regenerative pathology was evident.

INVOICE

31060

DATE

6/16/22



PATIENT

Gastrointestinal

Mickey Rzucidlo

Examination of the **gastrointestinal tract** revealed a stomach and intestine free of stasis, of normal wall thickness, acceptable curvilinear mural detail, and peristaltic activity. Small and large intestine demonstrated normal luminal chyme and stool consistency respectively. No obstructive or overt infiltrative disease was noted. No associated abnormal lymphatic activity was noted.

SPECIES

Canine

BREED

Chihuahua

Pancreas

The base and limbs of the **pancreas** were observed to be largely isoechoic to surrounding omental fat. Pancreatic duct and capsular contour were acceptably normal and parenchyma respected normal curvilinear patterns. No overt evidence of active inflammatory or neoplastic disease was noted.

SEX

Male

ULTRASONOGRAPHIC FINDINGS

Mild microhepatica.

AGE

6 months

INTERPRETATION OF THE FINDINGS & FURTHER RECOMMENDATIONS

WEIGHT

7.2 lbs

There was no evidence of macroscopic shunting. If the bile acids are persistently elevated then portal hypoplasia with concurrent hepatic insult is likely. Coagulation panel followed by core biopsy would be necessary from surgical or ultrasound-guided perspective. Strict dietary regiment avoiding any acute phase disease regarding the GI or pancreas is strongly recommended given the microhepatica as long term hepatic function is likely somewhat compromised from a congenital standpoint.

INTERPRETED BY

Eric Lindquist, DMV
DABVP, Cert. IVUSS

Hepatic Support for Bile Acid Elevation +/- Hepatic Encephalopathy

IMAGING PERFORMED BY

Shari Reffi, CVT

Royal Canin Hepatic Support diet or Hills L/D, Metronidazole (7.5 mg/kg PO bid) over the next 14 days, Lactulose (Oral: 3.1-3.7 g/5 ml lactulose in a syrup base) long term to target 2-3 soft stools/day, with a high-quality protein supplement of minor amount of yogurt or cheddar cheese. Monitor bile acids, with attention paid to dropping albumin, BUN or cholesterol. SAME and nutraceuticals as needed. Ursodiol (10-15 mg/kg p.o. q24h) can be considered as hepatoprotectant and to enhance bile flow. Zinc serum level keep between 200–500 ug/dl. If deficient then Tx zinc acetate 1-3 mg/kg/day. Gastrointestinal protectants are recommended if the patient is anorexic.

HOSPITAL NAME

Rockaway AH

REFERRING VET

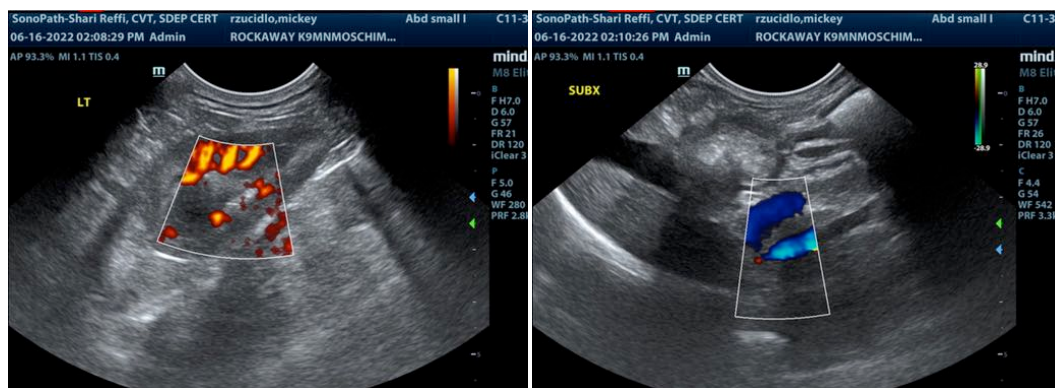
Dr. Maniar

INVOICE

31060

DATE

6/16/22





PATIENT

Mickey Rzucidlo

SPECIES

Canine

BREED

Chihuahua

SEX

Male

AGE

6 months

WEIGHT

7.2 lbs

INTERPRETED BY

Eric Lindquist, DMV
DABVP, Cert. IVUSS

IMAGING PERFORMED BY

Shari Reffi, CVT

HOSPITAL NAME

Rockaway AH

REFERRING VET

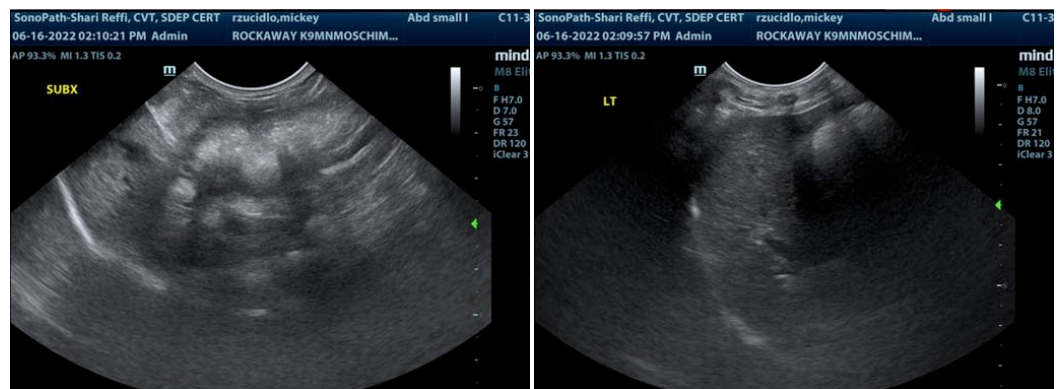
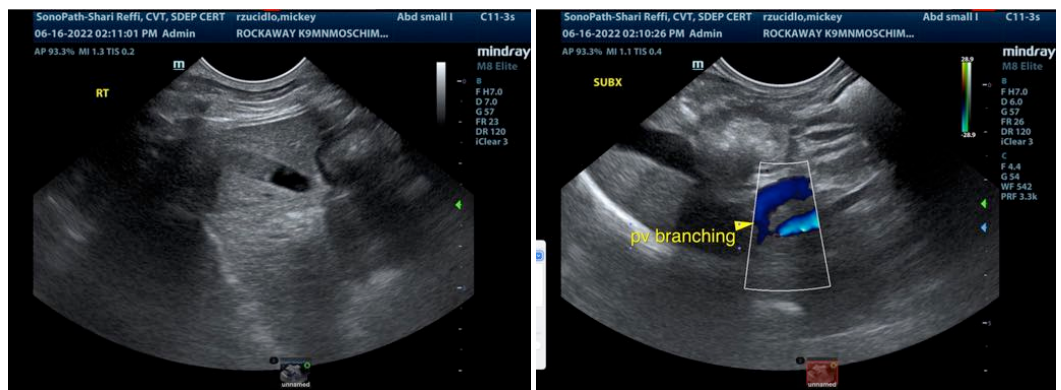
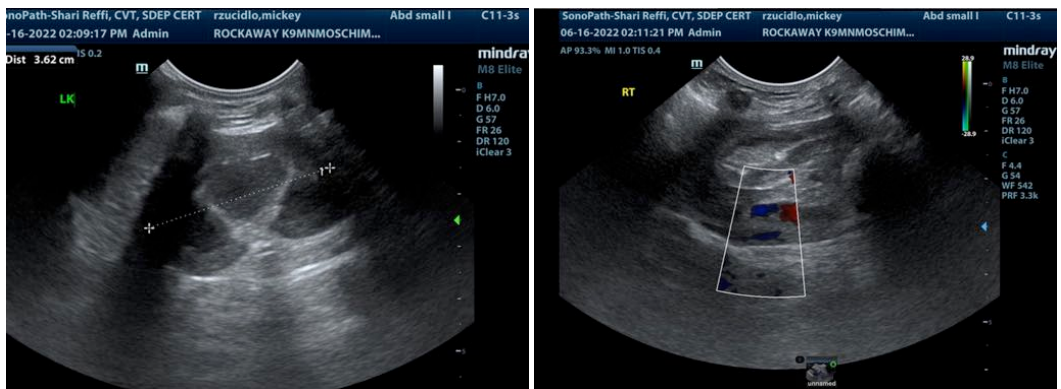
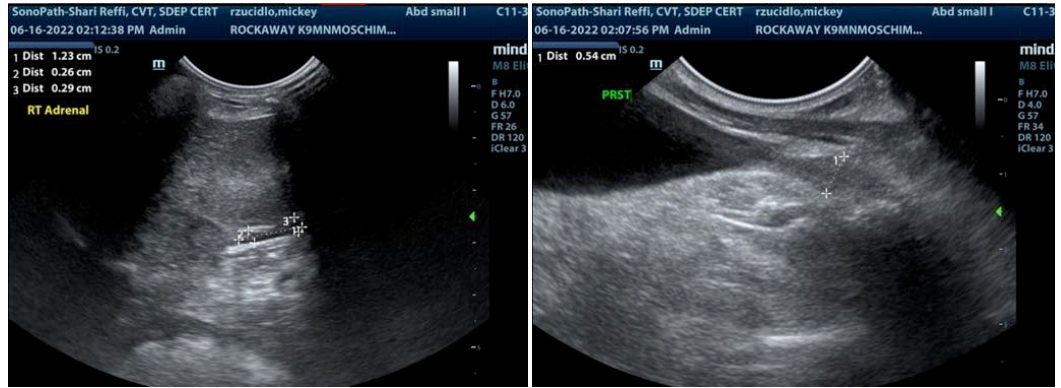
Dr. Maniar

INVOICE

31060

DATE

6/16/22





PATIENT

Mickey Rzucidlo

The information and recommendations provided are based on the images presented by the referring veterinarian/sonographer. No evaluation can be communicated regarding pathology that was not visible in the image/video clips provided.

SPECIES

Canine

Thank you for this referral. If the clinical or image interpretation does not parallel your findings or if I can be of any further assistance please contact me.

BREED

Chihuahua

Eric Lindquist, DMV, DABVP, Cert. IVUSS, CEO of SonoPath.com
Info@SonoPath.com

SEX

Male

AGE

6 months

WEIGHT

7.2 lbs

INTERPRETED BY

Eric Lindquist, DMV
DABVP, Cert. IVUSS

**IMAGING
PERFORMED BY**

Shari Reffi, CVT

HOSPITAL NAME

Rockaway AH

REFERRING VET

Dr. Maniar

INVOICE

31060

DATE

6/16/22