



PATIENT

Isabel Hanrahan

SPECIES

Canine

BREED

Coton de Tulear

SEX

Intact female

AGE

5 years

WEIGHT

12.1 lbs

INTERPRETED BY

Eric Lindquist, DMV,
DABVP, Cert. IVUSS,
CEO of SonoPath.com

IMAGING PERFORMED BY

Kelly Vazquez, CVT

HOSPITAL NAME

Oakland AH

REFERRING VET

Dr. Pellicano

INVOICE

44741

DATE

6/14/23

PRESENTING CLINICAL SIGNS

History: Patient presents for pregnancy confirmation, estimated count, and viability. Bred on May 20 & 21, 2023.

ULTRASONOGRAPHIC EXAMINATION OF THE ABDOMEN

The **urinary bladder**, trigone, and pelvic urethra presented normal thicknesses and normal tone. The ureters were not visible which is normal. No uroliths or sediment were visualized and anechoic urine was present. No evidence of inflammatory or neoplastic changes was noted. Ureteral papillae were normal.

The uterus in this patient revealed viable fetuses. The fetal sac measured 1.52 x 0.87 cm. The uterus was empty. Otherwise, no accumulation of fluid was present. Viable heart beats are noted. The fetal length measured 0.8 cm. Amniotic fluid was anechoic. There was no evidence of pathology. There are approximately 4-5 live fetuses appear to be present. The patient is approximately 23 days +/- 3 in gestation. Note that fetal count can change during gestation with various reabsorption and expulsion, yet there was no evidence of pathology noted.

ULTRASONOGRAPHIC FINDINGS

Live pregnancy, approximately 4-5 fetuses. Approximately 23 days of gestation.

INTERPRETATION OF THE FINDINGS & FURTHER RECOMMENDATIONS

.No specific therapy is necessary at this time.





PATIENT

Isabel Hanrahan

SPECIES

Canine

BREED

Coton de Tulear

SEX

Intact female

AGE

5 years

WEIGHT

12.1 lbs

INTERPRETED BY

Eric Lindquist, DMV,
DABVP, Cert. IVUSS,
CEO of SonoPath.com

IMAGING PERFORMED BY

Kelly Vazquez, CVT

HOSPITAL NAME

Oakland AH

REFERRING VET

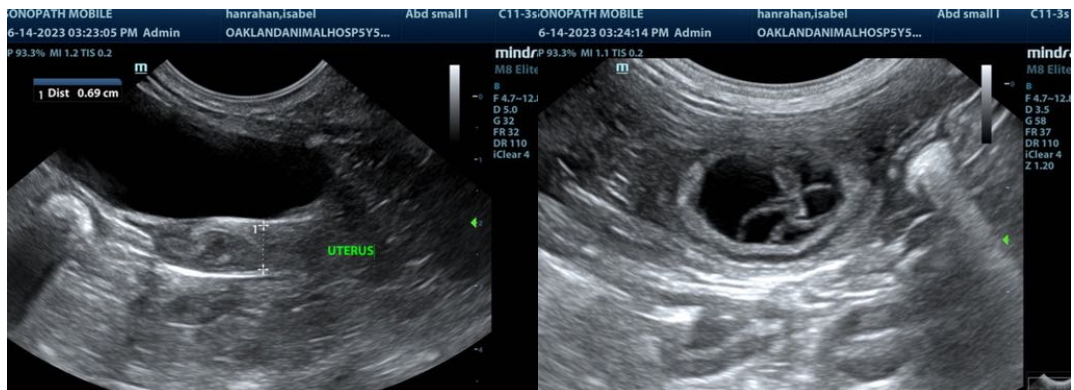
Dr. Pellicano

INVOICE

44741

DATE

6/14/23



The information and recommendations provided are based on the images presented by the referring veterinarian/sonographer. No evaluation can be communicated regarding pathology that was not visible in the image/video clips provided.

Thank you for this referral. If the clinical or image interpretation does not parallel your findings or if I can be of any further assistance please contact me.

Eric Lindquist, DMV, DABVP, Cert. IVUSS, CEO of SonoPath.com

Info@SonoPath.com