SonoPath
Clinical Sonography & Telecytology

EDUCATIONAL TELECONSULTATION SERVICES™

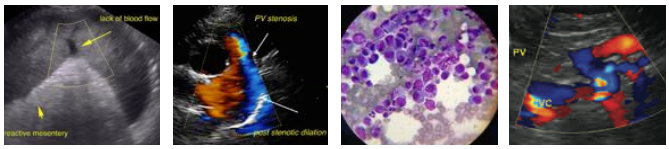

SonoPath.com™
1-800-838-4268 info@sonopath.com

PATIENT
Molly Horan

SPECIES
Canine

BREED
Cokapoo

SEX
Female

AGE
1 year

WEIGHT
13 lbs

INTERPRETED BY
Eric Lindquist, DMV
DABVP, Cert. IVUSS

IMAGING PERFORMED BY
Shari Reffi, CVT

HOSPITAL NAME
Tranquility VC

REFERRING VET
Dr. Christensen

INVOICE
30810

DATE
5/25/22

PRESENTING CLINICAL SIGNS

History: Elevated ALT and bile acids. No current meds.
Abnormal PE/Chem/CBC/UA Results: ALT >600, post-prandial bile acid >100. Lepto PCR pending

ULTRASONOGRAPHIC EXAMINATION OF THE ABDOMEN

Urinary System

The **urinary bladder**, trigone, and pelvic urethra presented normal thicknesses and normal tone. The ureters were not visible which is normal. No uroliths or sediment were visualized and anechoic urine was present. No evidence of inflammatory or neoplastic changes was noted. Ureteral papillae were normal.

The uterus was uniform and measured 0.82 cm.

The **kidneys** revealed normal size and structure, corticomedullary definition and ratio for this age. The cortices presented largely uniform texture with normal echogenic relationship to liver and spleen. Medullary structure differed distinctly from the cortex and no evidence of pelvic dilation was present. The capsules were acceptably uniform without significant irregularities. The left kidney measured 3.6 cm.

Adrenal Glands

Both **adrenal glands** were visualized and recognized as having normal shape, size, position and echogenicity for this breed. The phrenic vasculature, glandular echogenicity and detail were unremarkable. Capsule, cortex, and medullary definition were normal for this age patient. The right adrenal gland measured 1.28 x 0.88 cm at the cranial pole and 0.43 cm at the caudal pole. The left adrenal gland measured 1.73 x 0.41 cm at the cranial pole and 0.4 cm at the caudal pole.

Spleen

The **spleen** presented a smooth homogeneous parenchyma hyperechoic to liver and renal cortical parenchyma. The capsule was smooth without noticeable expansion or deviation from within the spleen or adjacent pathology. The splenic vasculature demonstrated normal volume without signs of congestion or thrombosis. No sonographic evidence of acute or chronic inflammatory, neoplastic, or infarctual changes was noted.

Liver

The **liver** presented slightly increased portal markings. The portal vein to vena cava ratio was 1:1 and both measured 0.6 cm. The gallbladder fossa revealed a hyperechoic linear structure. This may represent gallbladder malformation or complete gallbladder. The common bile duct was normal at 0.2 cm. There was no evidence of post hepatic disease.

SonoPath
Clinical Sonography & Telecytology

EDUCATIONAL TELECONSULTATION SERVICES™

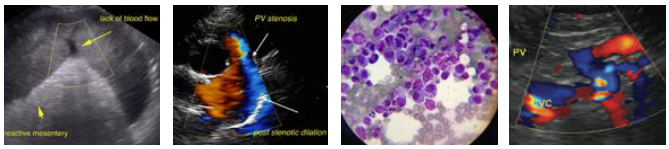

SonoPath.com™
1-800-838-4268 info@sonopath.com

PATIENT

Molly Horan

SPECIES

Canine

BREED

Cokapoo

SEX

Female

AGE

1 year

WEIGHT

13 lbs

INTERPRETED BY

Eric Lindquist, DMV
DABVP, Cert. IVUSS

IMAGING PERFORMED BY

Shari Reffi, CVT

HOSPITAL NAME

Tranquility VC

REFERRING VET

Dr. Christensen

INVOICE

30810

DATE

5/25/22

Gastrointestinal

Examination of the **gastrointestinal tract** revealed a stomach and intestine free of stasis, of normal wall thickness, acceptable curvilinear mural detail, and peristaltic activity. Small and large intestine demonstrated normal luminal chyme and stool consistency respectively. No obstructive or overt infiltrative disease was noted. No associated abnormal lymphatic activity was noted.

Pancreas

The base and limbs of the **pancreas** were observed to be largely isoechoic to surrounding omental fat. Pancreatic duct and capsular contour were acceptably normal and parenchyma respected normal curvilinear patterns. No overt evidence of active inflammatory or neoplastic disease was noted.

ULTRASONOGRAPHIC FINDINGS

Non-specific inflammatory hepatopathy.

Gallbladder aplasia is suspected.

INTERPRETATION OF THE FINDINGS & FURTHER RECOMMENDATIONS

There was no evidence of intrahepatic or extrahepatic shunting. The cause of acute on chronic inflammatory hepatopathy such as Leptospirosis, mushroom toxicity or similar should be considered. Core liver biopsy may be necessary for further definition. The liver was slightly subnormal in size. Concurrent microvascular dysplasia/portal vein hypoplasia may be an issue. IV fluid support, Ampicillin, Metronidazole and GI protectants as well as hepatic nutraceuticals are all indicated until sampling results can be further evaluated as well as Leptospirosis titers.

SonoPath

Clinical Sonography & Telecytology

EDUCATIONAL TELECONSULTATION SERVICES™

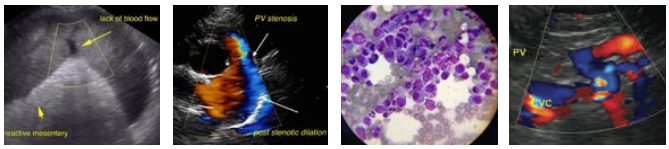

SonoPath.com™
1-800-838-4268 info@sonopath.com

PATIENT

Molly Horan

SPECIES

Canine

BREED

Cokapoo

SEX

Female

AGE

1 year

WEIGHT

13 lbs

INTERPRETED BY

Eric Lindquist, DMV
DABVP, Cert. IVUSS

IMAGING PERFORMED BY

Shari Reffi, CVT

HOSPITAL NAME

Tranquility VC

REFERRING VET

Dr. Christensen

INVOICE

30810

DATE

5/25/22

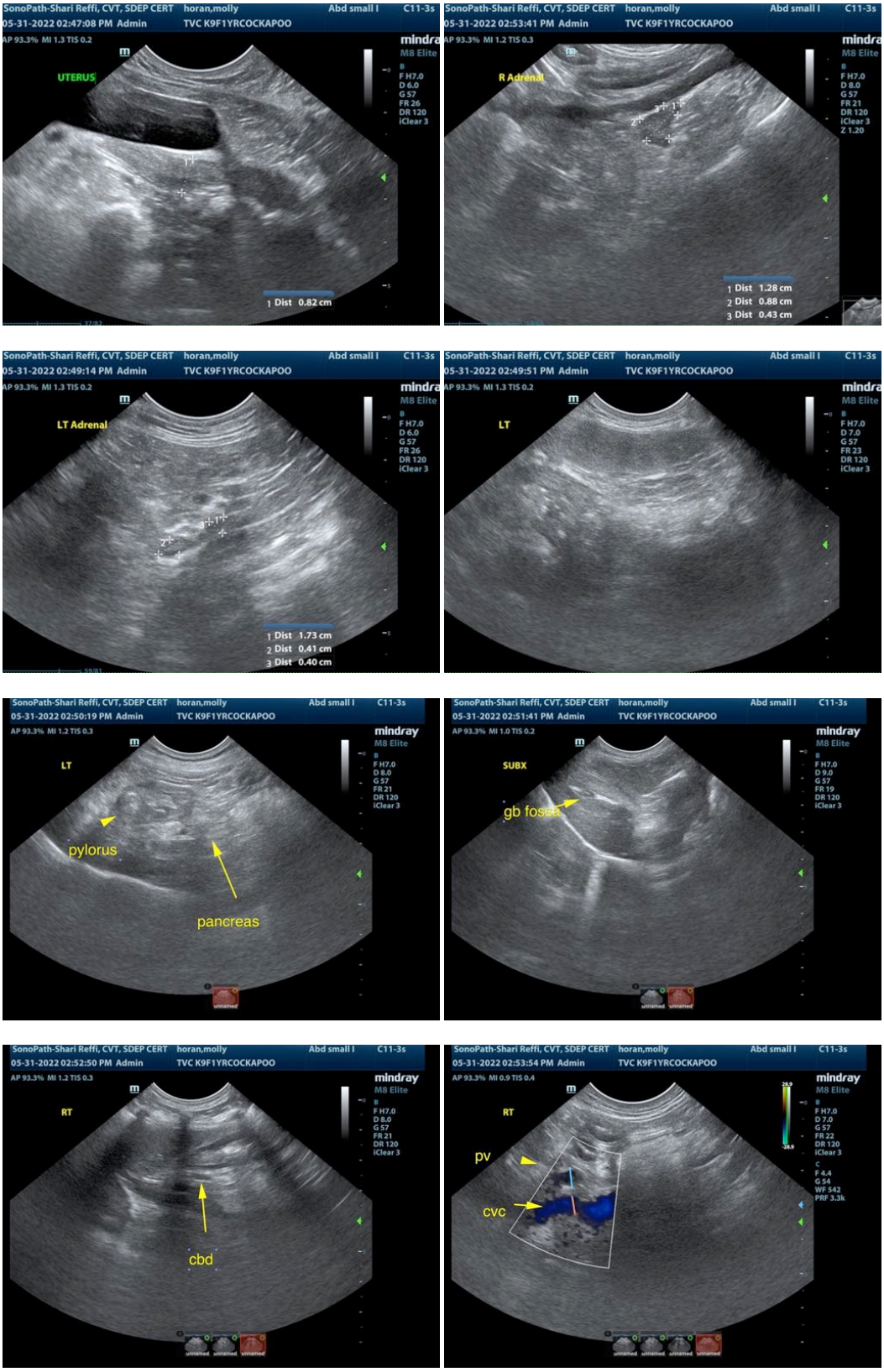

SonoPath
Clinical Sonography & Telecytology

EDUCATIONAL TELECONSULTATION SERVICES™

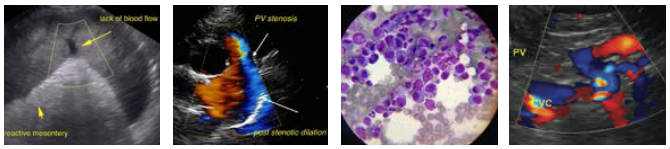

SonoPath.com™
1-800-838-4268 info@sonopath.com

PATIENT

Molly Horan

SPECIES

Canine

BREED

Cokapoo

SEX

Female

AGE

1 year

WEIGHT

13 lbs

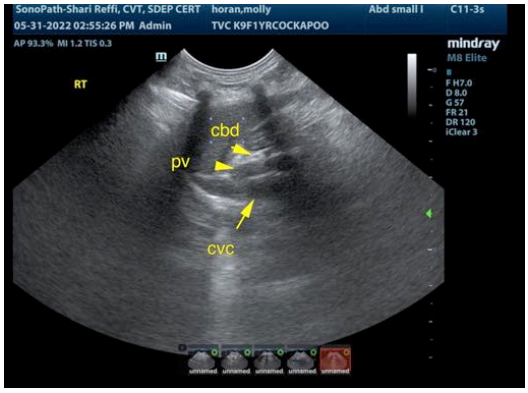

INTERPRETED BY

Eric Lindquist, DMV
DABVP, Cert. IVUSS

IMAGING PERFORMED BY

Shari Reffi, CVT

HOSPITAL NAME

Tranquility VC

REFERRING VET

Dr. Christensen

INVOICE

30810

DATE

5/25/22

The information and recommendations provided are based on the images presented by the referring veterinarian/sonographer. No evaluation can be communicated regarding pathology that was not visible in the image/video clips provided.

Thank you for this referral. If the clinical or image interpretation does not parallel your findings or if I can be of any further assistance please contact me.

Eric Lindquist, DMV, DABVP, Cert. IVUSS, CEO of SonoPath.com
Info@SonoPath.com