


**PATIENT PRESENTING CLINICAL SIGNS**

Tonka Craig History: white gums noted on exam. On furosemide and thyroxine

**SPECIES ULTRASONOGRAPHIC EXAMINATION OF THE HEART**

Canine

A 4.8 x 2.5 cm, mildly echogenic heart base mass. The mass appeared to be wrapping the aorta. Occasional arrhythmia was noted. The cardiac presentation in this patient revealed normal left sided volume with occasional tachyarrhythmia. The hepatic veins were not dilated. There was no pericardial or pleural effusion.

**BREED**

American Bulldog

**SEX**

Intact male

**AGE**

9 years

**WEIGHT**

58.4 lbs

**INTERPRETED BY**

 Eric Lindquist, DMV  
 DABVP, Cert. IVUSS

**IMAGING PERFORMED BY**

Diane McFadden, RVT

**HOSPITAL NAME**

North Warren AH

**REFERRING VET**

Dr. Corrado

**INVOICE**

30753

**DATE**

5/26/22

CANINE	MR	TR	LA/AO	LA/AO	FS	EF	EPSS
<b>CARDIAC PARAMETERS</b>	<b>VMAX</b> (m/s)	<b>VMAX</b> (m/s)	(Boon method)	(Heart Base; Swe)	(%)	(%)	(cm)
<b>NORMAL PARAMETER</b>	4.5-5.5	<2.7	1.3	<1.3	28-40	40-100	<0.6
<b>PATIENT</b>			2.07	1.35	30	80	NM
CANINE	HR	AV	PV	BODY WEIGHT	LA	LVIDd	LVIDs
<b>CARDIAC PARAMETERS</b>	(BPM)	<b>VMAX</b> (m/s)	<b>MAX</b> (m/s)		2D short axis Base view (cm)	Avg; 2D and m-mode short axis (cm)	Avg; 2D and m-mode short axis (cm)
<b>NORMAL PARAMETER</b>	50-100	0.7-1.7	0.7-1.6				
<b>PATIENT</b>			1.0	58.4 lbs		3.0	

**ULTRASONOGRAPHIC FINDINGS**

Heart base mass. Suspect chemodectoma/aortic body tumor.

**INTERPRETATION OF THE FINDINGS & FURTHER RECOMMENDATIONS**

This type of mass is typically a slow growing tumor. However, arrhythmogenic disease may be playing role and secondary to the heart base mass. EKG is indicated. There is no volume overload in this patient. Tapering of the Furosemide would be recommended. There was no evidence of volume overload or justification of Furosemide at this time. Blood pressure measurements, EKG +/- Holter monitor is warranted. The prognosis long term is guarded to poor. However, these tumors are typically slow growing.



**PATIENT**

Tonka Craig

**SPECIES**

Canine

**BREED**

American Bulldog

**SEX**

Intact male

**AGE**

9 years

**WEIGHT**

58.4 lbs

**INTERPRETED BY**

Eric Lindquist, DMV  
DABVP, Cert. IVUSS

**IMAGING  
PERFORMED BY**

Diane McFadden, RVT

**HOSPITAL NAME**

North Warren AH

**REFERRING VET**

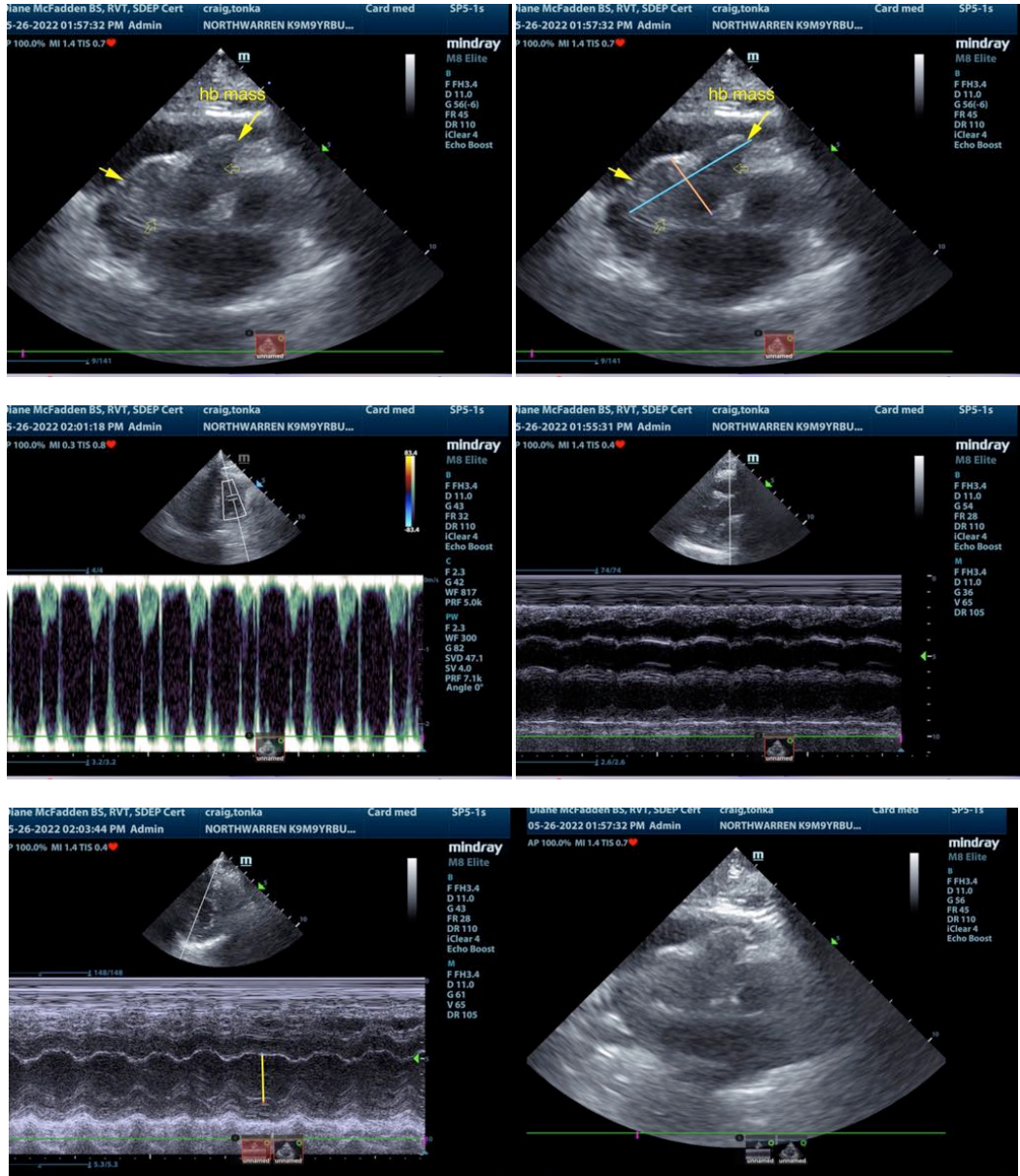
Dr. Corrado

**INVOICE**

30753

**DATE**

5/26/22



The information and recommendations provided are based on the images presented by the referring veterinarian/sonographer. No evaluation can be communicated regarding pathology that was not visible in the image/video clips provided.

Thank you for this referral. If the clinical or image interpretation does not parallel your findings or if I can be of any further assistance please contact me.

Eric Lindquist, DMV, DABVP, Cert. IVUSS, CEO of SonoPath.com  
Info@SonoPath.com