



PATIENT PRESENTING CLINICAL SIGNS

Rocky Rienzo
 History: coughing, enlarged heart on rads; on vetmedin, hydroxyzine, furosemide, TemerilP, amoxicillin

SPECIES ULTRASONOGRAPHIC EXAMINATION OF THE HEART

Canine

BREED

Bulldog Cross

SEX

Neutered male

AGE

10 years

The **echocardiogram** presented a prominent **right heart** with mild **right ventricular** hypertrophy, without significant **tricuspid** regurgitation, and normal **right atrial** size. No evidence of neoplasia was noted in the right auricle, or elsewhere in the heart. The **pulmonary artery** was uniformly prominent with mildly depressed pulmonic velocity measured on PW Doppler. No overt heartworms were noted in the main or visible deep pulmonary arteries. Yet, theoretically heartworms could be present in the deep pulmonary vasculature out of visible sonographic range. More likely, however, this prominent right heart is due to excessive intra-thoracic pressures caused by chronic respiratory disease or potentially excessive intra-thoracic fat (Pickwickian syndrome). The **left heart** demonstrated a linear **ventricular septum**. Contractility was functionally adequate demonstrated by the FS% measurement. **Mitral valve** insufficiency was noted. There was no significant **left atrial** dilation noted. The **left ventricular outflow** demonstrated normal flow patterns and velocities through the aortic valve. No evidence of tumor, pericardial or pleural effusion was noted. The visible **extra-cardiac** tissues were uniformly linear without evidence of masses, infiltrative or inflammatory mediastinal tissue. No evident arrhythmic activity was noted during the exam.

WEIGHT

44.8 lbs

INTERPRETED BY

Eric Lindquist, DMV
 DABVP, Cert. IVUSS

IMAGING PERFORMED BY

Diane McFadden, RVT

HOSPITAL NAME

North Warren AH

REFERRING VET

Dr. Corrado

CANINE CARDIAC PARAMETERS	MR VMAX (m/s)	TR VMAX (m/s)	LA/AO (Boon method)	LA/AO (Heart Base; Swe)	FS (%)	EF (%)	EPSS (cm)
NORMAL PARAMETER	4.5-5.5	<2.7	1.3	<1.3	28-40	40-100	<0.6
PATIENT	5.0		1.1	1.16			0.2
CANINE CARDIAC PARAMETERS	HR (BPM)	AV VMAX (m/s)	PV MAX (m/s)	BODY WEIGHT	LA (2D short axis Base view) (cm)	LVIDd (Avg; 2D and m-mode short axis) (cm)	LVIDs (Avg; 2D and m-mode short axis) (cm)
NORMAL PARAMETER	50-100	0.7-1.7	0.7-1.6				
PATIENT			1.2	44.8		3.1	

ULTRASONOGRAPHIC FINDINGS

Stage B1 valvular disease.

INVOICE

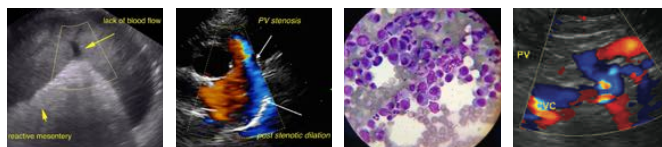
30748

DATE

526/22

INTERPRETATION OF THE FINDINGS & FURTHER RECOMMENDATIONS

The cough is non-cardiogenic in this patient. Primary respiratory protocol is warranted based on radiographs and/or CT evaluation.



PATIENT

Rocky Rienzo

SPECIES

Canine

BREED

Bulldog Cross

SEX

Neutered male

AGE

10 years

WEIGHT

44.8 lbs

INTERPRETED BY

Eric Lindquist, DMV
DABVP, Cert. IVUSS

**IMAGING
PERFORMED BY**

Diane McFadden, RVT

HOSPITAL NAME

North Warren AH

REFERRING VET

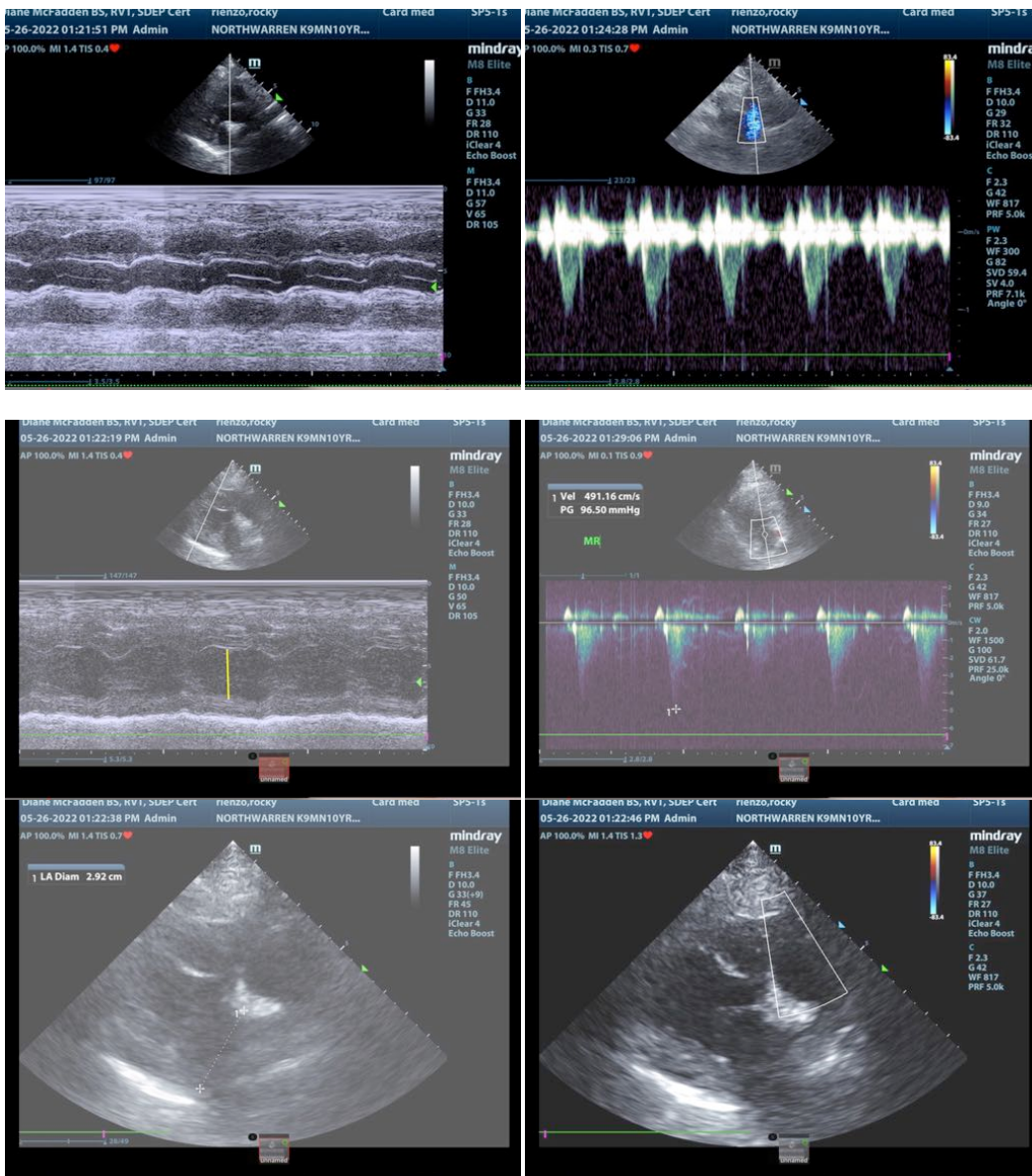
Dr. Corrado

INVOICE

30748

DATE

5/26/22



The information and recommendations provided are based on the images presented by the referring veterinarian/sonographer. No evaluation can be communicated regarding pathology that was not visible in the image/video clips provided.

Thank you for this referral. If the clinical or image interpretation does not parallel your findings or if I can be of any further assistance please contact me.

Eric Lindquist, DMV, DABVP, Cert. IVUSS, CEO of SonoPath.com
Info@SonoPath.com