


PATIENT

Finnegan Maloney

PRESENTING CLINICAL SIGNS

Shortness of breath HR 140-153, ascites (serous fluid), suspect DCM.

SPECIES

Canine

BREED

Boxer

SEX

Male

AGE

8 years

ULTRASONOGRAPHIC EXAMINATION OF THE HEART

The echocardiogram for this patient presented excessive **left atrial size** expressed in 3 different LA measurement methods.. Left atrial content was anechoic. No evidence of “smoke” or thrombotic activity was noted. The atrial septum was deviated owing to volume overload. The cranial and caudal **mitral** valve leaflets presented normal linear structure yet insufficiency was noted. The **left ventricle** demonstrated excessive volume (LVIDd measurement below). Ventricular function was subnormal expressed by the fractional shortening measurement listed below. Myocardium appeared subjectively thin typical of DCM. The **left ventricular outflow** tract demonstrated normal laminar flow and subjective structural integrity. The **right atrium** and auricle revealed normal size, structure and content. No evidence of masses was noted or chamber overload. **Tricuspid** valvular assessment demonstrated adequate linear morphology. The **right ventricle** was of normal size (1/3 diameter of LV), chordae structure, myocardial echogenicity and thickness. **Pulmonic** tract assessment revealed normal valve structure, laminar flow, and diameter (approx.1:1 pa/ao ratio). No visible **pericardial** or free pleura fluid was noted. The cranial **mediastinum and pericardial regions** were free of masses in the visible window. Hepatic vein dilation and ascites was noted.

INTERPRETED BY

 Eric Lindquist, DMV
 DABVP, Cert. IVUSS

IMAGING PERFORMED BY

 Eric Lindquist, DMV
 DABVP, Cert. IVUSS

HOSPITAL NAME

Greenwood Lakes AH

REFERRING VET

Dr. Louer

CANINE CARDIAC PARAMETERS	MR VMAX (m/s)	TR VMAX (m/s)	LA/AO (Boon method)	LA/AO (Heart Base; Swe)	FS (%)	EF (%)	EPSS (cm)
NORMAL PARAMETER	4.5-5.5	<2.7	1.3	<1.3	28-40	40-100	<0.6
PATIENT	5.0	3.5	NM		11	23	0.95
CANINE CARDIAC PARAMETERS	HR (BPM)	AV VMAX (m/s)	PV MAX (m/s)	BODY WEIGHT (kg)	LA 2D short axis Base view (cm)	LVIDd Avg; 2D and m- mode short axis (cm)	LVIDs Avg; 2D and m- mode short axis (cm)
NORMAL PARAMETER	50-100	0.7-1.7	0.7-1.6				
PATIENT		1.12	0.6		5.5	5.16	

INVOICE

30685

DATE

5/24/22

ULTRASONOGRAPHIC FINDINGS

DCM type presentation with left and right sided failure.

Hepatic vein dilation and ascites.



PATIENT

Finnegan Maloney

SPECIES

Canine

BREED

Boxer

SEX

Male

AGE

8 years

INTERPRETED BY

Eric Lindquist, DMV
DABVP, Cert. IVUS

IMAGING PERFORMED BY

Eric Lindquist, DMV
DABVP, Cert. IVUS

HOSPITAL NAME

Greenwood Lakes AH

REFERRING VET

Dr. Louer

INVOICE

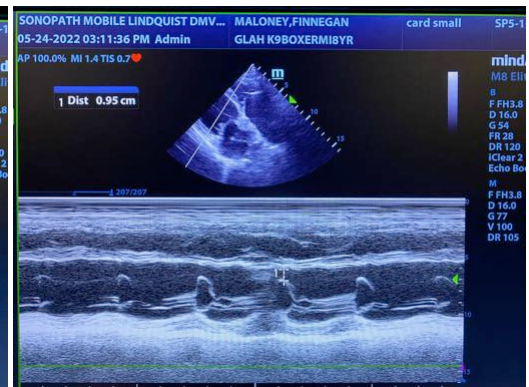
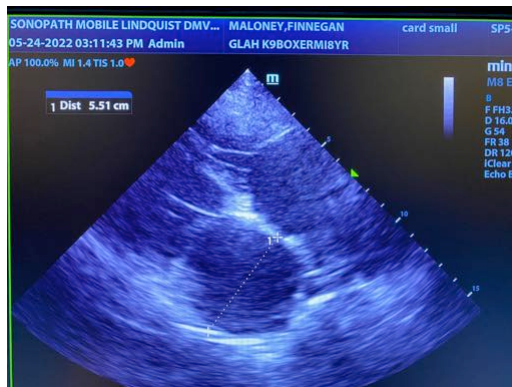
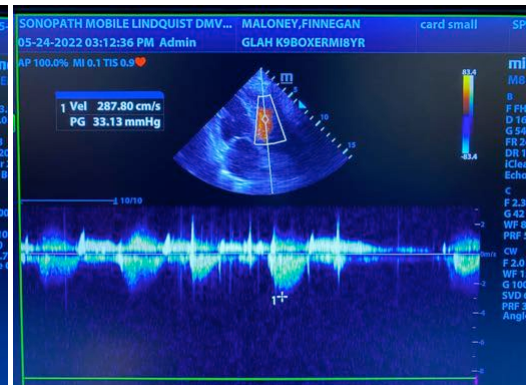
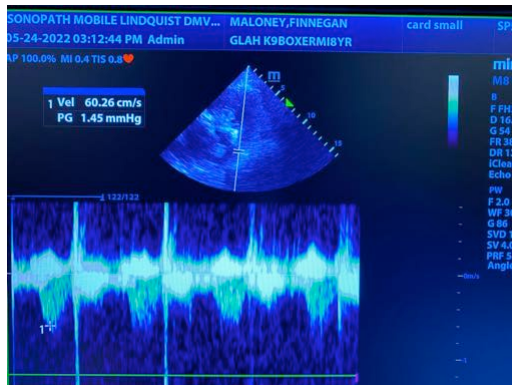
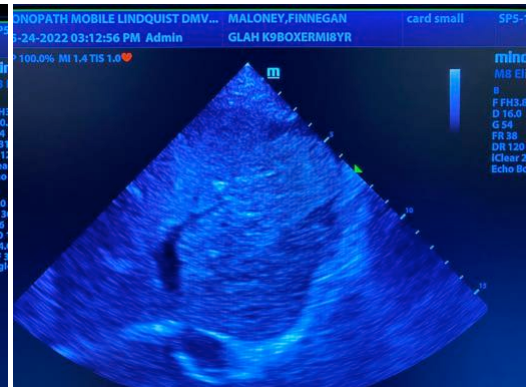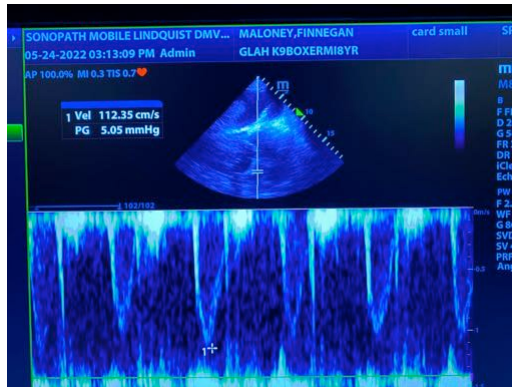
30685

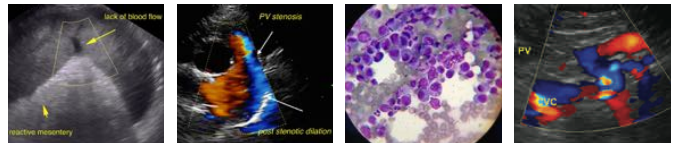
DATE

5/24/22

INTERPRETATION OF THE FINDINGS & FURTHER RECOMMENDATIONS

Underlying myocarditis taurine deficiency should be considered. Quadro therapy is warranted with Pimobendan at 0.3 mg/kg b.i.d. Ace inhibitor is recommended at 0.5 mg/kg s.i.d. progressing to b.i.d. Lasix is recommended 2-4 mg/kg b.i.d. and Spironolactone at 1-2 mg/kg. Taurine +/- magnesium supplementation may be utilized if magnesium levels are subnormal. Recheck echocardiogram is recommended in 7-10 days. This patient is at risk for sudden death.





PATIENT

Finnegan Maloney

SPECIES

Canine

BREED

Boxer

SEX

Male

AGE

8 years

INTERPRETED BY

Eric Lindquist, DMV
DABVP, Cert. IVUSS

IMAGING PERFORMED BY

Eric Lindquist, DMV
DABVP, Cert. IVUSS

HOSPITAL NAME

Greenwood Lakes AH

REFERRING VET

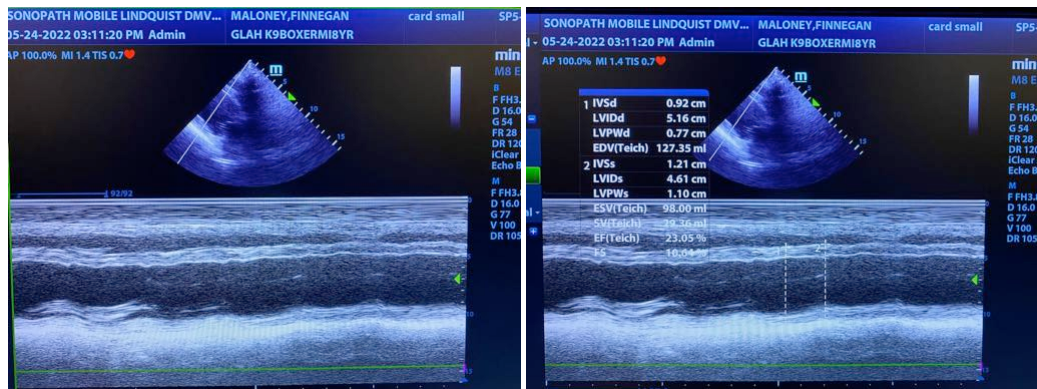
Dr. Louer

INVOICE

30685

DATE

5/24/22



The information and recommendations provided are based on the images presented by the referring veterinarian/sonographer. No evaluation can be communicated regarding pathology that was not visible in the image/video clips provided.

Thank you for this referral. If the clinical or image interpretation does not parallel your findings or if I can be of any further assistance please contact me.

Eric Lindquist, DMV, DABVP, Cert. IVUSS, CEO of SonoPath.com
Info@SonoPath.com