



PATIENT

Ella Ramunno

SPECIES

Canine

BREED

Miniature Schnauzer

SEX

Spayed female

AGE

1 ½ years

WEIGHT

12.3 lbs

INTERPRETED BY

Eric Lindquist, DMV
DABVP, Cert. IVUSS

IMAGING PERFORMED BY

Jessica Miller, RDMS

HOSPITAL NAME

Basking Ridge AH

REFERRING VET

Dr. Hollo-Rotella

INVOICE

44118

DATE

5/1/23

PRESENTING CLINICAL SIGNS

History: Hx of hydronephrosis and surgical removal 11/22. Recheck remaining kidney. No current meds.

Abnormal PE/Chem/CBC/UA Results: WNL

ULTRASONOGRAPHIC EXAMINATION OF THE ABDOMEN

Urinary System

The **urinary bladder**, trigone, and pelvic urethra presented normal thicknesses and normal tone. The ureters were not visible which is normal. No uroliths or sediment were visualized and anechoic urine was present. No evidence of inflammatory or neoplastic changes was noted. Ureteral papillae were normal.

The left kidney is normal in size and contour. Corticomedullary definition was maintained. There was no evidence of degenerative disease or hydronephrosis. The left kidney measured 4.44 cm. Blood flow to the left kidney appeared to be solid on power Doppler assessment. The region of the right renal fossa was unremarkable. There was no residual pathology.

Adrenal Glands

Both **adrenal glands** were visualized and recognized as having normal shape, size, position and echogenicity for this breed. The phrenic vasculature, glandular echogenicity and detail were unremarkable. Capsule, cortex, and medullary definition were normal for this age patient. The left adrenal gland measured 1.83 x 0.45 cm at the caudal pole and 0.3 cm at the cranial pole. The right adrenal gland measured 1.8 x 0.93 cm at the cranial pole and 0.47 cm at the caudal pole.

Spleen

The **spleen** presented a smooth homogeneous parenchyma hyperechoic to liver and renal cortical parenchyma. The capsule was smooth without noticeable expansion or deviation from within the spleen or adjacent pathology. The splenic vasculature demonstrated normal volume without signs of congestion or thrombosis. No sonographic evidence of acute or chronic inflammatory, neoplastic, or infarctual changes was noted.

Liver

The **liver** images submitted revealed subjectively normal liver size, contour, and structure. Parenchymal echogenicity was naturally coarse and hypoechoic to the spleen. Vascular and biliary tracts were of normal volume with no evidence of congestion. The gallbladder presented acceptably thin walls with primarily anechoic content. The cystic and common bile ducts were normal. No pathological hepatic lymphadenopathy was evident. No overt structural evidence of inflammatory, infiltrative or regenerative pathology was evident.



PATIENT

Gastrointestinal

Ella Ramunno

Examination of the **gastrointestinal tract** revealed a stomach and intestine free of stasis, of normal wall thickness, acceptable curvilinear mural detail, and peristaltic activity. Small and large intestine demonstrated normal luminal chyme and stool consistency respectively. No obstructive or overt infiltrative disease was noted. No associated abnormal lymphatic activity was noted.

SPECIES

Canine

BREED

Pancreas

Miniature Schnauzer

The base and limbs of the **pancreas** were observed to be largely isoechoic to surrounding omental fat. Pancreatic duct and capsular contour were acceptably normal and parenchyma respected normal curvilinear patterns. No overt evidence of active inflammatory or neoplastic disease was noted.

SEX

Spayed female

ULTRASONOGRAPHIC FINDINGS

AGE

1 ½ years

Normal abdomen and left kidney.

Normal right renal fossa.

WEIGHT

12.3 lbs

INTERPRETATION OF THE FINDINGS & FURTHER RECOMMENDATIONS

There was no residual pathology. Solid left renal structure was noted.

INTERPRETED BY

Eric Lindquist, DMV
DABVP, Cert. IVUSS

IMAGING PERFORMED BY

Jessica Miller, RDMS

HOSPITAL NAME

Basking Ridge AH

REFERRING VET

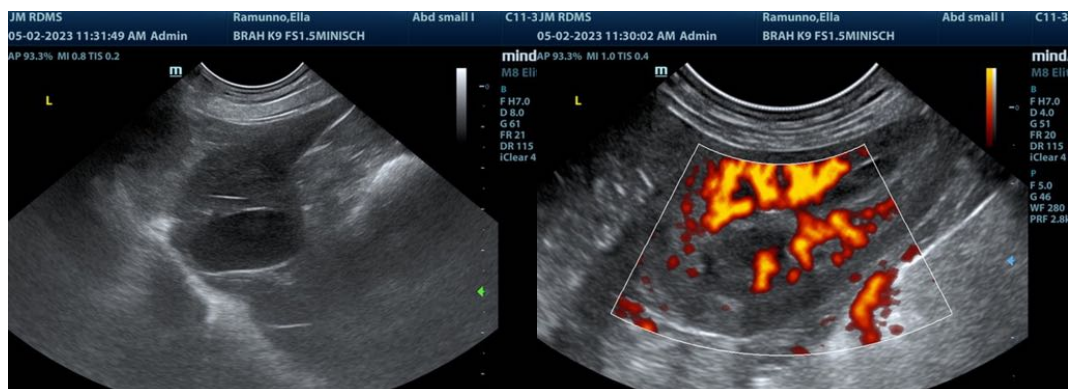
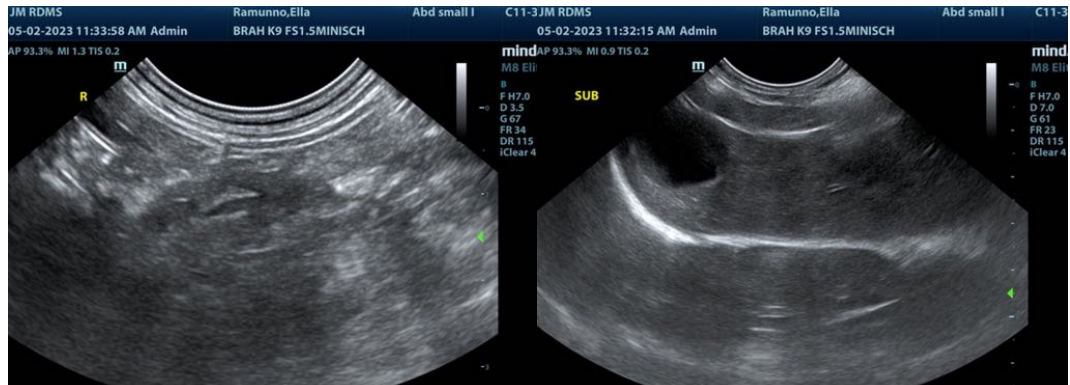
Dr. Hollo-Rotella

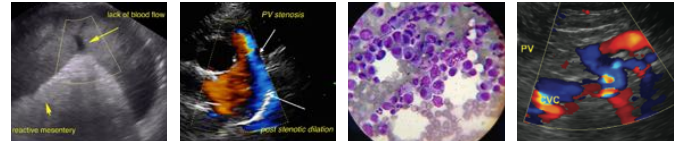
INVOICE

44118

DATE

5/1/23





PATIENT

Ella Ramunno

SPECIES

Canine

BREED

Miniature Schnauzer

SEX

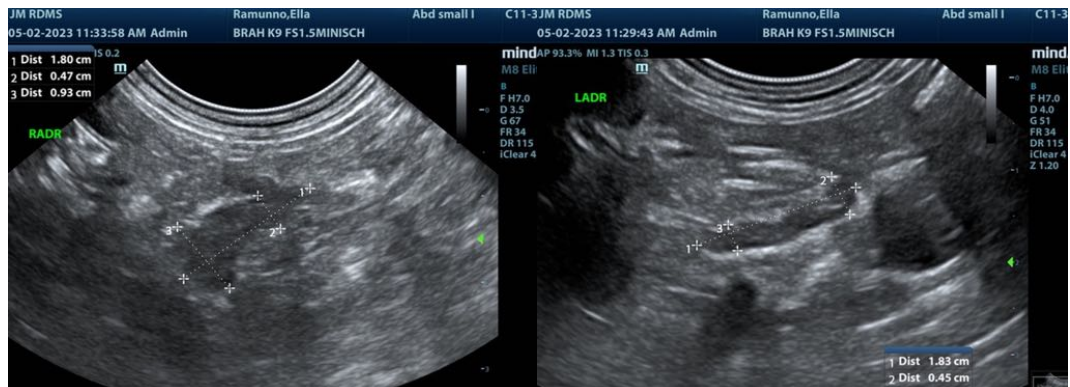
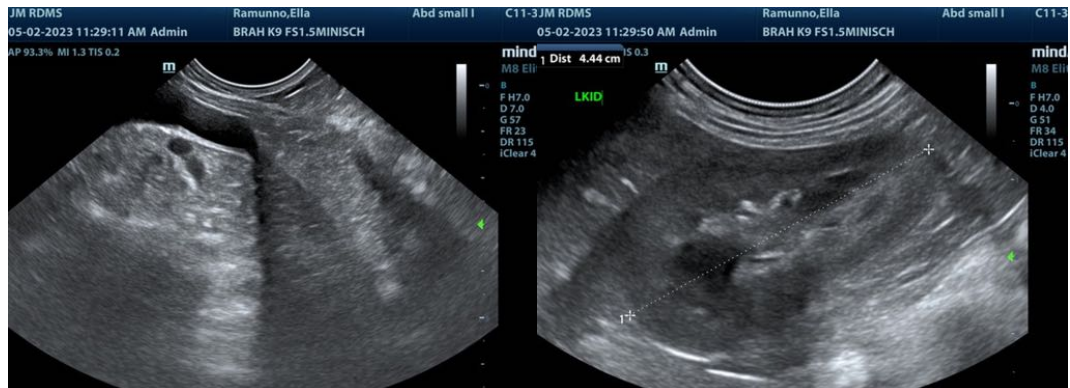
Spayed female

AGE

1 ½ years

WEIGHT

12.3 lbs



INTERPRETED BY

Eric Lindquist, DMV
DABVP, Cert. IVUSS

IMAGING PERFORMED BY

Jessica Miller, RDMS

HOSPITAL NAME

Basking Ridge AH

REFERRING VET

Dr. Hollo-Rotella

INVOICE

44118

DATE

5/1/23

The information and recommendations provided are based on the images presented by the referring veterinarian/sonographer. No evaluation can be communicated regarding pathology that was not visible in the image/video clips provided.

Thank you for this referral. If the clinical or image interpretation does not parallel your findings or if I can be of any further assistance please contact me.

Eric Lindquist, DMV, DABVP, Cert. IVUSS, CEO of SonoPath.com
Info@SonoPath.com