



PATIENT

Buka Redstone

SPECIES

Canine

BREED

Chow Chow

SEX

Neutered male

AGE

9 years

WEIGHT

55 lbs

INTERPRETED BY

Eric Lindquist, DMV
DABVP, Cert. IVUSS

IMAGING PERFORMED BY

Valeryia Shumskaya

HOSPITAL NAME

Hillsdale AH

REFERRING VET

Dr. Fischer

INVOICE

44116

DATE

5/2/23

PRESENTING CLINICAL SIGNS

History: Intermittent unresolving pain over weekend of 4/28-4/30/23. went to veg. rads fairly unremarkable. Prev ultrasound from oradell

Abnormal PE/Chem/CBC/UA Results: Alk Phosphatase 354, GGTP 35, RBC 10.5, Hemoglobin 20.4, HCT 62

ULTRASONOGRAPHIC EXAMINATION OF THE ABDOMEN

Urinary System

The **bladder** in this patient was mildly thickened with slight echogenic mural changes. No calculi or masses were noted. Slight micropolypoid changes were noted. This is a frequent finding in older animals and may be linked to a history of chronic urinary tract infection or active urinary tract infection. Urinalysis would be recommended with culture if any evidence of inflammatory sediment is present. The region of the trigone and visible pelvic urethra were normal.

The **kidneys** revealed largely normal size and structure, corticomedullary definition and ratio (cortex 1/3 of medulla) were essentially maintained with some age-related loss of curvilinear patterns regarding the capsule and C/M junction. The cortices presented largely uniform texture with some increased echogenicity expected for his age patient. Medullary structure differed distinctly from that of the cortex and no evidence of pelvic dilation was present. The left kidney measured 4.83 cm.

Adrenal Glands

Both **adrenal glands** were visualized and recognized as having normal shape, size, position and echogenicity for this breed. The phrenic vasculature, glandular echogenicity and detail were unremarkable. Capsule, cortex, and medullary definition were normal for this age patient. The right adrenal gland measured 2.13 x 0.91 cm at the cranial pole and 0.73 cm at the caudal pole. The left adrenal gland measured 1.28 x 0.49 cm at the cranial pole and 0.34 cm at the caudal pole.

Spleen

The **spleen** presented a smooth homogeneous parenchyma hyperechoic to liver and renal cortical parenchyma. The capsule was smooth without noticeable expansion or deviation from within the spleen or adjacent pathology. The splenic vasculature demonstrated normal volume without signs of congestion or thrombosis. No sonographic evidence of acute or chronic inflammatory, neoplastic, or infarctual changes was noted.

Liver

The **liver** revealed left-sided mixed echogenic mass that measured 4.6 cm. Left-sided hepatomegaly was present deviating the stomach slightly caudally. Minor heterogenous hepatic changes were noted on the right liver. The gallbladder and common bile duct were unremarkable.



PATIENT

Gastrointestinal

Buka Redstone

The **stomach** was overdistended with chyme and kibble. This is consistent with post prandial presentation. The pylorus was patent with no evidence of foreign bodies despite the full stomach. The small intestines and colon were unremarkable.

SPECIES

Canine

Pancreas

BREED

Chow Chow

The base and limbs of the **pancreas** were observed to be largely isoechoic to surrounding omental fat. Pancreatic duct and capsular contour were acceptably normal and parenchyma respected normal curvilinear patterns. No overt evidence of active inflammatory or neoplastic disease was noted.

SEX

Neutered male

ULTRASONOGRAPHIC FINDINGS

Left sided liver mass, occupies the majority of the left liver to the level of the diaphragm. Carcinoma versus hepatoma.

AGE

9 years

Age related renal changes.

Full stomach, possible delayed outflow depending on when the patient ate prior to the sonogram.

WEIGHT

55 lbs

INTERPRETATION OF THE FINDINGS & FURTHER RECOMMENDATIONS

CT is warranted for surgical planning. Ultrasound-guided FNA can be considered for further definition. Subjectively the liver mass appears to be low-grade, yet further definition by FNA is indicated.

INTERPRETED BY

Eric Lindquist, DMV
DABVP, Cert. IVUSS

ABOUT SONOPATH CT SERVICES:

SonoPath CT Services are offered at the SonoPath Imaging and Veterinary Education Center, 141 Main St (rt 206), Andover, New Jersey, a 20-minute drive west on route 80/206 North from the route 80/287 interchange/Parsippany, New Jersey. More information can be found at <https://sonopath.com/resources/sonopaths-teleconsultation-services-and-sdep-certification/sonopath-ct-services>

IMAGING PERFORMED BY

Valeryia Shumskaya

HOSPITAL NAME

Hillsdale AH

REFERRING VET

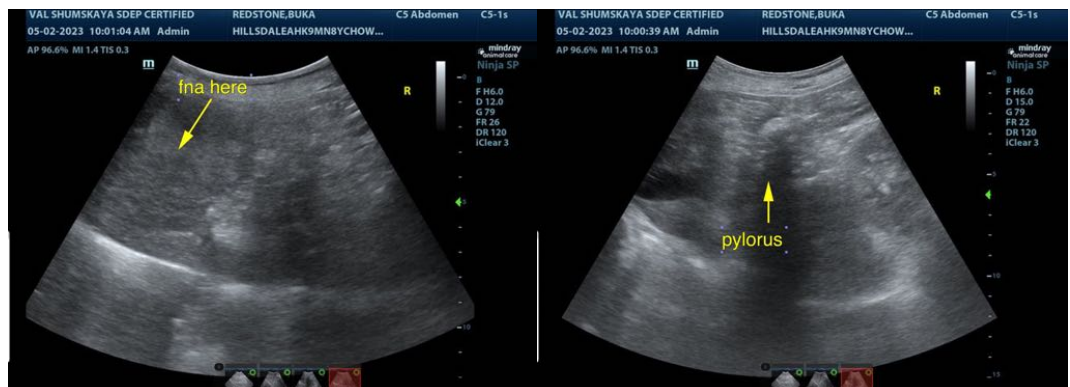
Dr. Fischer

INVOICE

44116

DATE

5/2/23





PATIENT

Buka Redstone

SPECIES

Canine

BREED

Chow Chow

SEX

Neutered male

AGE

9 years

WEIGHT

55 lbs

INTERPRETED BY

Eric Lindquist, DMV
DABVP, Cert. IVUSS

IMAGING PERFORMED BY

Valeryia Shumskaya

HOSPITAL NAME

Hillsdale AH

REFERRING VET

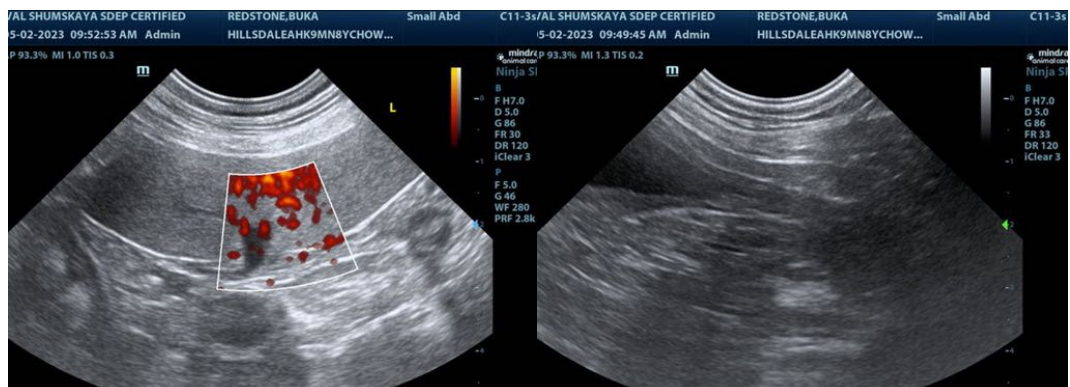
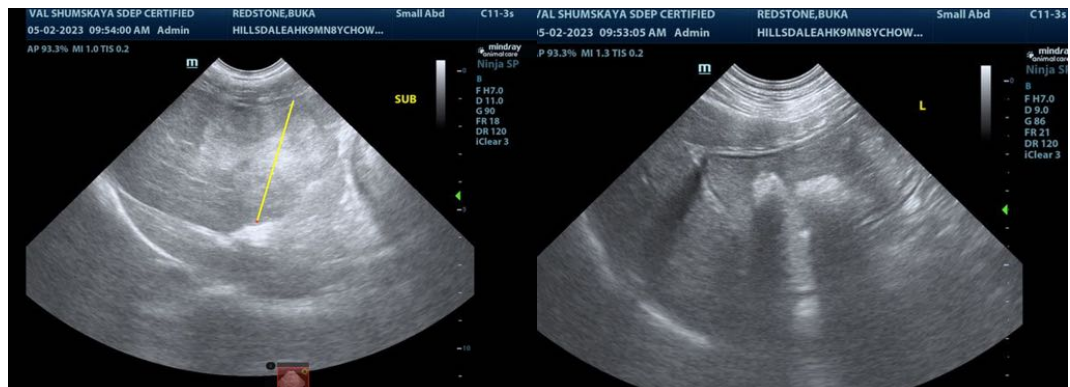
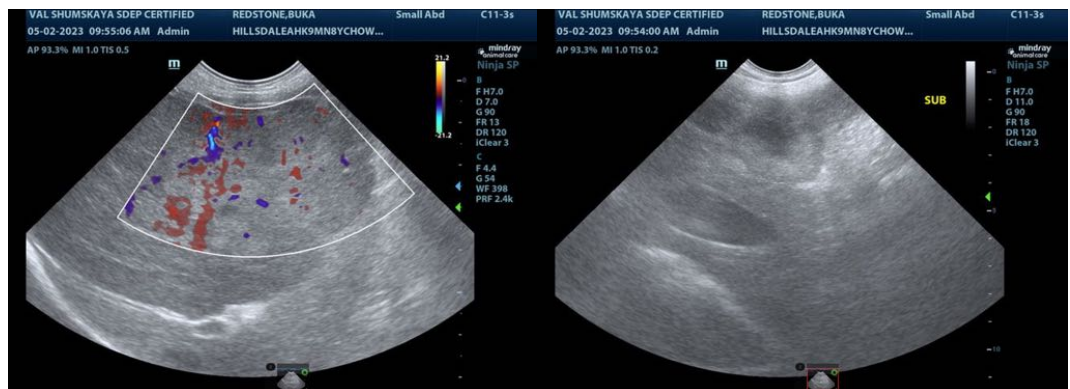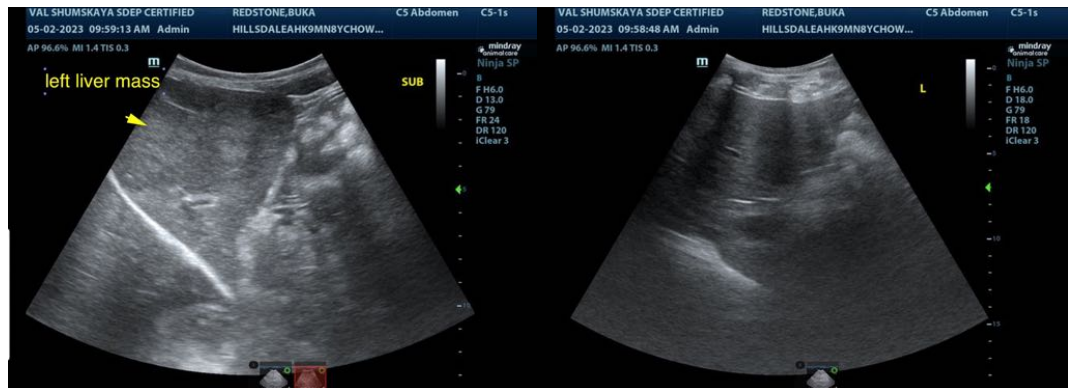
Dr. Fischer

INVOICE

44116

DATE

5/2/23





PATIENT

Buka Redstone

SPECIES

Canine

BREED

Chow Chow

SEX

Neutered male

AGE

9 years

WEIGHT

55 lbs

INTERPRETED BY

Eric Lindquist, DMV
DABVP, Cert. IVUSS

IMAGING PERFORMED BY

Valeryia Shumskaya

HOSPITAL NAME

Hillsdale AH

REFERRING VET

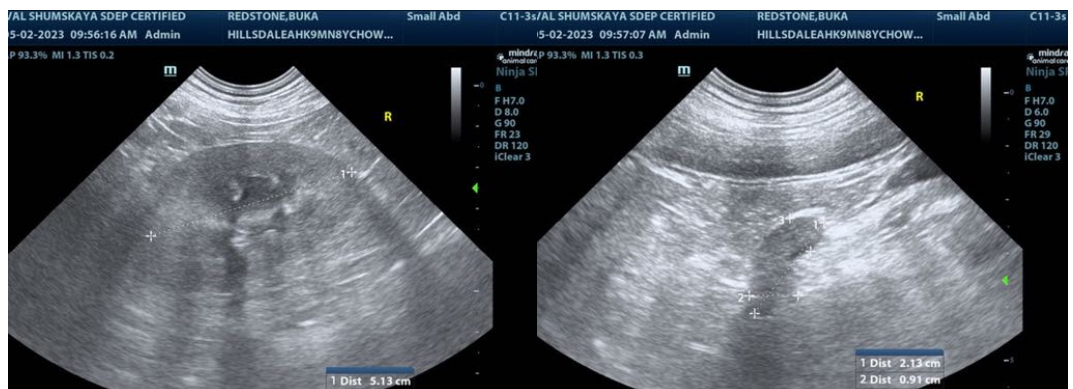
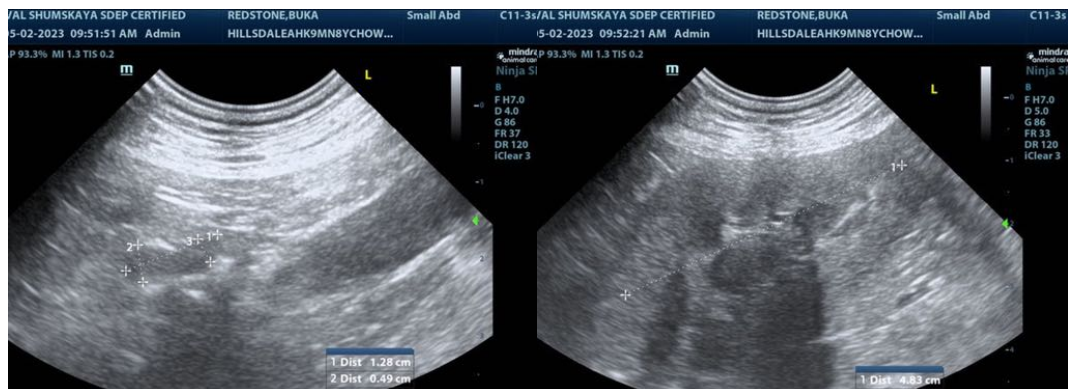
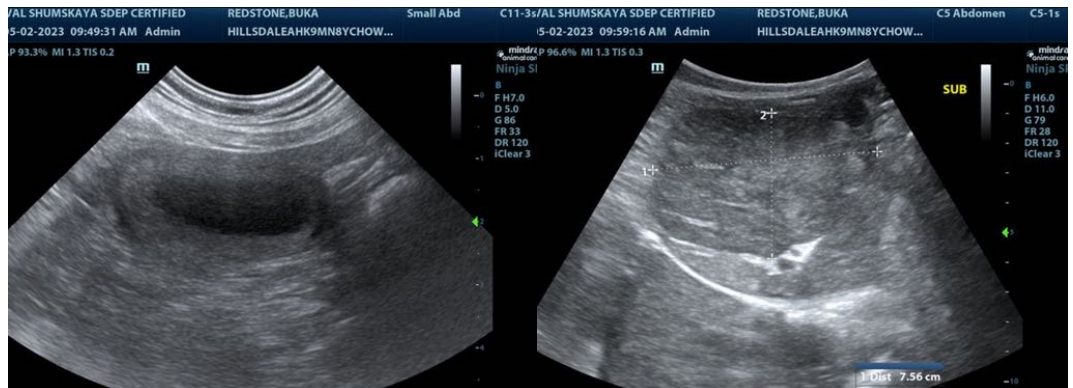
Dr. Fischer

INVOICE

44116

DATE

5/2/23



The information and recommendations provided are based on the images presented by the referring veterinarian/sonographer. No evaluation can be communicated regarding pathology that was not visible in the image/video clips provided.

Thank you for this referral. If the clinical or image interpretation does not parallel your findings or if I can be of any further assistance please contact me.

Eric Lindquist, DMV, DABVP, Cert. IVUSS
info@SonoPath.com