



PATIENT

Bailey Quagliana

SPECIES

Canine

BREED

Golden Doodle

SEX

Spayed female

AGE

13 years

WEIGHT

55.5 lbs

PRESENTING CLINICAL SIGNS

History: F.U.O, weight loss, muscle weakness, trouble breathing

Abnormal PE/Chem/CBC/UA Results: Hematocrit 37, hemoglobin 13, reticulocyte hemo 24.4, Eos 65, Platelets 64, ALB 2.6, Glob 4.1, alb:glob ratio 0.6, Chol 350, lyme 4dx neg

ULTRASONOGRAPHIC EXAMINATION OF THE HEART

The echocardiogram in this patient demonstrated normal **left atrial** size based on 3 different LA measurement methods. Chamber volumes and echogenicity were normal. The cranial and caudal **mitral** valve leaflets presented vegetative thickening consistent with endocardiosis. Doppler indicated measurable insufficiency. The **left ventricle** presented thicknesses with linear contour and was not dilated nor restricted. The **myocardium** presented normal echogenicity without subjective evidence of significant fibrotic or ischemic disease. **Contractility** of the ventricular walls was adequate and in normal range for this patient evidenced by the fractional shortening measurement and subjective evaluation of the different regions of the myocardium. Aortic insufficiency was noted at 5 m/sec. The **right atrium** and auricle revealed normal size, structure and content. No evidence of masses was noted or chamber overload. **Tricuspid** valvular assessment demonstrated adequate linear morphology. The **right ventricle** was of normal size (1/3 diameter of LV), chordae structure, myocardial echogenicity and thickness. **Pulmonic** tract assessment revealed normal valve structure, laminar flow, and diameter (approx. 1:1 pa/ao ratio). No visible **pericardial** or free pleura fluid was noted. No echographically detectable evidence of infiltrative disease was visible. The cranial **mediastinum and pericardial regions** were free of masses in the visible window.

INTERPRETED BY

Eric Lindquist, DMV
DABVP, Cert. IVUSS

IMAGING PERFORMED BY

Valeryia Shumskaya

HOSPITAL NAME

North Jersey AH

REFERRING VET

Dr. Riedel

INVOICE

44076

DATE

5/1/23

CANINE CARDIAC PARAMETERS	MR VMAX (m/s)	TR VMAX (m/s)	LA/AO (Boon method)	LA/AO (Heart Base;)	FS (%)	EF (%)	EPSS (cm)
NORMAL PARAMETER	4.5-5.5	<2.7	1.3	<1.6	28-40	40-100	<0.6
PATIENT	5.28		1.0	1.0	27	56	NM
CANINE CARDIAC PARAMETERS	HR (BPM)	AV VMAX (m/s)	PV MAX (m/s)	BODY WEIGHT	LA 2D short axis Base view (cm)	LVIDd Avg; 2D and m- mode short axis (cm)	LVIDs Avg; 2D and m- mode short axis (cm)
NORMAL PARAMETER	50-100	0.7-1.7	0.7-1.6	BELOW	BELOW	BELOW	BELOW
PATIENT	147	1.8		55.5 lbs	3.07	2.4	



PATIENT

Bailey Quagliana

SPECIES

Canine

BREED

Golden Doodle

SEX

Spayed female

AGE

13 years

WEIGHT

55.5 lbs

INTERPRETED BY

Eric Lindquist, DMV
DABVP, Cert. IVUSS

IMAGING PERFORMED BY

Valeryia Shumskaya

HOSPITAL NAME

North Jersey AH

REFERRING VET

Dr. Riedel

INVOICE

44076

DATE

5/1/23

ULTRASONOGRAPHIC EXAMINATION OF THE ABDOMEN

Urinary System

The **urinary bladder**, trigone, and pelvic urethra presented normal thicknesses and normal tone. The ureters were not visible which is normal. No uroliths or sediment were visualized and anechoic urine was present. No evidence of inflammatory or neoplastic changes was noted. Ureteral papillae were normal.

The **kidneys** revealed largely normal size and structure, corticomedullary definition and ratio (cortex 1/3 of medulla) were essentially maintained with some age-related loss of curvilinear patterns regarding the capsule and C/M junction. The cortices presented largely uniform texture with some increased echogenicity expected for his age patient. Medullary structure differed distinctly from that of the cortex and no evidence of pelvic dilation was present. The left kidney measured 4.93 cm. The right kidney measured 6.75 cm.

Adrenal Glands

Both **adrenal glands** were visualized and recognized as having normal shape, size, position and echogenicity for this breed. The phrenic vasculature, glandular echogenicity and detail were unremarkable. Capsule, cortex, and medullary definition were normal for this age patient. The right adrenal gland measured 2.0 x 0.97 cm at the cranial pole and 0.55 cm at the caudal pole. The left adrenal gland measured 1.8 x 0.56 cm at the cranial pole and 0.53 cm at the caudal pole.

Spleen

The **spleen** in this patient was mildly enlarged with uniform parenchyma and was folded upon itself with uniform parenchyma. This is a positional variant and is not pathological. There was no evidence of significant disease.

Liver

The **liver** was uniformly swollen with minor, excessive gallbladder debris and over distension with dependent and suspended bile without evidence of overt mucocele formation. However, excessive sludge was present. The liver presented coarse architecture with mildly increased portal markings and subtle, mixed echogenic changes. This is consistent with vacuolar hepatopathy and some level of remodeling and history of inflammatory component. There was no overt suspicion of neoplasia.

Gastrointestinal

Examination of the **gastrointestinal tract** revealed a stomach and intestine free of stasis, of normal wall thickness, acceptable curvilinear mural detail, and peristaltic activity. Small and large intestine demonstrated normal luminal chyme and stool consistency respectively. No obstructive or overt infiltrative disease was noted. No associated abnormal lymphatic activity was noted.



PATIENT

Pancreas

Bailey Quagliana

The base and limbs of the **pancreas** were observed to be largely isoechoic to surrounding omental fat. Pancreatic duct and capsular contour were acceptably normal and parenchyma respected normal curvilinear patterns. No overt evidence of active inflammatory or neoplastic disease was noted.

SPECIES

Canine

Free Abdomen

BREED

Golden Doodle

Diffuse, alveolar shower curtain lung pattern was noted.

SEX

Spayed female

ULTRASONOGRAPHIC FINDINGS

Mitral and aortic insufficiency, compensated, possible underlying hypertension.

AGE

13 years

Unremarkable abdomen.

WEIGHT

55.5 lbs

INTERPRETATION OF THE FINDINGS & FURTHER RECOMMENDATIONS

Blood pressure measurements are recommended. Radiographs are warranted if not already performed. There is no evidence of cardiogenic disease noted causing any clinical issues. However, systemic hypertension should be ruled out.

There was no evidence of primary disease. I recommend focusing on thoracic presentation in this patient. Chest radiographs, blood pressure measurements +/- chest CT are all indicated. Thromboembolic disease, pneumonitis, and thoracic neoplasia are all potentials in this patient.

INTERPRETED BY

Eric Lindquist, DMV
DABVP, Cert. IVUSS

ABOUT SONOPATH CT SERVICES:

SonoPath CT Services are offered at the SonoPath Imaging and Veterinary Education Center, 141 Main St (rt 206), Andover, New Jersey, a 20-minute drive west on route 80/206 North from the route 80/287 interchange/Parsippany, New Jersey. More information can be found at

<https://sonopath.com/resources/sonopath-teleconsultation-services-and-sdep-certification/sonopath-ct-services>

IMAGING PERFORMED BY

Valeryia Shumskaya

HOSPITAL NAME

North Jersey AH

REFERRING VET

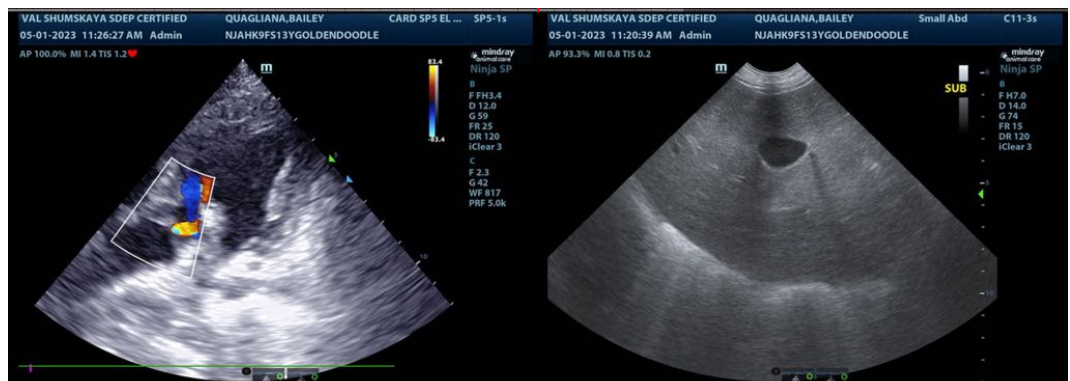
Dr. Riedel

INVOICE

44076

DATE

5/1/23





PATIENT

Bailey Quagliana

SPECIES

Canine

BREED

Golden Doodle

SEX

Spayed female

AGE

13 years

WEIGHT

55.5 lbs

INTERPRETED BY

Eric Lindquist, DMV
DABVP, Cert. IVUSS

IMAGING PERFORMED BY

Valeryia Shumskaya

HOSPITAL NAME

North Jersey AH

REFERRING VET

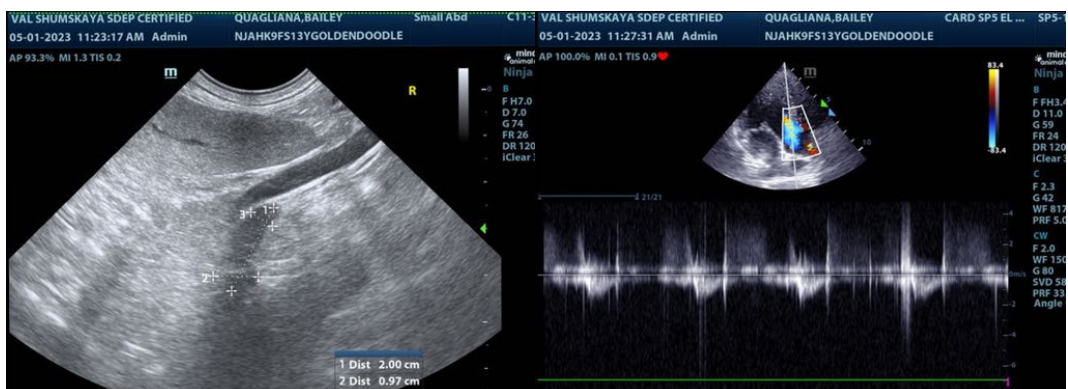
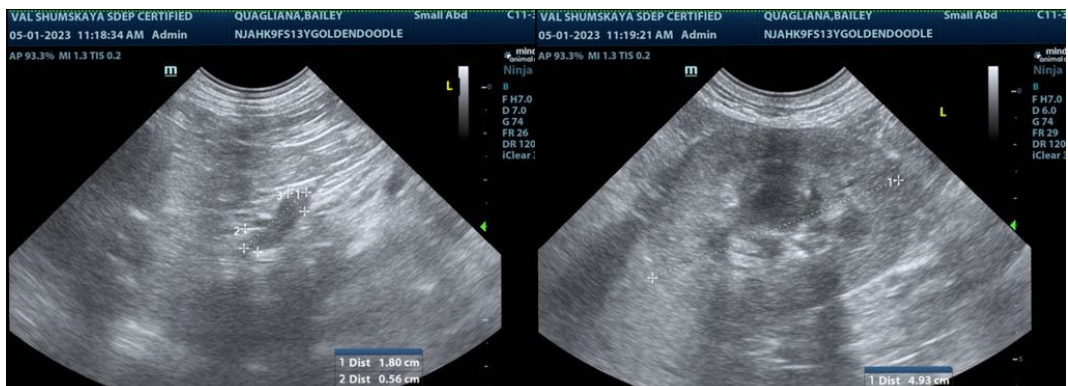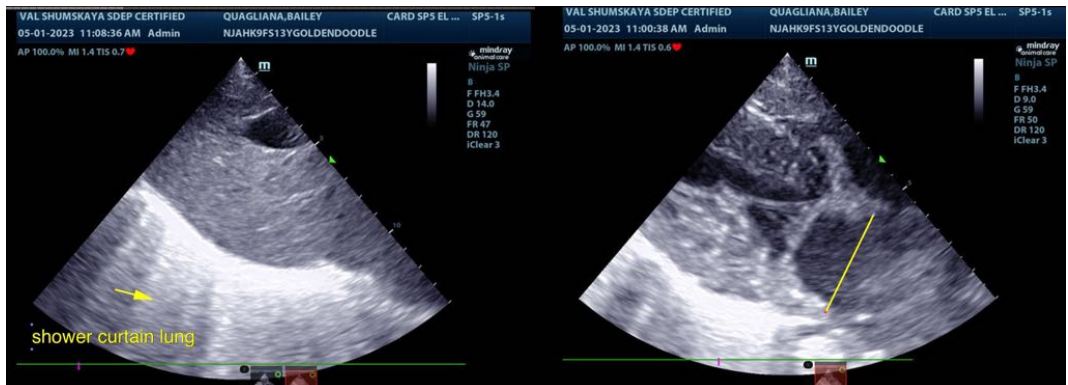
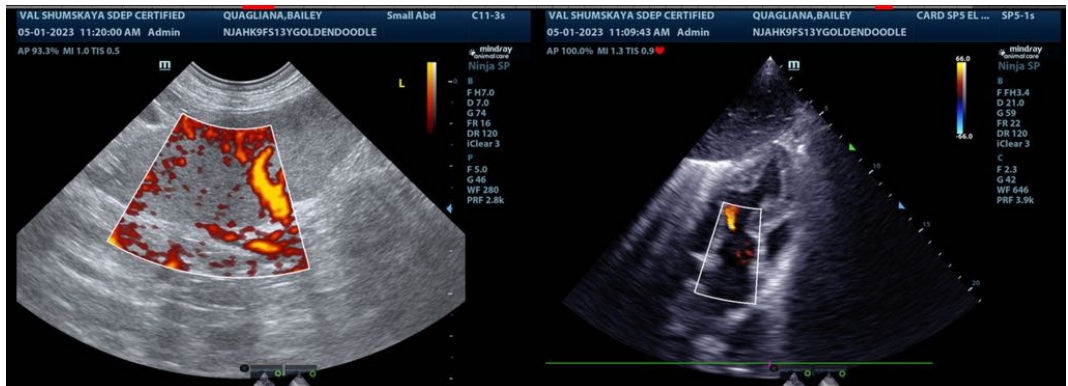
Dr. Riedel

INVOICE

44076

DATE

5/1/23





PATIENT

Bailey Quagliana

SPECIES

Canine

BREED

Golden Doodle

SEX

Spayed female

AGE

13 years

WEIGHT

55.5 lbs

INTERPRETED BY

Eric Lindquist, DMV
DABVP, Cert. IVUSS

IMAGING PERFORMED BY

Valeryia Shumskaya

HOSPITAL NAME

North Jersey AH

REFERRING VET

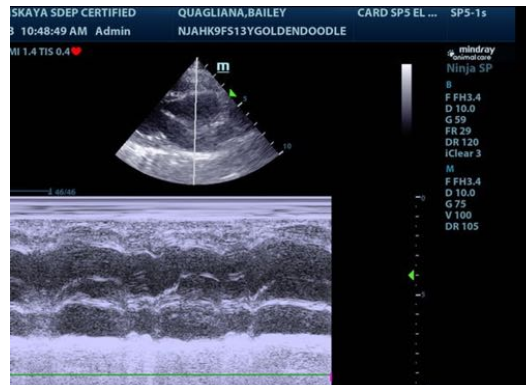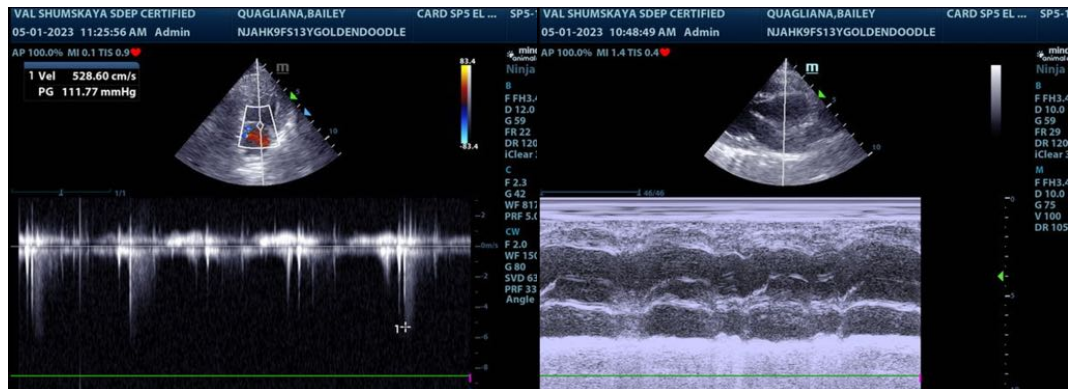
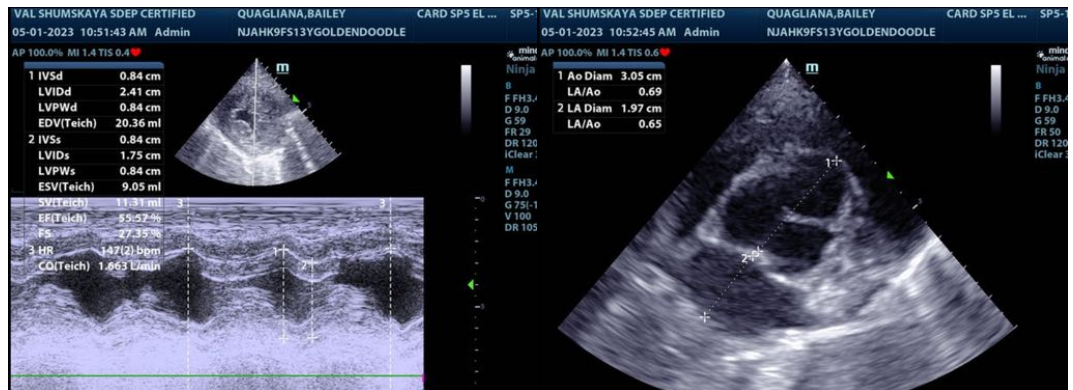Dr. Riedel

INVOICE

44076

DATE

5/1/23



The information and recommendations provided are based on the images presented by the referring veterinarian/sonographer. No evaluation can be communicated regarding pathology that was not visible in the image/video clips provided.

Thank you for this referral. If the clinical or image interpretation does not parallel your findings or if I can be of any further assistance please contact me.

Eric Lindquist, DMV, DABVP, Cert. IVUSS
info@SonoPath.com