



PATIENT PRESENTING CLINICAL SIGNS

Mia Visakay

SPECIES

Canine

History: distended abdomen; sometime in the past 2 days may have ingested up to 8# of cat litter and/or half of the insides of a pillow. vomited last night; anorexic; drinking a lot. No diarrhea. On proin, dasaquin, fluoxetine
Abnormal PE/Chem/CBC/UA Results: n/a

BREED

Pit Bull

SEX

Spayed female

ULTRASONOGRAPHIC EXAMINATION OF THE ABDOMEN
Urinary System

The **urinary bladder**, trigone, and pelvic urethra presented normal thicknesses and normal tone. The ureters were not visible which is normal. No uroliths or sediment were visualized and anechoic urine was present. No evidence of inflammatory or neoplastic changes was noted. Ureteral papillae were normal.

AGE

9 years

The **kidneys** revealed normal size and structure, corticomedullary definition and ratio for this age. The cortices presented largely uniform texture with normal echogenic relationship to liver and spleen. Medullary structure differed distinctly from the cortex and no evidence of pelvic dilation was present. The capsules were acceptably uniform without significant irregularities. The left kidney measured 6.76 cm. Anechoic cyst was noted in the medial cortex of the right kidney and measured 1.65 cm.

WEIGHT

58.1 lbs

Adrenal Glands

Both **adrenal glands** were visualized and recognized as having normal shape, size, position and echogenicity for this breed. The phrenic vasculature, glandular echogenicity and detail were unremarkable. Capsule, cortex, and medullary definition were normal for this age patient. The left adrenal gland measured 2.0 x 0.43 cm at the caudal pole and 0.32 cm at the cranial pole. The right adrenal gland measured 2.24 x 1.9 cm at the cranial pole and 0.6 cm at the caudal pole.

INTERPRETED BY

Eric Lindquist, DMV
DABVP, Cert. IVUSS

IMAGING PERFORMED BY

Diane McFadden, RVT

Spleen

The **spleen** presented a smooth homogeneous parenchyma hyperechoic to liver and renal cortical parenchyma. The capsule was smooth without noticeable expansion or deviation from within the spleen or adjacent pathology. The splenic vasculature demonstrated normal volume without signs of congestion or thrombosis. No sonographic evidence of acute or chronic inflammatory, neoplastic, or infarctual changes was noted.

HOSPITAL NAME

Long Valley AH

REFERRING VET

Dr. Welch

INVOICE

43991

DATE

4/25/23

Liver

The **liver** images submitted revealed subjectively normal liver size, contour, and structure. Parenchymal echogenicity was naturally coarse and hypoechoic to the spleen. Vascular and biliary tracts were of normal volume with no evidence of congestion. The gallbladder presented acceptably thin walls with primarily anechoic content. The cystic and common bile ducts were normal. No pathological hepatic lymphadenopathy was evident. No overt structural evidence of inflammatory, infiltrative or regenerative pathology was evident.



PATIENT *Gastrointestinal*

Mia Visakay

The **stomach** was over distended with progressively shadowing material. This is consistent with stuffing material or similar assuming that the patient was n.p.o. at the time of sonogram. Some transit of chyme is occurring. The small intestines and colon were unremarkable.

SPECIES

Canine

Pancreas

BREED

Pit Bull

The base and limbs of the **pancreas** were observed to be largely isoechoic to surrounding omental fat. Pancreatic duct and capsular contour were acceptably normal and parenchyma respected normal curvilinear patterns. No overt evidence of active inflammatory or neoplastic disease was noted.

SEX

Spayed female

Free Abdomen

A trace amount of free fluid was noted adjacent to the spleen.

AGE

9 years

ULTRASONOGRAPHIC FINDINGS

Full stomach, consistent with stuffing material.

WEIGHT

58.1 lbs

Trace amount of free fluid adjacent to the spleen.

Otherwise, benign abdomen.

INTERPRETED BY

Eric Lindquist, DMV
DABVP, Cert. IVUSS

INTERPRETATION OF THE FINDINGS & FURTHER RECOMMENDATIONS

Assuming that the patient was not post prandial then gastrotomy is indicated. However, a rapid sonogram of the stomach should be performed just prior to surgery to ensure that the material is persistently present. The trace amount of free fluid adjacent to the spleen is likely owing to splenic congestion secondary to gastric over distension.

IMAGING PERFORMED BY

Diane McFadden, RVT

HOSPITAL NAME

Long Valley AH

REFERRING VET

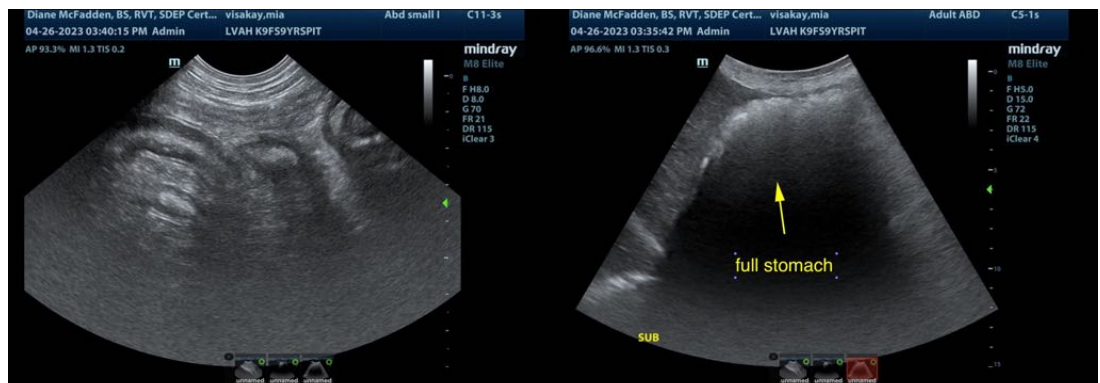
Dr. Welch

INVOICE

43991

DATE

4/25/23





PATIENT

Mia Visakay

SPECIES

Canine

BREED

Pit Bull

SEX

Spayed female

AGE

9 years

WEIGHT

58.1 lbs

INTERPRETED BY

Eric Lindquist, DMV
DABVP, Cert. IVUSS

IMAGING PERFORMED BY

Diane McFadden, RVT

HOSPITAL NAME

Long Valley AH

REFERRING VET

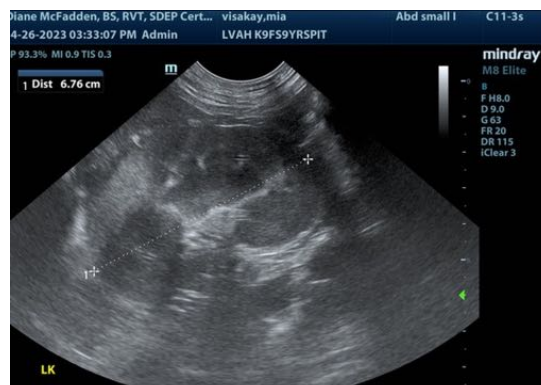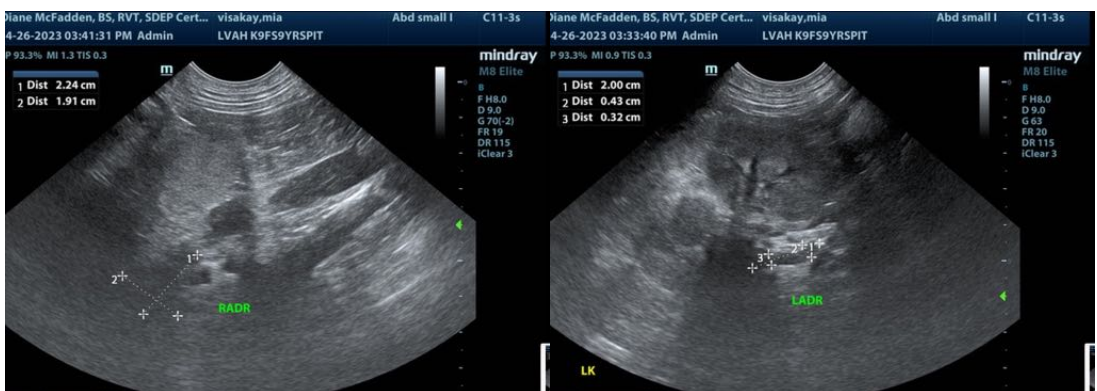
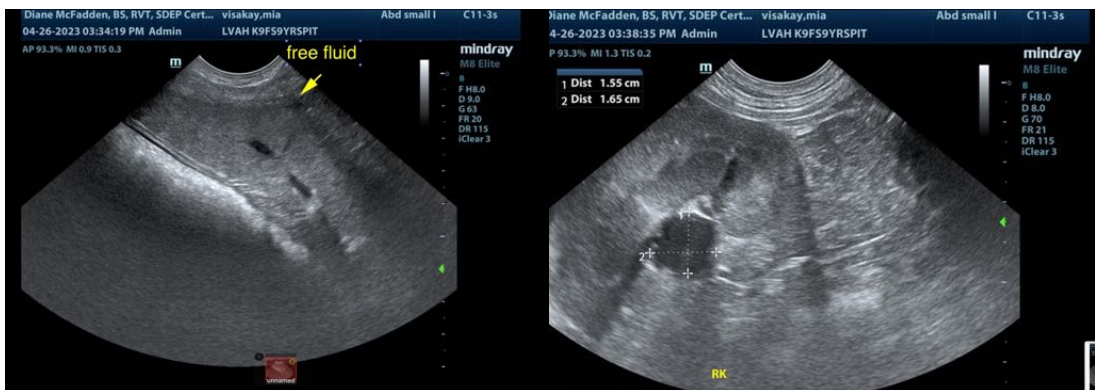
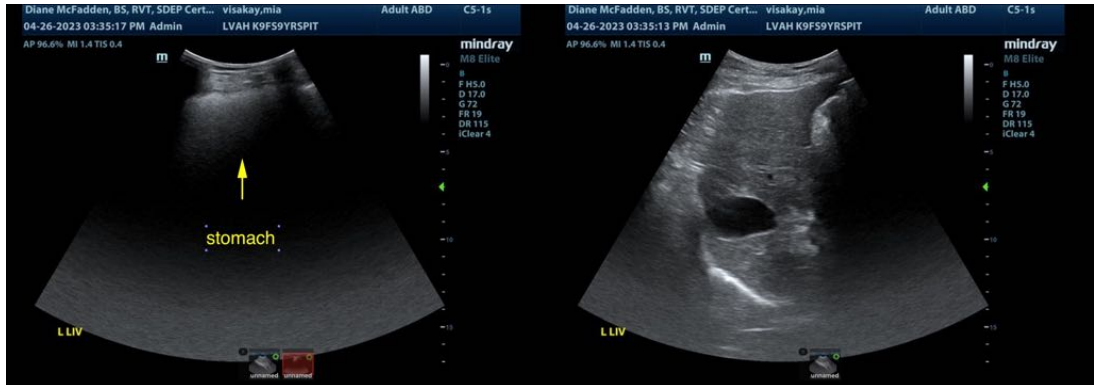Dr. Welch

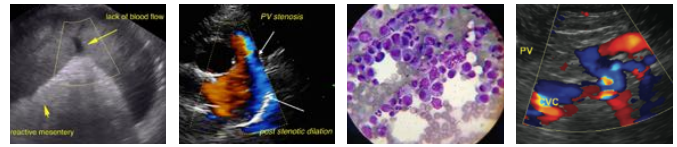
INVOICE

43991

DATE

4/25/23





PATIENT

Mia Visakay

The information and recommendations provided are based on the images presented by the referring veterinarian/sonographer. No evaluation can be communicated regarding pathology that was not visible in the image/video clips provided.

SPECIES

Canine

Thank you for this referral. If the clinical or image interpretation does not parallel your findings or if I can be of any further assistance please contact me.

BREED

Pit Bull

Eric Lindquist, DMV, DABVP, Cert. IVUSS, CEO of SonoPath.com
Info@SonoPath.com

SEX

Spayed female

AGE

9 years

WEIGHT

58.1 lbs

INTERPRETED BY

Eric Lindquist, DMV
DABVP, Cert. IVUSS

**IMAGING
PERFORMED BY**

Diane McFadden, RVT

HOSPITAL NAME

Long Valley AH

REFERRING VET

Dr. Welch

INVOICE

43991

DATE

4/25/23