



PATIENT

Lexi Zelster

PRESENTING CLINICAL SIGNS

Elevated liver values.

SPECIES

Feline

ULTRASONOGRAPHIC EXAMINATION OF THE ABDOMEN

Urinary System

BREED

Scottish Fold

The **urinary bladder**, trigone, and pelvic urethra presented normal thicknesses and normal tone. The ureters were not visible which is normal. No uroliths or sediment were visualized and anechoic urine was present. No evidence of inflammatory or neoplastic changes was noted. Ureteral papillae were normal.

SEX

Spayed female

The **kidneys** revealed normal size and structure, corticomedullary definition and ratio for this age. The cortices presented largely uniform texture with normal echogenic relationship to liver and spleen. Medullary structure differed distinctly from the cortex and no evidence of pelvic dilation was present. The capsules were acceptably uniform without significant irregularities. The left kidney measured 3.5 cm. The right kidney measured 3.5 cm.

AGE

5 years

INTERPRETED BY

Eric Lindquist, DMV
DABVP, Cert. IVUSS

Adrenal Glands

Both **adrenal glands** were visualized and recognized as having normal shape, size, position and echogenicity for this breed. The phrenic vasculature, glandular echogenicity and detail were unremarkable. Capsule, cortex, and medullary definition were normal for this age patient.

IMAGING PERFORMED BY

Eric Lindquist, DMV
DABVP, Cert. IVUSS

Spleen

The **spleen** was enlarged and irregular with scalloping contour. The spleen revealed a granular appearance with multi-focal, hyperechoic lipogranulomatous changes. The spleen measured 1.5 cm in maximum width.

HOSPITAL NAME

Butler VH

Liver

The **liver** was enlarged with swollen, irregular contour. Increased portal markings were noted with lobar biliary calculi throughout the liver. The gallbladder was mildly thickened with mild, non-obstructive calculi. The common bile duct was at the upper limits of normal and measured 0.4 cm. The common bile duct was followed to the duodenal papilla. There was no overt obstruction.

REFERRING VET

Dr. Garro

INVOICE

43782

Gastrointestinal

DATE

4/11/23

Examination of the **gastrointestinal tract** revealed a stomach and intestine free of stasis, of normal wall thickness, acceptable curvilinear mural detail, and peristaltic activity. Small and large intestine demonstrated normal luminal chyme and stool consistency respectively. No obstructive or overt infiltrative disease was noted. No associated abnormal lymphatic activity was noted.



PATIENT

Lexi Zelster

Pancreas

The **pancreas** was hypoechoic and irregular primarily in the right limb and base with enhanced surrounding mesentery. This is suggestive for chronic active pancreatitis. The patient was painful upon imaging.

SPECIES

Feline

BREED

Scottish Fold

Free Abdomen

Sublumbar lymph node was enlarged and measured 1.5 x 0.8 cm.

SEX

Spayed female

ULTRASONOGRAPHIC FINDINGS

Cholangitis liver pattern with enlarged spleen. Splenitis versus round cell neoplasia.

Lobar biliary calculi, non-obstructive.

AGE

5 years

Gallbladder calculus, non-obstructive.

INTERPRETED BY

Eric Lindquist, DMV
DABVP, Cert. IVUSS

INTERPRETATION OF THE FINDINGS & FURTHER RECOMMENDATIONS

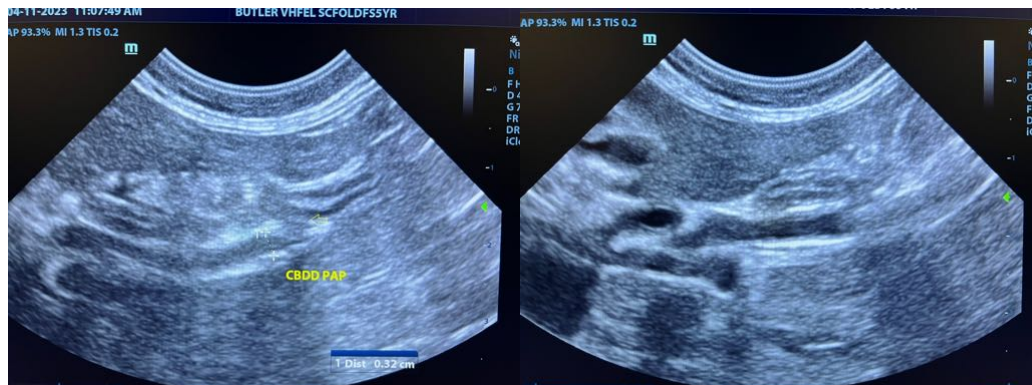
I am concerned for the possibility for transformation of cholangitis and splenitis to potential round cell neoplasia. FNA of the spleen and liver is recommended. Infectious agents should be considered such as Toxoplasmosis and Bartonella. If sampling is not an option then a clinical trial with Clindamycin and Enrofloxacin combination +/- low-dose Prednisolone or Dexamethasone injections can be considered from a palliative standpoint. If successful antibiotic protocol is recommended for 10 days or longer if Bartonella or Toxoplasmosis testing is positive.

IMAGING PERFORMED BY

Eric Lindquist, DMV
DABVP, Cert. IVUSS

HOSPITAL NAME

Butler VH



REFERRING VET

Dr. Garro

INVOICE

43782

DATE

4/11/23



PATIENT

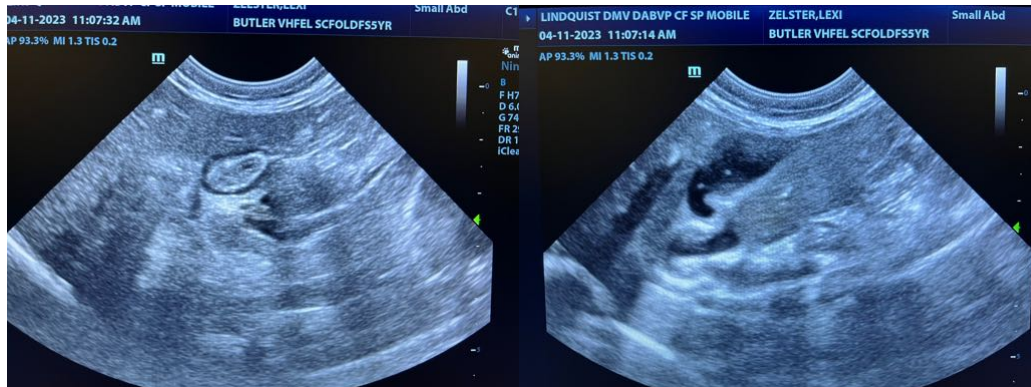Lexi Zelster

SPECIES

Feline

BREED

Scottish Fold

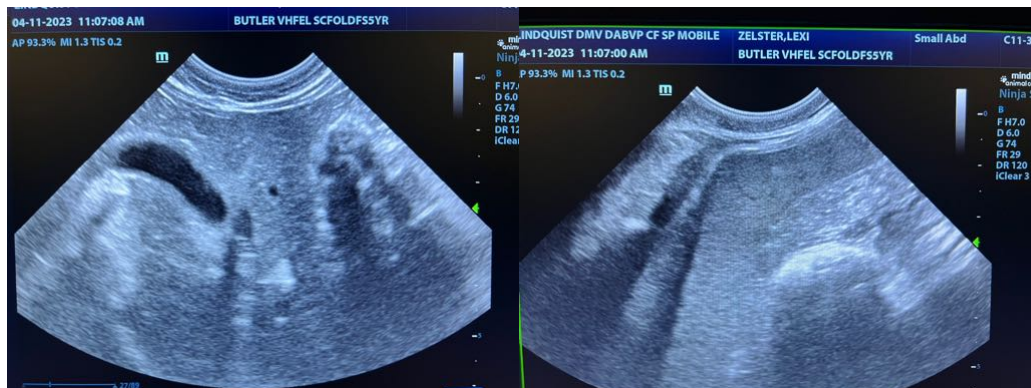


SEX

Spayed female

AGE

5 years



INTERPRETED BY

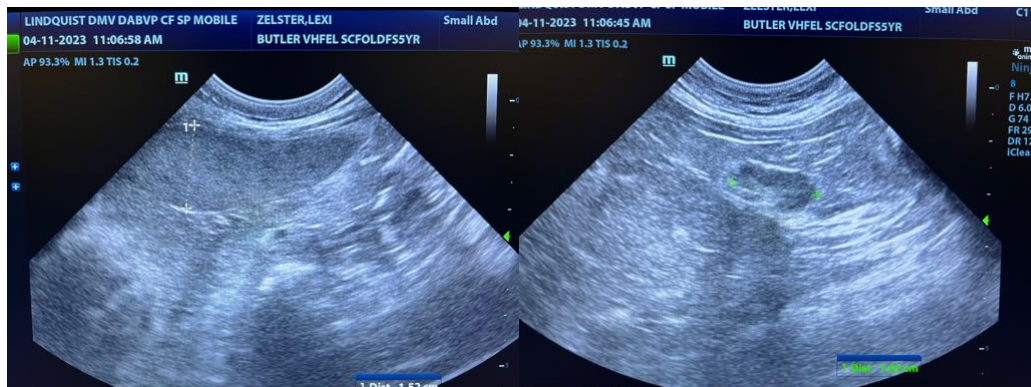
Eric Lindquist, DMV
DABVP, Cert. IVUSS

IMAGING PERFORMED BY

Eric Lindquist, DMV
DABVP, Cert. IVUSS

HOSPITAL NAME

Butler VH



REFERRING VET

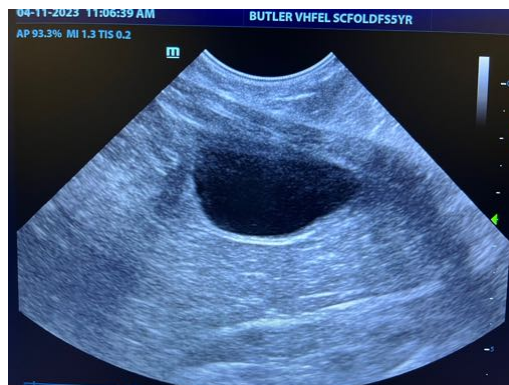Dr. Garro

INVOICE

43782

DATE

4/11/23





PATIENT

Lexi Zelster

The information and recommendations provided are based on the images presented by the referring veterinarian/sonographer. No evaluation can be communicated regarding pathology that was not visible in the image/video clips provided.

SPECIES

Feline

Thank you for this referral. If the clinical or image interpretation does not parallel your findings or if I can be of any further assistance please contact me.

BREED

Scottish Fold

Eric Lindquist, DMV, DABVP, Cert. IVUSS, CEO of SonoPath.com
Info@SonoPath.com

SEX

Spayed female

AGE

5 years

INTERPRETED BY

Eric Lindquist, DMV
DABVP, Cert. IVUSS

IMAGING PERFORMED BY

Eric Lindquist, DMV
DABVP, Cert. IVUSS

HOSPITAL NAME

Butler VH

REFERRING VET

Dr. Garro

INVOICE

43782

DATE

4/11/23