


**PATIENT**

Brody Dempsey

**PRESENTING CLINICAL SIGNS**

Recheck

**SPECIES**

Canine

**BREED**

Shih Tzu

**ULTRASONOGRAPHIC EXAMINATION OF THE HEART**

The echocardiogram in this patient revealed persistent volume overload of the left atrium and left ventricle with prolapse of the anterior mitral valve leaflet. Contractility appears to be adequately compensatory. The right heart was unremarkable with mild tricuspid insufficiency. There was no overt pulmonary hypertension at this time. The right ventricular and right atrial chambers were unremarkable. No pericardial or pleural effusion was noted.

**SEX**

Neutered male

**AGE**

13 years

**INTERPRETED BY**

 Eric Lindquist, DMV  
 DABVP, Cert. IVUSS

**IMAGING PERFORMED BY**

 Eric Lindquist, DMV  
 DABVP, Cert. IVUSS

CANINE CARDIAC PARAMETERS	MR VMAX (m/s)	TR VMAX (m/s)	LA/AO (Boon method)	LA/AO (Heart Base;)	FS (%)	EF (%)	EPSS (cm)
NORMAL PARAMETER	4.5-5.5	<2.7	1.3	<1.6	28-40	40-100	<0.6
PATIENT	5.0	2.21	1.6	2.0	47	80	NM
CANINE CARDIAC PARAMETERS	HR (BPM)	AV VMAX (m/s)	PV MAX (m/s)	BODY WEIGHT (kg)	LA 2D short axis Base view (cm)	LVIDd Avg; 2D and m- mode short axis (cm)	LVIDs Avg; 2D and m-mode short axis (cm)
NORMAL PARAMETER	50-100	0.7-1.7	0.7-1.6	BELOW	BELOW	BELOW	BELOW
PATIENT	187	1.0	0.55		4.4	3.55	

**HOSPITAL NAME**

Butler VH

**ULTRASONOGRAPHIC FINDINGS**
**REFERRING VET**

Dr. Garro

Partially compensated stage C1 valvular disease with persistent volume overload of the left atrium and left ventricle.

**INVOICE**

43783

**DATE**

4/11/23

**INTERPRETATION OF THE FINDINGS & FURTHER RECOMMENDATIONS**

Given that the patient is on quadrotherapy I recommend minor adjustment and increase of Lasix at 2-2.5 mg/kg b.i.d. Target respiratory rate is less than 25/minute. Reassessment of blood pressure measurements, BUN, creatinine and urine specific gravity as well as general exam as well as radiographs 5-10 days post adjustment of the protocol. Recheck sonogram is recommended in 3-6 months or earlier if clinical signs initiate. Prognosis long term is guarded.



**PATIENT**

Brody Dempsey

**SPECIES**

Canine

**BREED**

Shih Tzu

**SEX**

Neutered male

**AGE**

13 years

**INTERPRETED BY**

Eric Lindquist, DMV  
DABVP, Cert. IVUSS

**IMAGING PERFORMED BY**

Eric Lindquist, DMV  
DABVP, Cert. IVUSS

**HOSPITAL NAME**

Butler VH

**REFERRING VET**

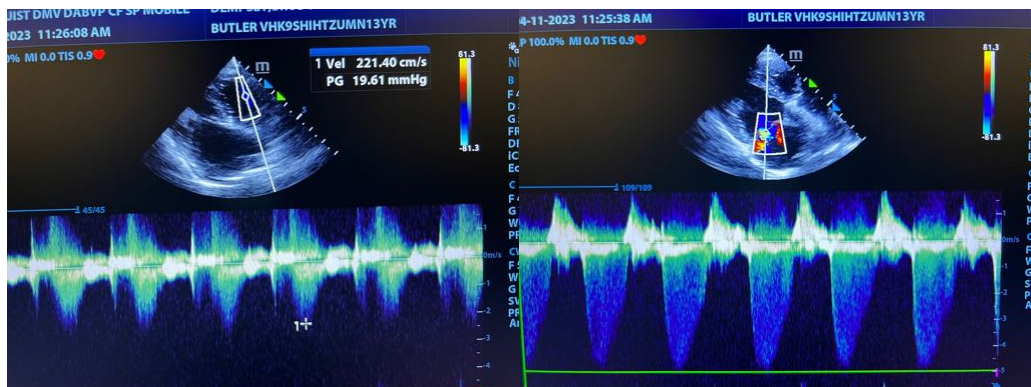
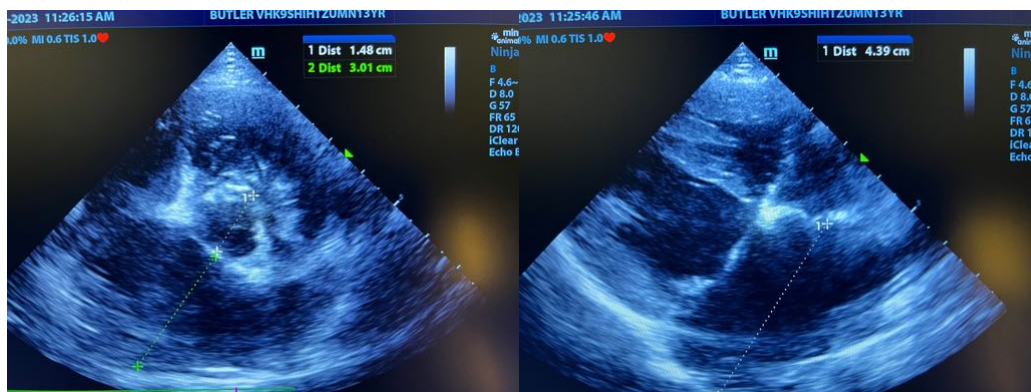
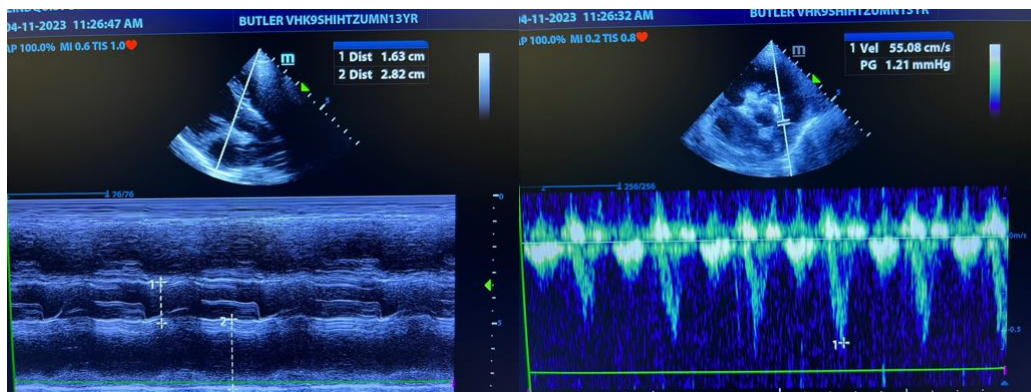
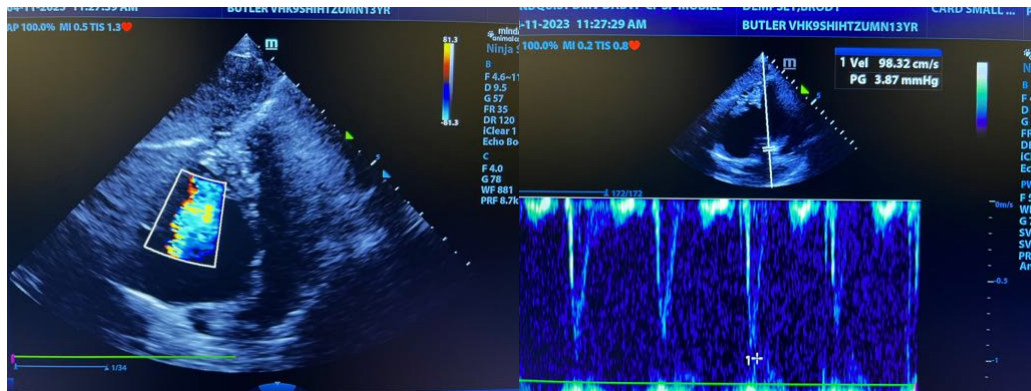
Dr. Garro

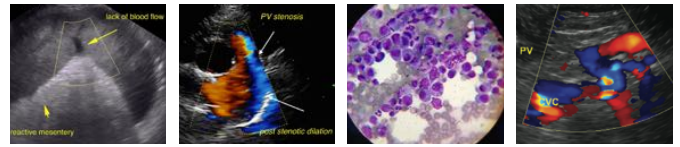
**INVOICE**

43783

**DATE**

4/11/23





**PATIENT**

Brody Dempsey

**SPECIES**

Canine

**BREED**

Shih Tzu

**SEX**

Neutered male

**AGE**

13 years

**INTERPRETED BY**

Eric Lindquist, DMV  
DABVP, Cert. IVUSS

**IMAGING  
PERFORMED BY**

Eric Lindquist, DMV  
DABVP, Cert. IVUSS

**HOSPITAL NAME**

Butler VH

**REFERRING VET**

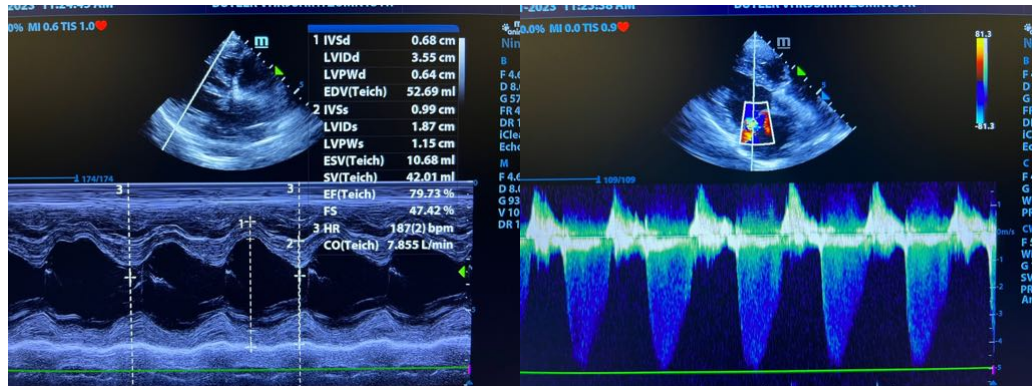
Dr. Garro

**INVOICE**

43783

**DATE**

4/11/23



The information and recommendations provided are based on the images presented by the referring veterinarian/sonographer. No evaluation can be communicated regarding pathology that was not visible in the image/video clips provided.

Thank you for this referral. If the clinical or image interpretation does not parallel your findings or if I can be of any further assistance please contact me.

**Eric Lindquist**, DMV, DABVP, Cert. IVUSS, CEO of SonoPath.com  
Info@SonoPath.com