


PATIENT PRESENTING CLINICAL SIGNS

Guinness Giatomusi

History: Grade 5-6/6 murmur, 1 yr follow-up. Not coughing. Double cav done 3/14/22. Current meds: Pimobendan 5mg 1/2 T q 12hrs, Enalapril 5mg BID

SPECIES

Abnormal PE/Chem/CBC/UA Results: ALKP 440, ALT 317, Ca 12.2, Mg 2.6, K+ 5.8 UPC 5.1 - (O had stopped Enalapril) SG: 1.009

Canine

BREED

Mix

SEX

Spayed female

AGE

13 years

WEIGHT

29 lbs

INTERPRETED BY

 Eric Lindquist, DMV
 DABVP, Cert. IVUSS

IMAGING PERFORMED BY

Jessica Miller, RDMS

HOSPITAL NAME

Sova AH

REFERRING VET

Dr. Ammeraal

INVOICE

43760

DATE

4/10/23

ULTRASONOGRAPHIC EXAMINATION OF THE HEART

The echocardiogram in this patient presented mitral and tricuspid insufficiency with mild prolapse of the anterior mitral valve leaflet. Left atrial size was contained. Moderate filling of the left atrium was noted. All four chambers revealed relatively normal volume. No pericardial or pleural effusion was noted. Mitral and tricuspid aortic and pulmonic insufficiency were all present, yet no significant secondary changes were noted in the heart. Normal compensatory function was noted.

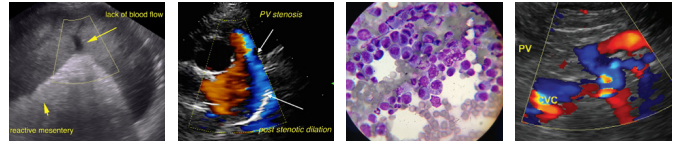
CANINE CARDIAC PARAMETERS	MR VMAX (m/s)	TR VMAX (m/s)	LA/AO (Boon method)	LA/AO (Heart Base;)	FS (%)	EF (%)	EPSS (cm)
NORMAL PARAMETER	4.5-5.5	<2.7	1.3	<1.6	28-40	40-100	<0.6
PATIENT	6.0	2.13	1.4	1.7	49	81	0.25
CANINE CARDIAC PARAMETERS	HR (BPM)	AV VMAX (m/s)	PV MAX (m/s)	BODY WEIGHT	LA (2D short axis Base view) (cm)	LVIDd (Avg; 2D and m-mode short axis) (cm)	LVIDs (Avg; 2D and m-mode short axis) (cm)
NORMAL PARAMETER	50-100	0.7-1.7	0.7-1.6	BELOW	BELOW	BELOW	BELOW
PATIENT	103	1.74	1.98	29 lbs	4.18	3.75	

ULTRASONOGRAPHIC FINDINGS

Stable valvular disease.

INTERPRETATION OF THE FINDINGS & FURTHER RECOMMENDATIONS

I recommend continuation of the current protocol.



PATIENT

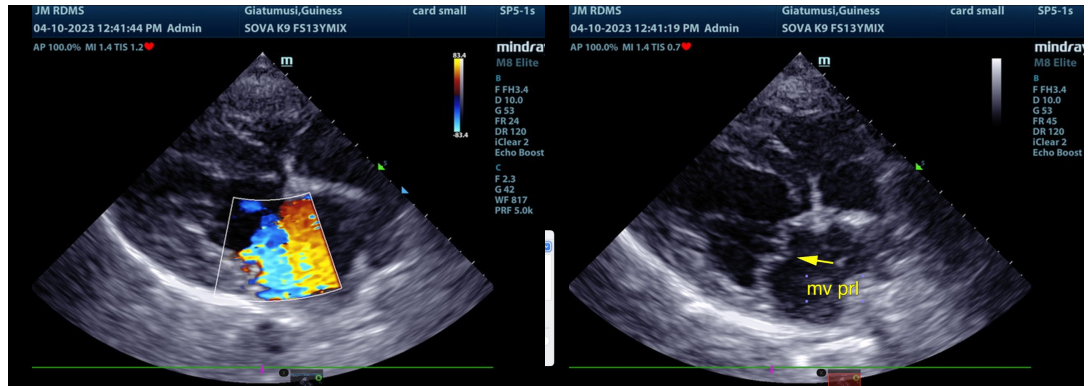
Guinness Giatumusi

SPECIES

Canine

BREED

Mix



SEX

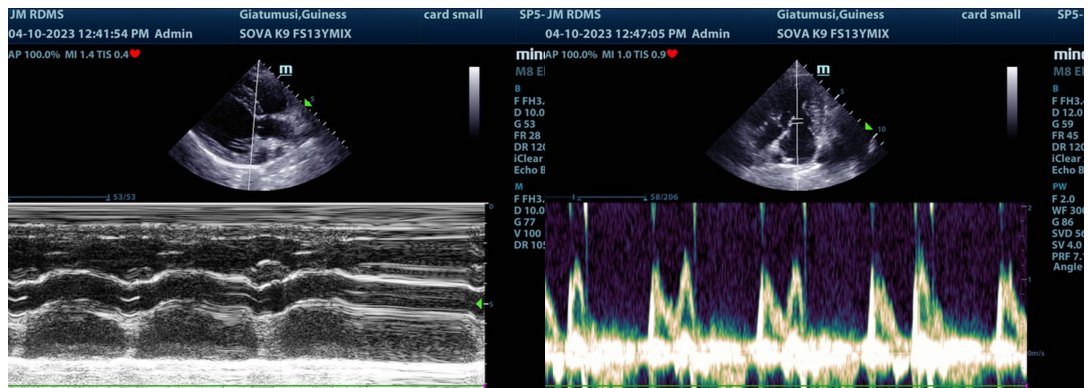
Spayed female

AGE

13 years

WEIGHT

29 lbs



INTERPRETED BY

Eric Lindquist, DMV
DABVP, Cert. IVUSS

IMAGING PERFORMED BY

Jessica Miller, RDMS

HOSPITAL NAME

Sova AH

REFERRING VET

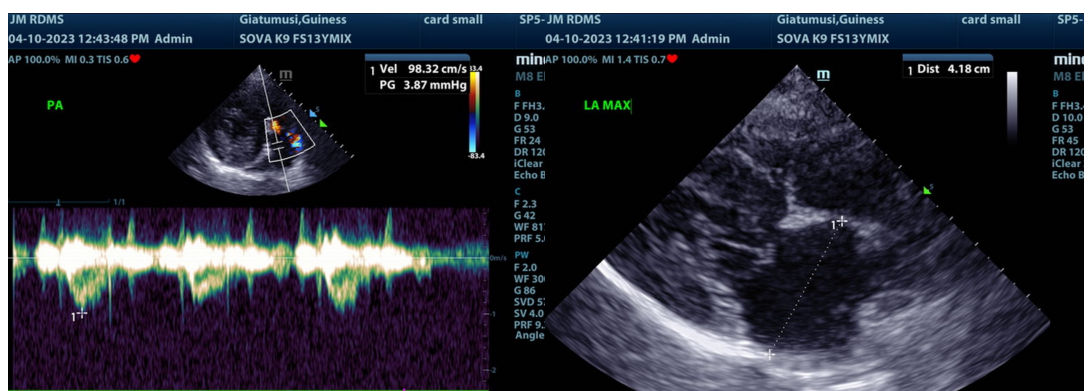
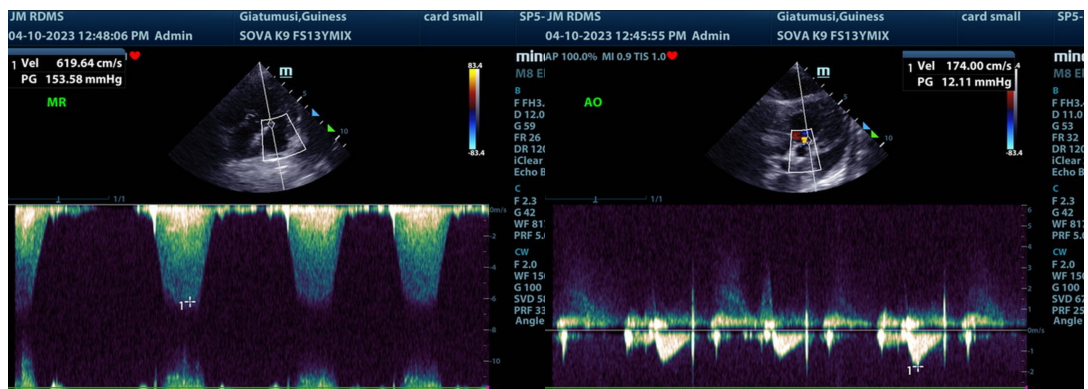
Dr. Ammeraal

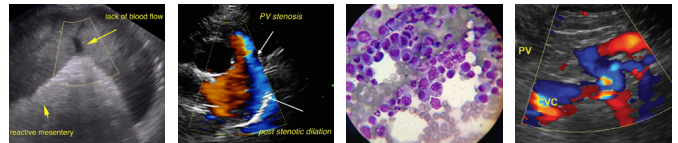
INVOICE

43760

DATE

4/10/23





PATIENT

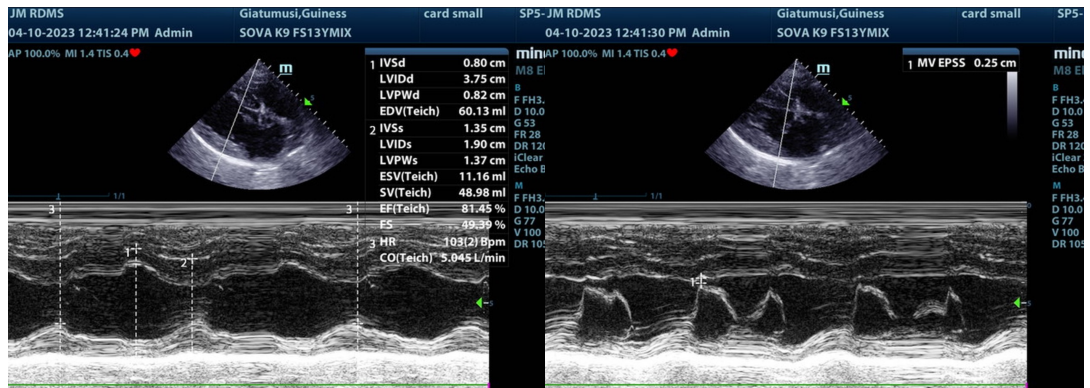
Guinness Giatumusi

SPECIES

Canine

BREED

Mix



SEX

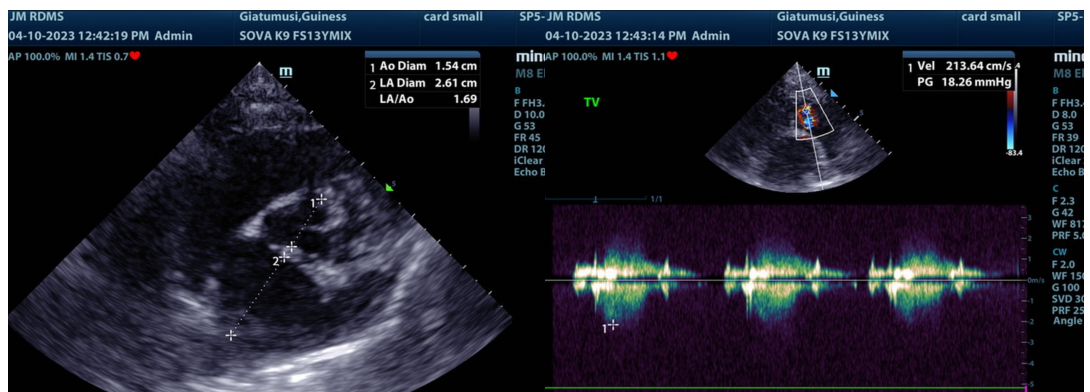
Spayed female

AGE

13 years

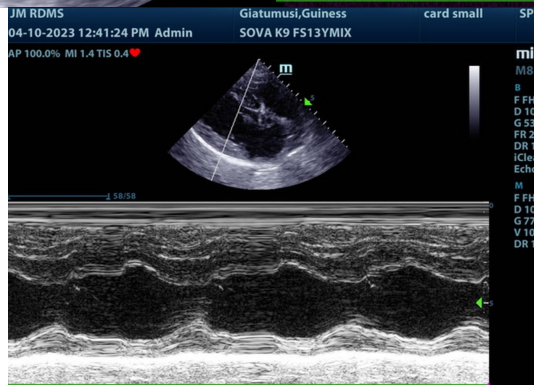
WEIGHT

29 lbs



INTERPRETED BY

Eric Lindquist, DMV
DABVP, Cert. IVUSS



IMAGING PERFORMED BY

Jessica Miller, RDMS

HOSPITAL NAME

Sova AH

REFERRING VET

Dr. Ammeraal

INVOICE

43760

DATE

4/10/23

The information and recommendations provided are based on the images presented by the referring veterinarian/sonographer. No evaluation can be communicated regarding pathology that was not visible in the image/video clips provided.

Thank you for this referral. If the clinical or image interpretation does not parallel your findings or if I can be of any further assistance please contact me.

Eric Lindquist, DMV, DABVP, Cert. IVUSS, CEO of SonoPath.com
Info@SonoPath.com