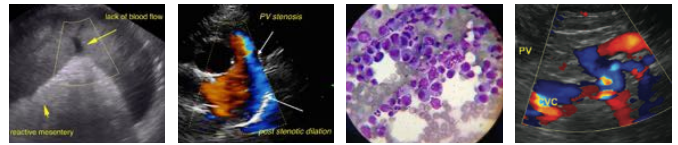


PATIENT	PRESENTING CLINICAL SIGNS
Romeo Giampietro	History: Pre-sx for dental and skin tag removal. Recheck prev. found adrenal nodule.
SPECIES	ULTRASONOGRAPHIC EXAMINATION OF THE ABDOMEN
Canine	Urinary System
BREED	The urinary bladder , trigone, and pelvic urethra presented normal thicknesses and normal tone. The ureters were not visible which is normal. No uroliths or sediment were visualized and anechoic urine was present. No evidence of inflammatory or neoplastic changes was noted. Ureteral papillae were normal.
Rottweiler	The residual prostate was uniform and measured 0.14 cm.
SEX	The kidneys revealed largely normal size and structure, corticomedullary definition and ratio (cortex 1/3 of medulla) were essentially maintained with some age-related loss of curvilinear patterns regarding the capsule and C/M junction. The cortices presented largely uniform texture with some increased echogenicity expected for his age patient. Medullary structure differed distinctly from that of the cortex and no evidence of pelvic dilation was present. The left kidney measured 6.28 cm.
Neutered male	
AGE	Adrenal Glands
9 years	The right adrenal gland revealed mildly heterogenous nodules at the cranial pole and measured 1.6 cm at the cranial pole and 0.9 cm at the caudal pole. The right adrenal gland measured 2.91 x 0.65 cm at the aural pole and 0.58 cm at the cranial pole. The left adrenal gland measured 2.36 x 0.58 cm at the cranial pole and 0.69 cm at the caudal pole.
WEIGHT	Spleen
117 lbs	The spleen presented a smooth homogeneous parenchyma hyperechoic to liver and renal cortical parenchyma. The capsule was smooth without noticeable expansion or deviation from within the spleen or adjacent pathology. The splenic vasculature demonstrated normal volume without signs of congestion or thrombosis. No sonographic evidence of acute or chronic inflammatory, neoplastic, or infarctual changes was noted.
INTERPRETED BY	Liver
Eric Lindquist, DMV DABVP, Cert. IVUSS	The liver images submitted revealed subjectively normal liver size, contour, and structure. Parenchymal echogenicity was naturally coarse and hypoechoic to the spleen. Vascular and biliary tracts were of normal volume with no evidence of congestion. The gallbladder presented acceptably thin walls with primarily anechoic content. The cystic and common bile ducts were normal. No pathological hepatic lymphadenopathy was evident. No overt structural evidence of inflammatory, infiltrative or regenerative pathology was evident.
IMAGING PERFORMED BY	
Shari Reffi, CVT	
HOSPITAL NAME	
Whippany VH	
REFERRING VET	
Dr. Smith	
INVOICE	
43236	
DATE	
3/9/23	



PATIENT

Gastrointestinal

Romeo Giampietro

Examination of the **gastrointestinal tract** revealed a stomach and intestine free of stasis, of normal wall thickness, acceptable curvilinear mural detail, and peristaltic activity. Small and large intestine demonstrated normal luminal chyme and stool consistency respectively. No obstructive or overt infiltrative disease was noted. No associated abnormal lymphatic activity was noted.

SPECIES

Canine

BREED

Rottweiler

SEX

Neutered male

AGE

9 years

WEIGHT

117 lbs

Pancreas

The base and limbs of the **pancreas** were observed to be largely isoechoic to surrounding omental fat. Pancreatic duct and capsular contour were acceptably normal and parenchyma respected normal curvilinear patterns. No overt evidence of active inflammatory or neoplastic disease was noted.

ULTRASONOGRAPHIC FINDINGS

Stable right adrenal gland.

Age related renal changes.

INTERPRETATION OF THE FINDINGS & FURTHER RECOMMENDATIONS

There was no significant from the prior sonogram. There is no contraindication to anesthetic procedure.

INTERPRETED BY

Eric Lindquist, DMV
DABVP, Cert. IVUSS

IMAGING PERFORMED BY

Shari Reffi, CVT

HOSPITAL NAME

Whippany VH

REFERRING VET

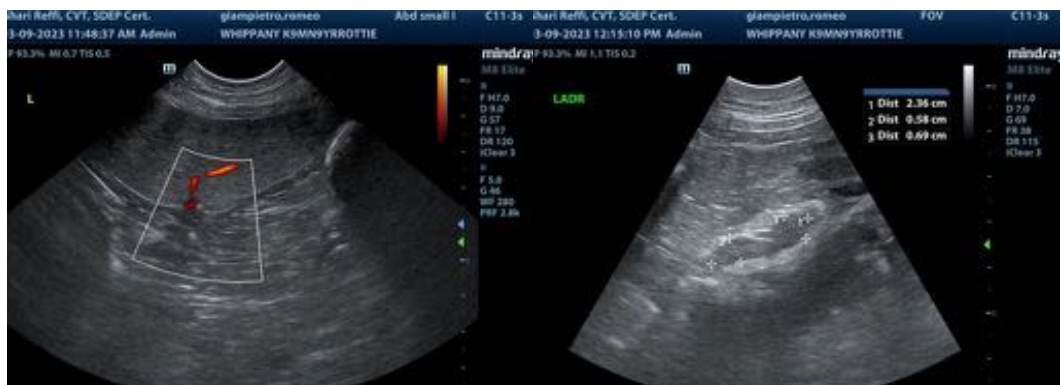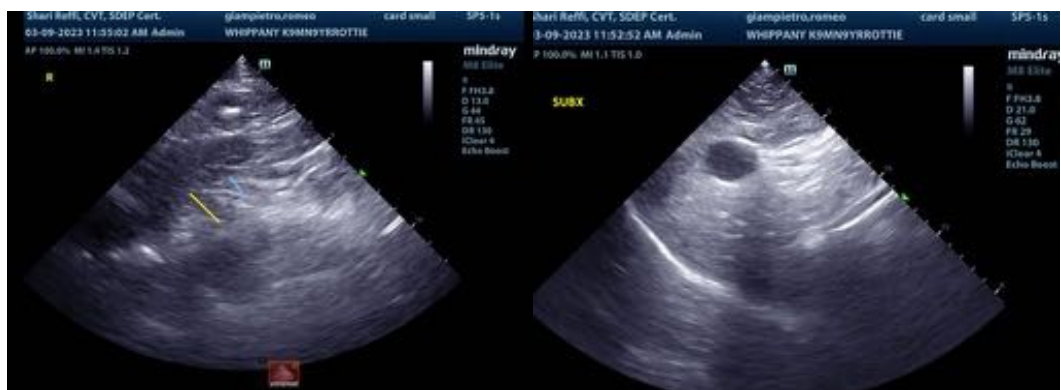
Dr. Smith

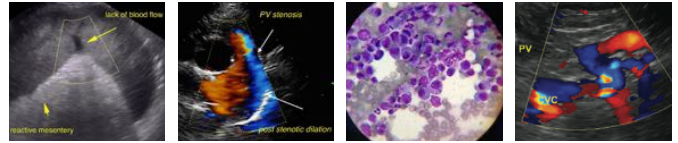
INVOICE

43236

DATE

3/9/23





PATIENT

Romeo Giampietro

SPECIES

Canine

BREED

Rottweiler

SEX

Neutered male

AGE

9 years

WEIGHT

117 lbs

INTERPRETED BY

Eric Lindquist, DMV
DABVP, Cert. IVUSS

IMAGING PERFORMED BY

Shari Reffi, CVT

HOSPITAL NAME

Whippany VH

REFERRING VET

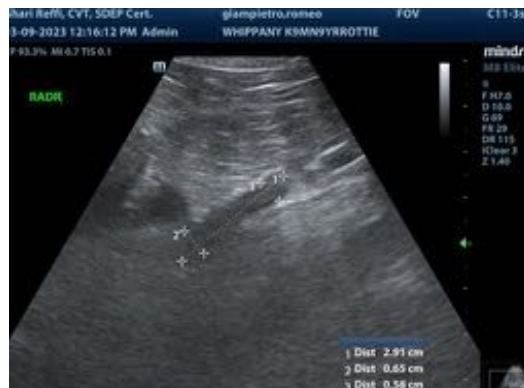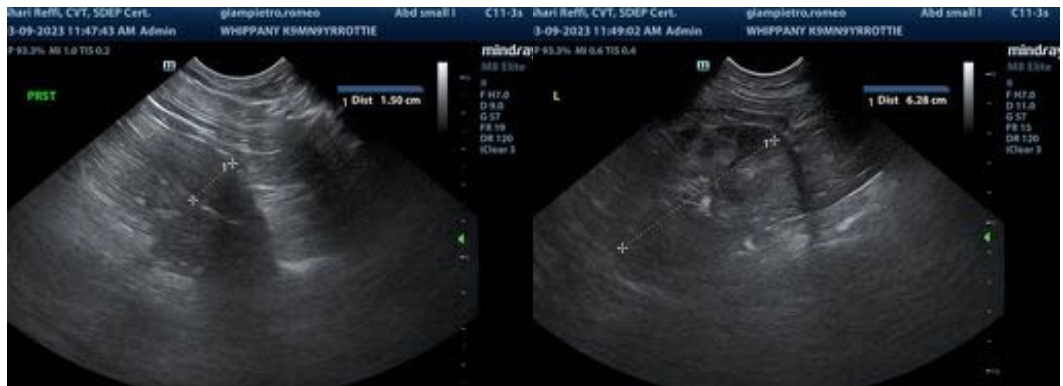Dr. Smith

INVOICE

43236

DATE

3/9/23



The information and recommendations provided are based on the images presented by the referring veterinarian/sonographer. No evaluation can be communicated regarding pathology that was not visible in the image/video clips provided.

Thank you for this referral. If the clinical or image interpretation does not parallel your findings or if I can be of any further assistance please contact me.

Eric Lindquist, DMV, DABVP, Cert. IVUSS, CEO of SonoPath.com
Info@SonoPath.com