SonoPath
Clinical Sonography & Telecytology

EDUCATIONAL TELECONSULTATION SERVICES™

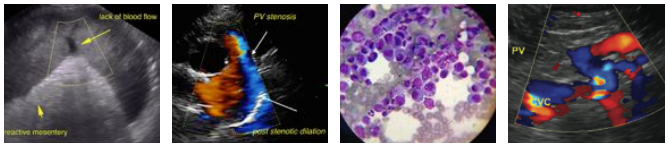

SonoPath.com™
1-800-838-4268 info@sonopath.com

PATIENT
Deuce Quinn

SPECIES
Canine

BREED
Doberman

SEX
Neutered male

AGE
3 years

WEIGHT
110.5 lbs

INTERPRETED BY
Eric Lindquist, DMV DABVP, Cert. IVUSS

IMAGING PERFORMED BY
Valeryia Shumskaya

HOSPITAL NAME
Warren AH

REFERRING VET
Dr. Nicole

INVOICE
43194

DATE
3/8/23

PRESENTING CLINICAL SIGNS

History: Screening for DCM. On raw diet

ULTRASONOGRAPHIC EXAMINATION OF THE HEART

The echocardiogram in this patient demonstrated normal **left atrial** size based on 3 separate methods of LA evaluation. The cranial and caudal **mitral** valve leaflets presented normal linear structure, extension in systole, and union in diastole with normal kinesis. The **left ventricle** presented thicknesses with linear contour and was not dilated nor restricted. The **myocardium** presented normal echogenicity without subjective evidence of significant fibrotic or ischemic disease. **Contractility** of the ventricular walls was adequate and in normal range for this patient evidenced by the fractional shortening measurement and subjective evaluation of the different regions of the myocardium. The **left ventricular outflow** tract demonstrated normal laminar flow and subjective structural integrity. The **right atrium** and auricle revealed normal size, structure and content. No evidence of masses was noted. **Tricuspid** valvular assessment demonstrated adequate linear morphology and kinesis. The **right ventricle** was of normal size (1/3 diameter of LV), chordae structure, myocardial echogenicity and thickness. **Pulmonary outflow** tract assessment revealed normal valve structure, laminar flow, and diameter (approx.1:1 pa/ao ratio). No visible **pericardial** or free pleura fluid was noted. The cranial **mediastinum and pericardial and extra-cardiac regions** were free of masses in the visible window.

CANINE CARDIAC PARAMETERS	MR VMAX (m/s)	TR VMAX (m/s)	LA/AO (Boon method)	LA/AO (Heart Base;)	FS (%)	EF (%)	EPSS (cm)
NORMAL PARAMETER	4.5-5.5	<2.7	1.3	<1.6	28-40	40-100	<0.6
PATIENT			1.3	1.4	33	61	0.1
CANINE CARDIAC PARAMETERS	**HR** (BPM)	**AV VMAX** (m/s)	**PV MAX** (m/s)	**BODY WEIGHT**	**LA** 2D short axis Base view (cm)	**LVIDd** Avg; 2D and m-mode short axis (cm)	**LVIDs** Avg; 2D and m-mode short axis (cm)
NORMAL PARAMETER	50-100	0.7-1.7	0.7-1.6	BELOW	BELOW	BELOW	BELOW
PATIENT	129	2.07	1.0	110.5 lbs	5.0 max	4.5	

ULTRASONOGRAPHIC FINDINGS

Normal echocardiogram, no evidence of pathology.

Normal contractility and volumes.

INTERPRETATION OF THE FINDINGS & FURTHER RECOMMENDATIONS

There was no evidence of nutritional cardiomyopathy or dilated cardiomyopathy.

SonoPath
Clinical Sonography & Telecytology

EDUCATIONAL TELECONSULTATION SERVICES™

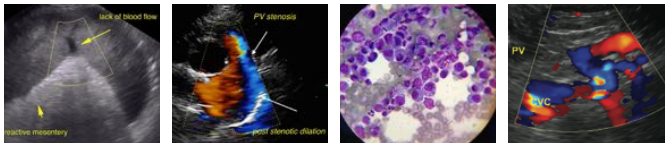

SonoPath.com™
1-800-838-4268 info@sonopath.com

PATIENT

Deuce Quinn

SPECIES

Canine

BREED

Doberman

SEX

Neutered male

AGE

3 years

WEIGHT

110.5 lbs

INTERPRETED BY

Eric Lindquist, DMV
DABVP, Cert. IVUSS

IMAGING PERFORMED BY

Valeryia Shumskaya

HOSPITAL NAME

Warren AH

REFERRING VET

Dr. Nicole

INVOICE

43194

DATE

3/8/23

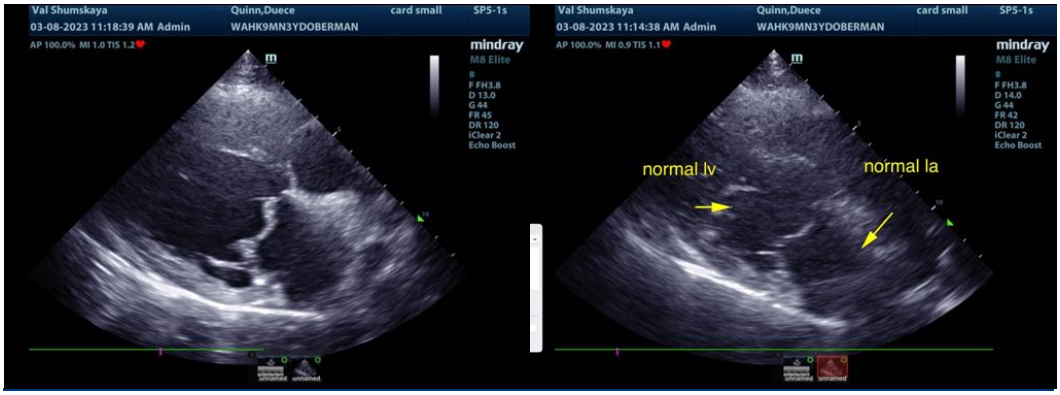

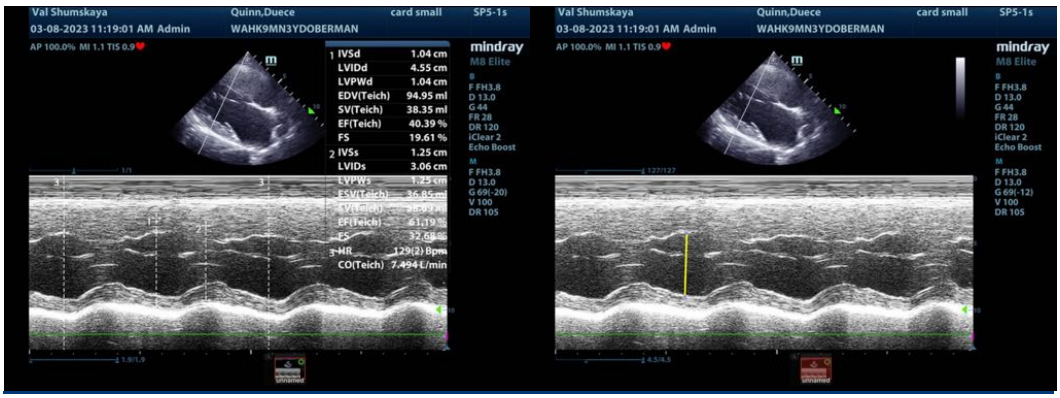

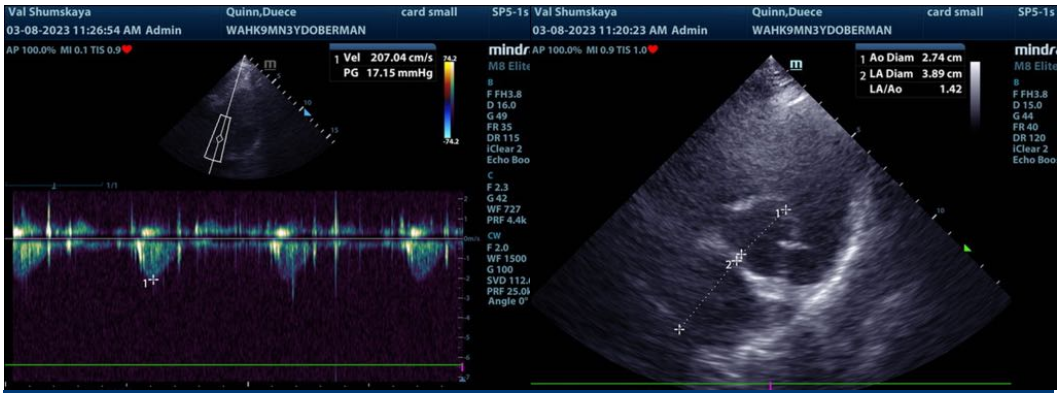

The information and recommendations provided are based on the images presented by the referring veterinarian/sonographer. No evaluation can be communicated regarding pathology that was not visible in the image/video clips provided.

Thank you for this referral. If the clinical or image interpretation does not parallel your findings or if I can be of any further assistance please contact me.

Eric Lindquist, DMV, DABVP, Cert. IVUSS
info@SonoPath.com