



PATIENT

Summer Parrino

PRESENTING CLINICAL SIGNS

Recurrent gastroenteritis.

SPECIES

Canine

ULTRASONOGRAPHIC EXAMINATION OF THE ABDOMEN

Urinary System

BREED

Golden Retriever

The **urinary bladder**, trigone, and pelvic urethra presented normal thicknesses and normal tone. The ureters were not visible which is normal. No uroliths or sediment were visualized and anechoic urine was present. No evidence of inflammatory or neoplastic changes was noted. Ureteral papillae were normal.

SEX

Spayed female

The **kidneys** revealed normal size and structure, corticomedullary definition and ratio for this age. The cortices presented largely uniform texture with normal echogenic relationship to liver and spleen. Medullary structure differed distinctly from the cortex and no evidence of pelvic dilation was present. The capsules were acceptably uniform without significant irregularities. The left kidney measured 6.18 cm.

AGE

2022

INTERPRETED BY

Eric Lindquist, DMV
DABVP, Cert. IVUSS

Adrenal Glands

Both **adrenal glands** were visualized and recognized as having normal shape, size, position and echogenicity for this breed. The phrenic vasculature, glandular echogenicity and detail were unremarkable. Capsule, cortex, and medullary definition were normal for this age patient. The right adrenal gland measured 2.2 x 1.34 cm at the cranial pole and 0.86 cm at th caudal pole. The left adrenal gland measured 2.07 x 0.45 cm.

IMAGING PERFORMED BY

Eric Lindquist, DMV
DABVP, Cert. IVUSS

Spleen

HOSPITAL NAME

Franklin Lakes AH

The **spleen** presented a smooth homogeneous parenchyma hyperechoic to liver and renal cortical parenchyma. The capsule was smooth without noticeable expansion or deviation from within the spleen or adjacent pathology. The splenic vasculature demonstrated normal volume without signs of congestion or thrombosis. No sonographic evidence of acute or chronic inflammatory, neoplastic, or infarctual changes was noted.

REFERRING VET

Dr. Rizzo

Liver

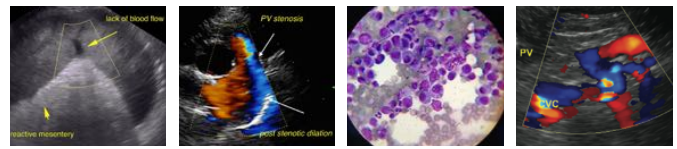
INVOICE

43627

The **liver** images submitted revealed subjectively normal liver size, contour, and structure. Parenchymal echogenicity was naturally coarse and hypoechoic to the spleen. Vascular and biliary tracts were of normal volume with no evidence of congestion. The gallbladder presented acceptably thin walls with primarily anechoic content. The cystic and common bile ducts were normal. No pathological hepatic lymphadenopathy was evident. No overt structural evidence of inflammatory, infiltrative or regenerative pathology was evident.

DATE

3/30/23



PATIENT

Gastrointestinal

Summer Parrino

A 6.5 x 4.0 cm translucent, fluid filled structure was noted in the jejunum with regional, hyperechoic surrounding fat. This is consistent with peritonitis. Partial obstructive pattern was noted with mild, dilated hyperperistalsis. The upper gastrointestinal tract was followed by the foreign structure and empty small intestine. Trace amounts of free fluid was noted in the abdomen. This is consistent with emerging peritonitis. Variable small intestinal thickening was noted. This is suggestive for underlying inflammatory bowel or similar. Regional lymph nodes were reactive and measured up to 2.5 cm.

SPECIES

Canine

BREED

Golden Retriever

Pancreas

The base and limbs of the **pancreas** were observed to be largely isoechoic to surrounding omental fat. Pancreatic duct and capsular contour were acceptably normal and parenchyma respected normal curvilinear patterns. No overt evidence of active inflammatory or neoplastic disease was noted.

SEX

Spayed female

ULTRASONOGRAPHIC FINDINGS

AGE

2022

Jejunal foreign body with emerging peritonitis.

Intestinal thickening, likely underlying chronic disease.

INTERPRETED BY

Eric Lindquist, DMV
DABVP, Cert. IVUSS

INTERPRETATION OF THE FINDINGS & FURTHER RECOMMENDATIONS

Immediate enterotomy and GI biopsies are recommended.

IMAGING PERFORMED BY

Eric Lindquist, DMV
DABVP, Cert. IVUSS

According to SonoPath research presented at ECVIM 2016 (Stockholm, Sweden), Advances in Small Animal Medicine and Surgery (May 2017), and EVDI 2017 (Verona, Italy), concurrent underlying chronic inflammatory neoplastic intestinal disease can often reside in PICA patients. Therefore, surgical biopsies are essential in this case regardless of the exploratory findings.

HOSPITAL NAME

Franklin Lakes AH

REFERRING VET

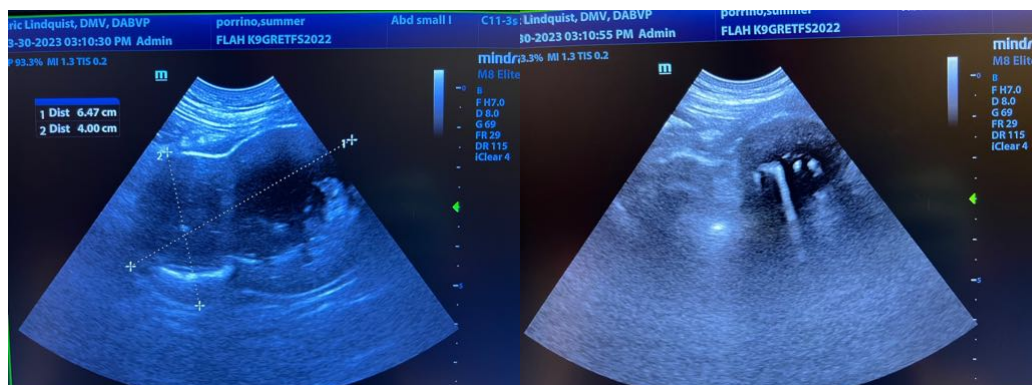
Dr. Rizzo

INVOICE

43627

DATE

3/30/23





PATIENT

Summer Parrino

SPECIES

Canine

BREED

Golden Retriever

SEX

Spayed female

AGE

2022

INTERPRETED BY

Eric Lindquist, DMV
DABVP, Cert. IVUSS

IMAGING PERFORMED BY

Eric Lindquist, DMV
DABVP, Cert. IVUSS

HOSPITAL NAME

Franklin Lakes AH

REFERRING VET

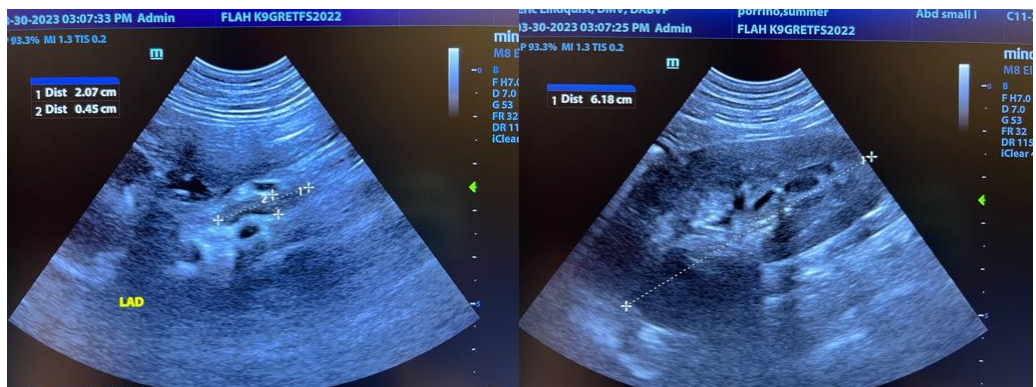
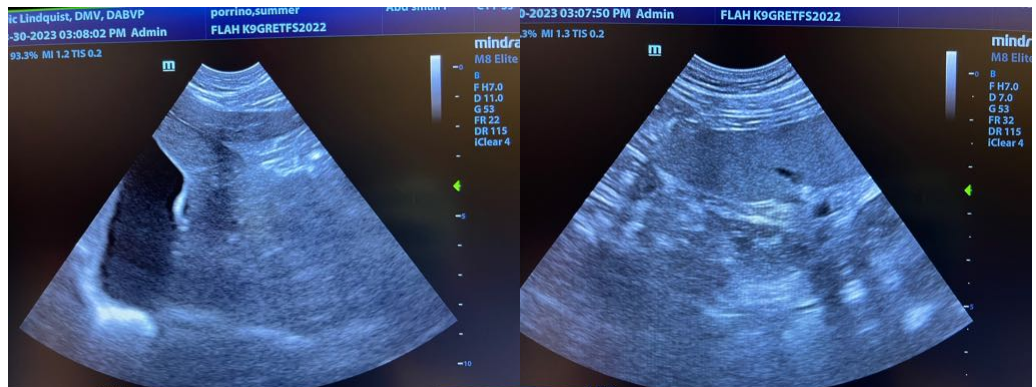
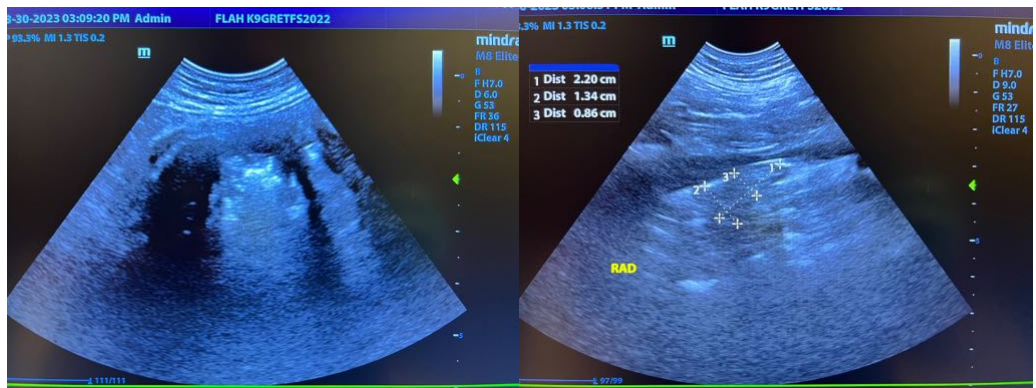
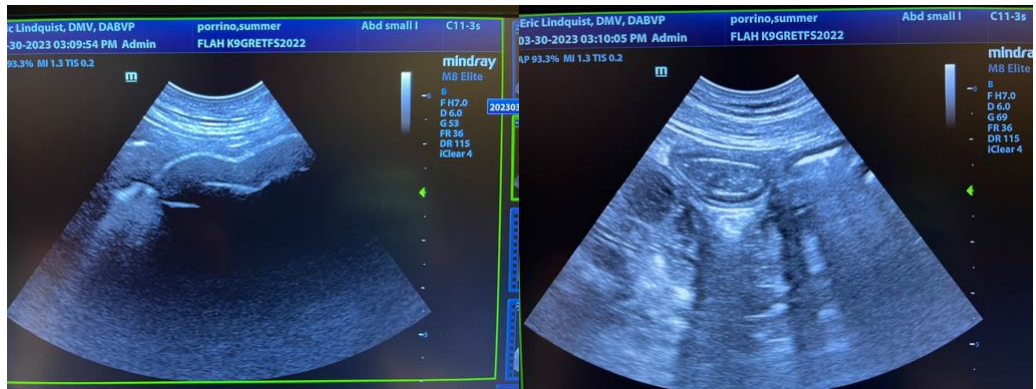
Dr. Rizzo

INVOICE

43627

DATE

3/30/23





PATIENT

Summer Parrino

The information and recommendations provided are based on the images presented by the referring veterinarian/sonographer. No evaluation can be communicated regarding pathology that was not visible in the image/video clips provided.

SPECIES

Canine

Thank you for this referral. If the clinical or image interpretation does not parallel your findings or if I can be of any further assistance please contact me.

BREED

Golden Retriever

Eric Lindquist, DMV, DABVP, Cert. IVUSS, CEO of SonoPath.com
Info@SonoPath.com

SEX

Spayed female

AGE

2022

INTERPRETED BY

Eric Lindquist, DMV
DABVP, Cert. IVUSS

**IMAGING
PERFORMED BY**

Eric Lindquist, DMV
DABVP, Cert. IVUSS

HOSPITAL NAME

Franklin Lakes AH

REFERRING VET

Dr. Rizzo

INVOICE

43627

DATE

3/30/23