



PATIENT

Reese Luciano

SPECIES

Canine

BREED

Terrier Mix

SEX

Spayed female

AGE

12 years

WEIGHT

51.4 lbs

PRESENTING CLINICAL SIGNS

History: Weight loss, heart murmur, pulmonary edema. Current meds: Percorten injections q 5 weeks; prednisone.

Abnormal PE/Chem/CBC/UA Results: SAP 2322. U/A: UTI (voided sample), USG 1.033.

ULTRASONOGRAPHIC EXAMINATION OF THE ABDOMEN

The echocardiogram in this patient demonstrated enlarged **left atrial** size based on 3 different LA measurement methods. Chamber volumes and echogenicity were normal. The cranial and caudal **mitral** valve leaflets presented vegetative thickening consistent with endocardiosis. Doppler indicated measurable insufficiency. The **left ventricle** presented normal thicknesses with linear contour and was not dilated nor restricted. The **myocardium** presented normal echogenicity without subjective evidence of significant fibrotic or ischemic disease. **Contractility** of the ventricular walls was adequate and in normal range for this patient evidenced by the fractional shortening measurement and subjective evaluation of the different regions of the myocardium. The **left ventricular outflow** tract demonstrated normal laminar flow and subjective structural integrity. The **right atrium** and auricle revealed normal size, structure and content. No evidence of masses was noted or chamber overload. Minor **tricuspid** insufficiency was noted. The **right ventricle** was of normal size (1/3 diameter of LV), chordae structure, myocardial echogenicity and thickness. **Pulmonic** tract assessment revealed normal valve structure, laminar flow, and diameter (approx. 1:1 pa/ao ratio). No visible **pericardial** or free pleura fluid was noted. No echographically detectable evidence of infiltrative disease was visible. The cranial **mediastinum and pericardial regions** were free of masses in the visible window. Ring down lung pattern was noted. This is consistent with alveolar occupation.

INTERPRETED BY

Eric Lindquist, DMV,
DABVP, Cert. IVUSS,
CEO of SonoPath.com

IMAGING PERFORMED BY

Kelly Vazquez, CVT

HOSPITAL NAME

Hillsdale AH

REFERRING VET

Dr. Fischer

INVOICE

43646

DATE

3/30/23

CANINE CARDIAC PARAMETERS	MR VMAX (m/s)	TR VMAX (m/s)	LA/AO (Boon method)	LA/AO (Heart Base)	FS (%)	EF (%)	EPSS (cm)
NORMAL PARAMETER	4.5-5.5	<2.7	1.3	<1.6	28-40	40-100	<0.6
PATIENT	6.0		NM	2.0	40	70	NM
CANINE CARDIAC PARAMETERS	HR (BPM)	AV VMAX (m/s)	PV MAX (m/s)	BODY WEIGHT (kg)	LA 2D short axis Base view (cm)	LVIDd Avg; 2D and m-mode short axis (cm)	LVIDs Avg; 2D and m-mode short axis (cm)
NORMAL PARAMETER	50-100	0.7-1.7	0.7-1.6	BELOW	BELOW	BELOW	BELOW
PATIENT	115	1.56	0.79	51.4	6.9	5.22	



PATIENT

Reese Luciano

ULTRASONOGRAPHIC FINDINGS

Mitral insufficiency.

SPECIES

Canine

B2+-C1 valvular disease depending on radiographic findings.

BREED

Terrier Mix

INTERPRETATION OF THE FINDINGS & FURTHER RECOMMENDATIONS

I recommend triple therapy in this patient with ace inhibitor at 0.5 mg/kg s.i.d. progressing to b.i.d. Pimobendan at 0.3 mg/kg b.i.d. and Lasix at 1-2 mg/kg b.i.d.

SEX

Spayed female

Given the ring down B lines and significant left atrial enlargement and volume overload, left-sided heart failure is likely. I recommend diminishing the cortisone therapy as it may be amplifying the volume overload. Recheck echocardiogram is recommended in 1 month or earlier if clinical signs exacerbate. Blood pressure measurements and chest radiographs are all indicated as well as target sleeping respiratory rate of less than 25/minute.

AGE

12 years

WEIGHT

51.4 lbs

INTERPRETED BY

Eric Lindquist, DMV,
DABVP, Cert. IVUSS,
CEO of SonoPath.com

IMAGING PERFORMED BY

Kelly Vazquez, CVT

HOSPITAL NAME

Hillsdale AH

REFERRING VET

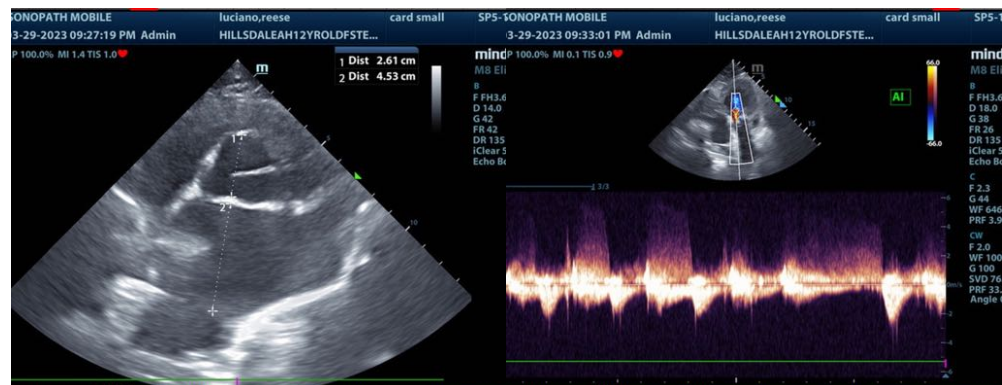
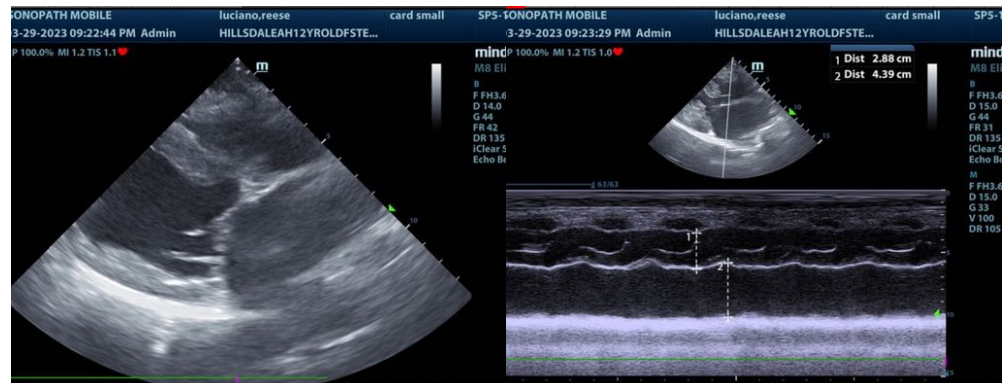
Dr. Fischer

INVOICE

43646

DATE

3/30/23





PATIENT

Reese Luciano

SPECIES

Canine

BREED

Terrier Mix

SEX

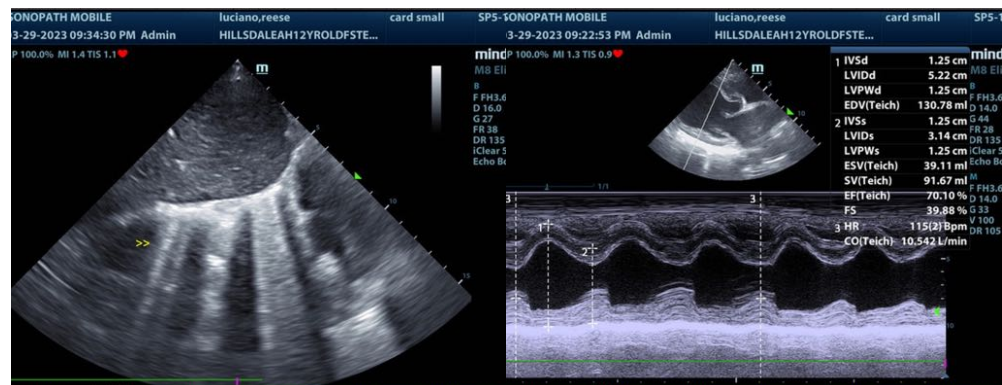
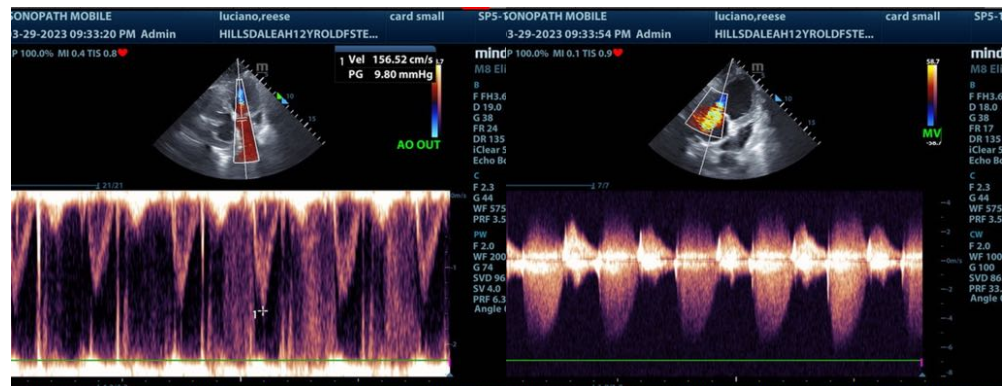
Spayed female

AGE

12 years

WEIGHT

51.4 lbs



INTERPRETED BY

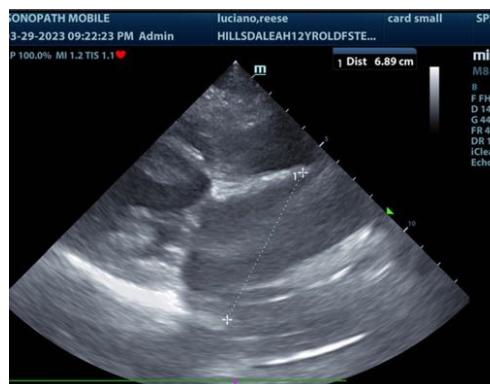
Eric Lindquist, DMV, DABVP, Cert. IVUSS, CEO of SonoPath.com

IMAGING PERFORMED BY

Kelly Vazquez, CVT

HOSPITAL NAME

Hillsdale AH



REFERRING VET

Dr. Fischer

INVOICE

43646

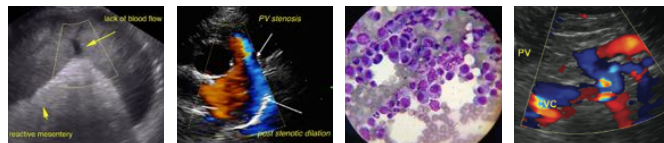
DATE

3/30/23

The information and recommendations provided are based on the images presented by the referring veterinarian/sonographer. No evaluation can be communicated regarding pathology that was not visible in the image/video clips provided.

Thank you for this referral. If the clinical or image interpretation does not parallel your findings or if I can be of any further assistance please contact me.

Eric Lindquist, DMV, DABVP, Cert. IVUSS, CEO of SonoPath.com



PATIENT

Info@SonoPath.com

Reese Luciano

SPECIES

Canine

BREED

Terrier Mix

SEX

Spayed female

AGE

12 years

WEIGHT

51.4 lbs

INTERPRETED BY

Eric Lindquist, DMV,
DABVP, Cert. IVUSS,
CEO of SonoPath.com

**IMAGING
PERFORMED BY**

Kelly Vazquez, CVT

HOSPITAL NAME

Hillsdale AH

REFERRING VET

Dr. Fischer

INVOICE

43646

DATE

3/30/23