



**PATIENT PRESENTING CLINICAL SIGNS**

Kobe Lungu History: Bloat

**SPECIES ULTRASONOGRAPHIC EXAMINATION**

Canine

**Gastrointestinal**

**BREED**

The **gastrointestinal tract** revealed severe gastric dilation and air interference. The pylorus was not overtly visualized.

Labrador Retriever

**ULTRASONOGRAPHIC FINDINGS**

**SEX**

Given the radiographic presentation gastric bloat/partial volvulus is suspected.

Neutered male

**INTERPRETATION OF THE FINDINGS & FURTHER RECOMMENDATIONS**

**AGE**

If the patient is stable then gastric tubing, gastric decompression and IV fluid support can be considered. Recheck sonogram is recommended. No comorbidity was noted.

13 years

**WEIGHT**

77.4 lbs

**INTERPRETED BY**

Eric Lindquist, DMV  
DABVP, Cert. IVUSS

**IMAGING PERFORMED BY**

Valeryia Shumskaya

**HOSPITAL NAME**

North Haledon VC

**REFERRING VET**

Dr. Mansfield

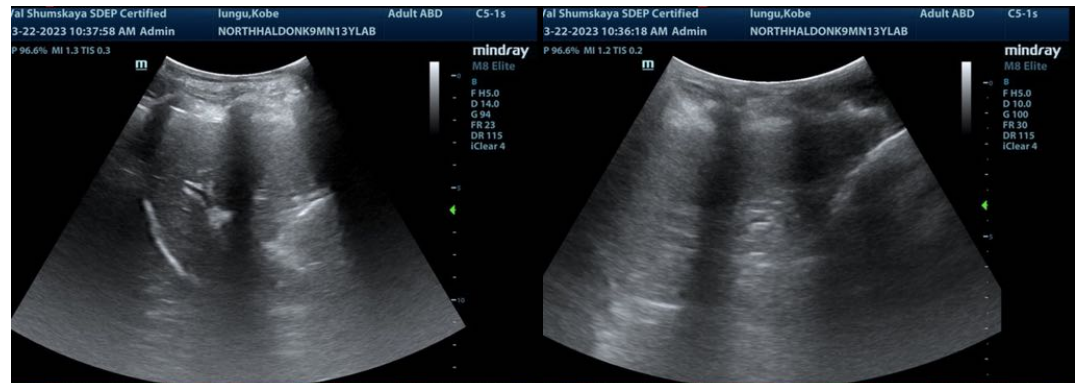
**INVOICE**

43424

Eric Lindquist, DMV, DABVP, Cert. IVUSS  
info@SonoPath.com

**DATE**

3/22/23



The information and recommendations provided are based on the images presented by the referring veterinarian/sonographer. No evaluation can be communicated regarding pathology that was not visible in the image/video clips provided.

Thank you for this referral. If the clinical or image interpretation does not parallel your findings or if I can be of any further assistance please contact me.