

**PATIENT PRESENTING CLINICAL SIGNS**

**PATIENT**  
Kobe Signoretti  
The patient has a heart murmur and occasional cough.

**SPECIES ULTRASONOGRAPHIC EXAMINATION OF THE ABDOMEN**

**SPECIES**  
Canine  
The echocardiogram in this patient demonstrated normal **left atrial** size based on 3 different LA measurement methods. Chamber volumes and echogenicity were normal. The cranial and caudal **mitral** valve leaflets presented vegetative thickening consistent with endocardiosis. Doppler indicated measurable insufficiency. The **left ventricle** presented thicknesses with linear contour and was not dilated nor restricted. The **myocardium** presented normal echogenicity without subjective evidence of significant fibrotic or ischemic disease. **Contractility** of the ventricular walls was adequate and in normal range for this patient evidenced by the fractional shortening measurement and subjective evaluation of the different regions of the myocardium. The **left ventricular outflow** tract demonstrated normal laminar flow and subjective structural integrity. The **right atrium** and auricle revealed normal size, structure and content. No evidence of masses was noted or chamber overload. **Tricuspid** valvular assessment demonstrated adequate linear morphology. The **right ventricle** was of normal size (1/3 diameter of LV), chordae structure, myocardial echogenicity and thickness. **Pulmonic** tract assessment revealed normal valve structure, laminar flow, and diameter (approx. 1:1 pa/ao ratio). No visible **pericardial** or free pleura fluid was noted. No echographically detectable evidence of infiltrative disease was visible. The cranial **mediastinum and pericardial regions** were free of masses in the visible window. An arrhythmia was noted, likely sinus arrhythmia.

**BREED**  
Shih Tzu

**SEX**  
Neutered male

**AGE**  
12 years

**INTERPRETED BY**

Eric Lindquist, DMV  
DABVP, Cert. IVUSS

**IMAGING PERFORMED BY**

Eric Lindquist, DMV  
DABVP, Cert. IVUSS

**HOSPITAL NAME**

Greenwood Lake AH

**REFERRING VET**

Dr. Price

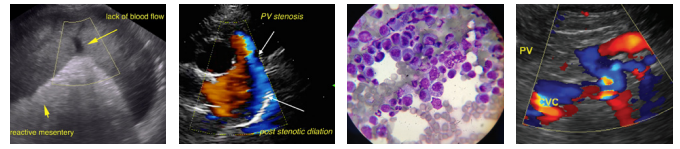
**INVOICE**

43408

**DATE**

3/21/23

CANINE CARDIAC PARAMETERS	MR VMAX (m/s)	TR VMAX (m/s)	LA/AO (Boon method)	LA/AO (Heart Base)	FS (%)	EF (%)	EPSS (cm)
NORMAL PARAMETER	4.5-5.5	<2.7	1.3	<1.6	28-40	40-100	<0.6
PATIENT	5.93		1.2	1.2	65	94	NM
CANINE CARDIAC PARAMETERS	HR (BPM)	AV VMAX (m/s)	PV MAX (m/s)	BODY WEIGHT (kg)	LA 2D short axis Base view (cm)	LVIDd Avg; 2D and m-mode short axis (cm)	LVIDs Avg; 2D and m-mode short axis (cm)
NORMAL PARAMETER	50-100	0.7-1.7	0.7-1.6	BELOW	BELOW	BELOW	BELOW
PATIENT	103	1.7	0.95		2.6	2.29	



**PATIENT**

Kobe Signoretti

**ULTRASONOGRAPHIC FINDINGS**

Stage B1 valvular disease.

**SPECIES**

Canine

**INTERPRETATION OF THE FINDINGS & FURTHER RECOMMENDATIONS**

EKG Is recommended to confirm arrhythmia. The cough is non-cardiogenic. Primary respiratory protocol is recommended.

**BREED**

Shih Tzu

**SEX**

Neutered male

**AGE**

12 years

**INTERPRETED BY**

Eric Lindquist, DMV DABVP, Cert. IVUSS

**IMAGING PERFORMED BY**

Eric Lindquist, DMV DABVP, Cert. IVUSS

**HOSPITAL NAME**

Greenwood Lake AH

**REFERRING VET**

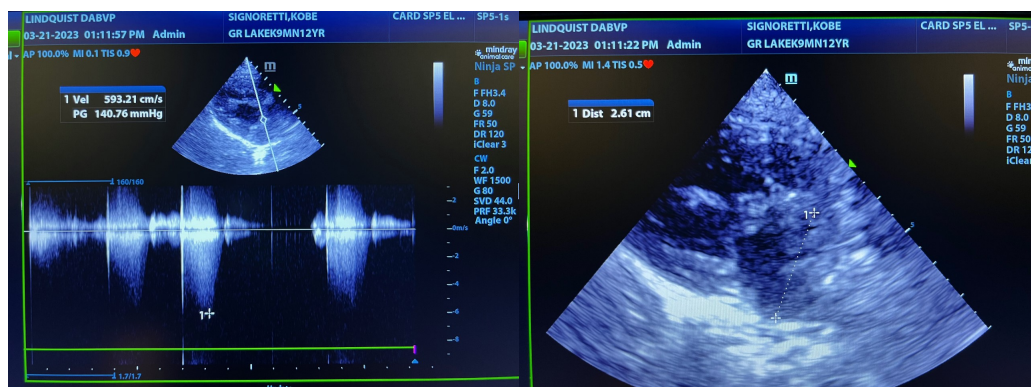
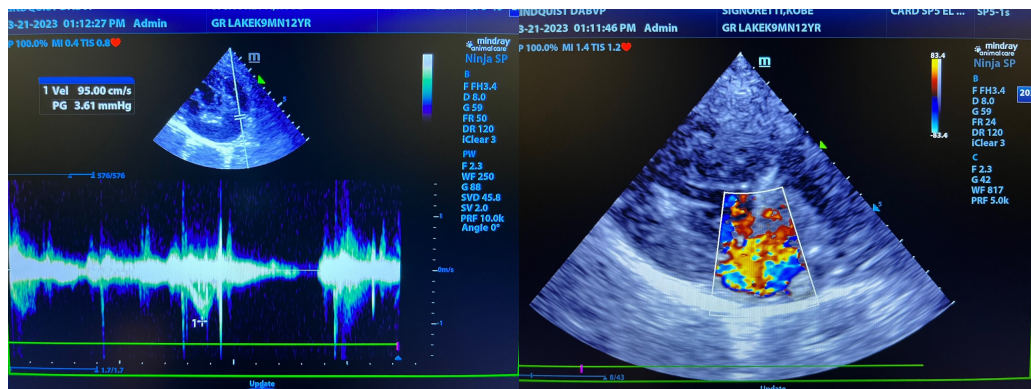
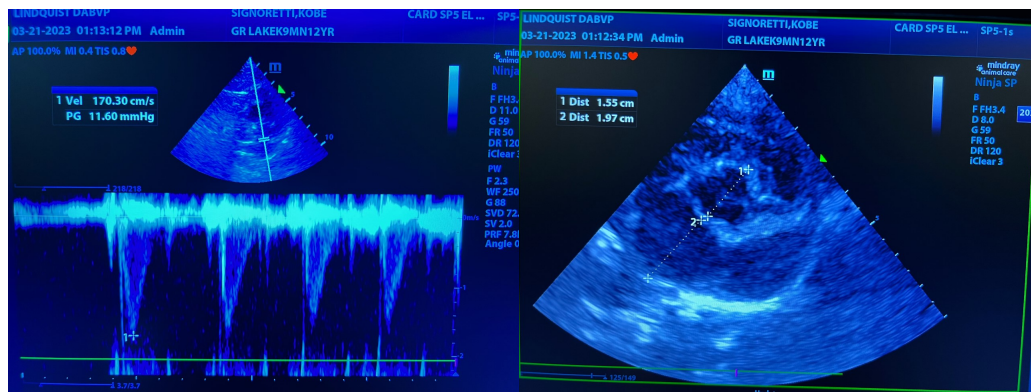
Dr. Price

**INVOICE**

43408

**DATE**

3/21/23





## PATIENT

Kobe Signoretti

## SPECIES

Canine

## BREED

Shih Tzu

## SEX

Neutered male

## AGE

12 years

## INTERPRETED BY

Eric Lindquist, DMV  
DABVP, Cert. IVUSS

## IMAGING PERFORMED BY

Eric Lindquist, DMV  
DABVP, Cert. IVUSS

## HOSPITAL NAME

Greenwood Lake AH

## REFERRING VET

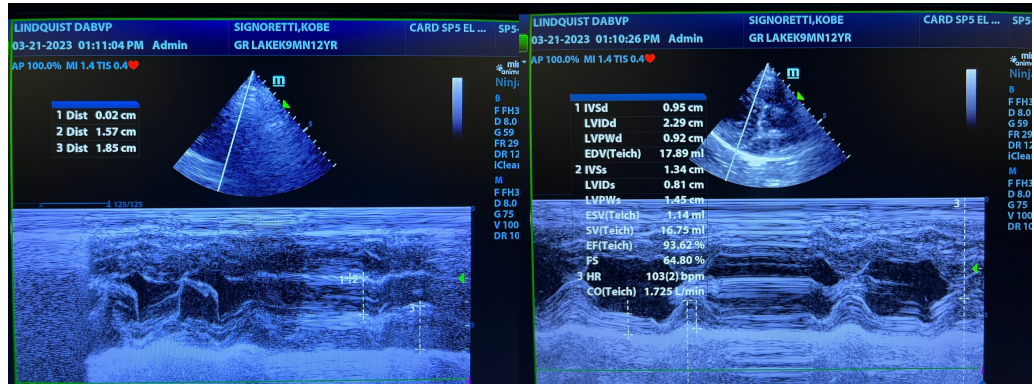Dr. Price

## INVOICE

43408

## DATE

3/21/23



The information and recommendations provided are based on the images presented by the referring veterinarian/sonographer. No evaluation can be communicated regarding pathology that was not visible in the image/video clips provided.

Thank you for this referral. If the clinical or image interpretation does not parallel your findings or if I can be of any further assistance please contact me.

**Eric Lindquist**, DMV, DABVP, Cert. IVUSS, CEO of SonoPath.com  
Info@SonoPath.com