

PATIENT

Scooter Centrelli

PRESENTING CLINICAL SIGNS

History: Additional images of PA/ deep PA to add to initial report to determine if PDA is present.

SPECIES

Feline

ULTRASONOGRAPHIC EXAMINATION

Upon further imaging of this patient holosystolic flow was noted in the deep pulmonary artery. This is consistent with patent ductus arteriosus. Pulmonary artery dilation was noted with secondary pulmonic insufficiency.

BREED

Domestic Shorthair

ULTRASONOGRAPHIC FINDINGS

Consistent with patent ductus arteriosus.

SEX

Neutered male

INTERPRETATION OF THE FINDINGS & FURTHER RECOMMENDATIONS

Given the volume of overload in the left heart and the PDA I recommend off label Pimobendan can be considered if not already being utilized at 0.3 mg/kg bi.d. Target respiratory rate should be less than 25/minute. Blood pressure measurements are warranted. Referral to interventional cardiologist for potential surgical correction would be appropriate. It is likely that the defect has gotten larger over time and is now more visible then on the prior echocardiograms as the volume overload has progressed. Medical management may be adequate in this patient given the age of the patient.

INTERPRETED BY

Eric Lindquist, DMV,
DABVP, Cert. IVUSS,
CEO of SonoPath.com

IMAGING PERFORMED BY

Kelly Vazquez, CVT

HOSPITAL NAME

The Gentle Vet

REFERRING VET

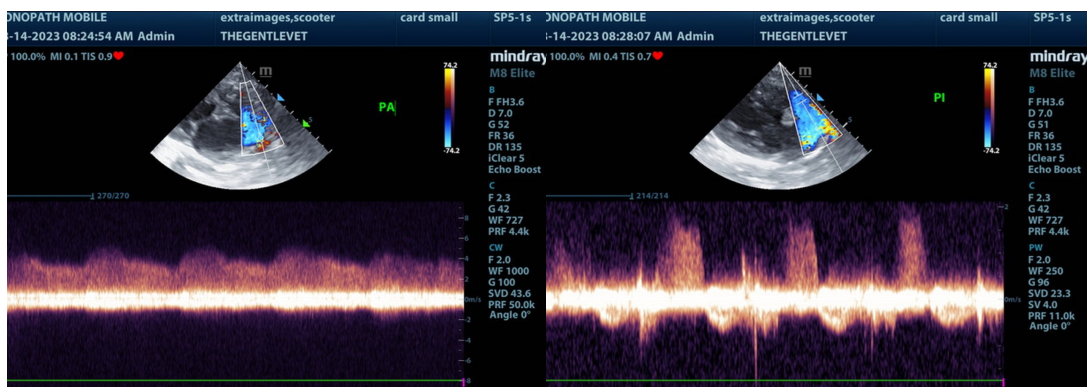
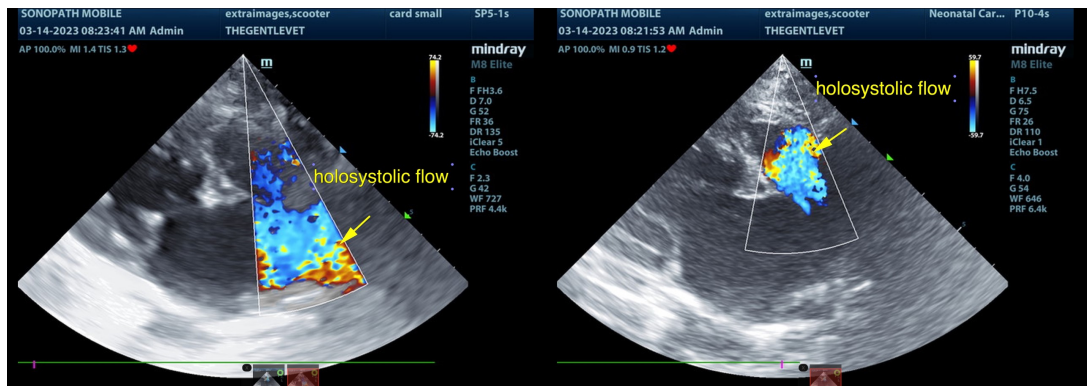
Dr. Dulude

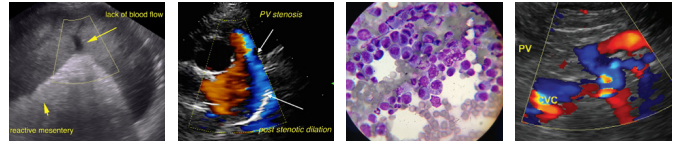
INVOICE

43293

DATE

3/14/23





PATIENT

Scooter Centrelli

SPECIES

Feline

BREED

Domestic Shorthair

SEX

Neutered male

AGE

9 years

WEIGHT

13 lbs

INTERPRETED BY

Eric Lindquist, DMV,
DABVP, Cert. IVUSS,
CEO of SonoPath.com

**IMAGING
PERFORMED BY**

Kelly Vazquez, CVT

HOSPITAL NAME

The Gentle Vet

REFERRING VET

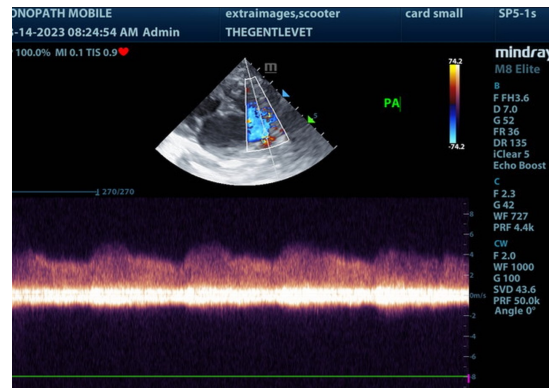
Dr. Dulude

INVOICE

43293

DATE

3/14/23



The information and recommendations provided are based on the images presented by the referring veterinarian/sonographer. No evaluation can be communicated regarding pathology that was not visible in the image/video clips provided.

Thank you for this referral. If the clinical or image interpretation does not parallel your findings or if I can be of any further assistance please contact me.

Eric Lindquist, DMV, DABVP, Cert. IVUSS, CEO of SonoPath.com

Info@SonoPath.com