

**PATIENT PRESENTING CLINICAL SIGNS**

Atlas Schulz

History: grade 4/6 murmur noted on PE 3/8/23; assess for anesthesia for dental procedure. not on any meds.

**SPECIES**

Abnormal PE/Chem/CBC/UA Results: platelet count low

Feline

**BREED**

Maine Coon Mix

**SEX**

Neutered male

**AGE**

7 years

**WEIGHT**

17.6 lbs

**INTERPRETED BY**

Eric Lindquist, DMV  
DABVP, Cert. IVUSS

**IMAGING PERFORMED BY**

Diane McFadden, RVT

**HOSPITAL NAME**

Denville AH

**REFERRING VET**

Dr. Reddy

**INVOICE**

43258

**DATE**

3/10/23

**ULTRASONOGRAPHIC EXAMINATION OF THE HEART**

The echocardiogram in this patient demonstrated normal **left atrial** size based on 3 separate LA measurements. **Mitral** insufficiency was noted on spectral Doppler. The **left ventricle** presented normal thicknesses with linear contour and was not dilated nor restricted. The **myocardium** presented normal echogenicity without subjective evidence of significant fibrotic or ischemic disease. **Contractility** of the ventricular walls was adequate and in normal range for this patient evidenced by the fractional shortening measurement and subjective evaluation of the different regions and angles of the myocardium. The **left ventricular outflow** tract demonstrated normal laminar flow and subjective structural integrity. The **right atrium** and auricle revealed normal size, structure and content. No evidence of masses was noted or chamber overload. **Tricuspid** valvular assessment demonstrated adequate linear morphology and kinetics. The **right ventricle** was of normal size (1/3 diameter of LV), chordae structure, myocardial echogenicity and thickness. **Pulmonic** tract assessment revealed normal valve structure, laminar flow, and diameter (approx. 1:1 pa/ao ratio). No visible **pericardial** or free pleura fluid was noted or extra cardiac pathology in the visible planes. The cranial **mediastinum and pericardial regions** were free of masses in the visible window.

FELINE CARDIAC PARAMETERS	BODY WEIGHT	HR (BPM)	IVSd (cm)	LVIDd (cm)	LVWd (cm)	FS (%)	EF (%)
NORMAL PARAMETER	-----	150-240	0.3-0.6	1.0-2.1	0.25-0.6	35-67	80-100
PATIENT	17.6 lbs	127	0.55	1.89	0.58	25	53
FELINE CARDIAC PARAMETERS	LA/AO (Boon)	LA/AO HEART BASE (Sisson)	LA 2D 4-chamber long axis AS to FW (Sisson) (cm)	LVOT VEL. (m/s)	RVOT VEL. (m/s)	IVRT (m/)	
NORMAL PARAMETER	<1.5	0.88-1.79	0.7-1.7	<1.6	<1.3	40-60	
PATIENT	1.0	1.3	1.4	1.0	0.6	NM	
Adapted from June Boon, Veterinary Echocardiography, 1998 Sisson D et al. JVIM 1991; 5: 232, Jacobs et al. Am J Vet Res 1985; 46:1705							



**PATIENT**

Atlas Schulze

**SPECIES**

Feline

**BREED**

Maine Coon Mix

**SEX**

Neutered male

**AGE**

7 years

**WEIGHT**

17.6 lbs

**INTERPRETED BY**

Eric Lindquist, DMV  
DABVP, Cert. IVUSS

**IMAGING PERFORMED BY**

Diane McFadden, RVT

**HOSPITAL NAME**

Denville AH

**REFERRING VET**

Dr. Reddy

**INVOICE**

43258

**DATE**

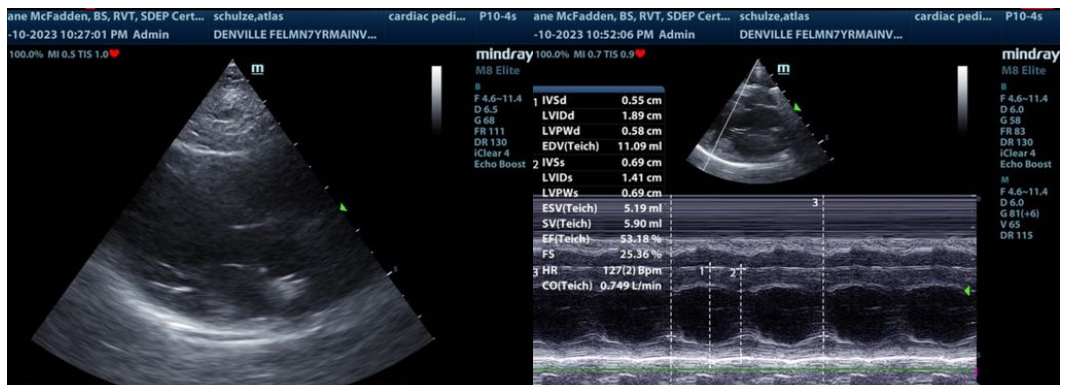
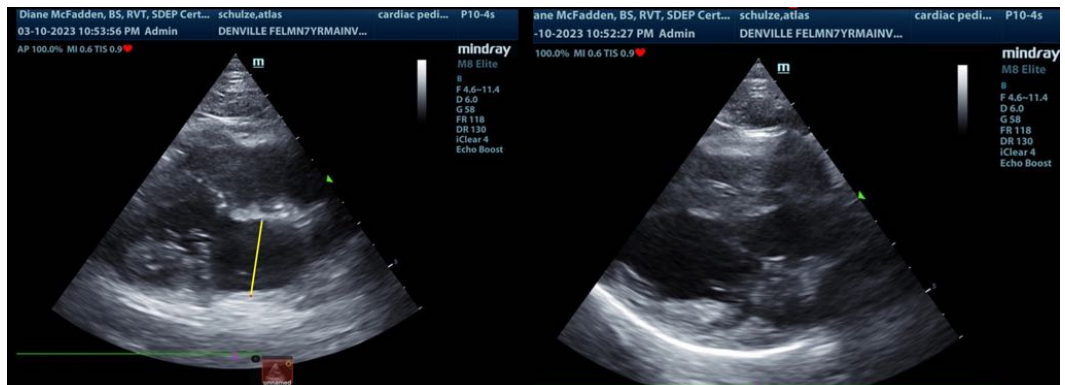
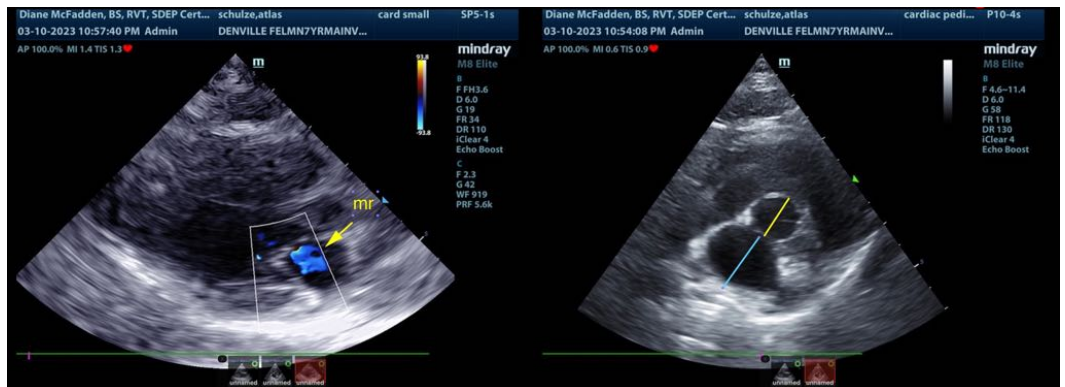
3/10/23

**ULTRASONOGRAPHIC FINDINGS**

Minor mitral insufficiency.  
Structurally and functionally normal heart.

**INTERPRETATION OF THE FINDINGS & FURTHER RECOMMENDATIONS**

There is no contraindication to anesthetic procedure. Recheck echocardiogram is recommended in a year.





**PATIENT**

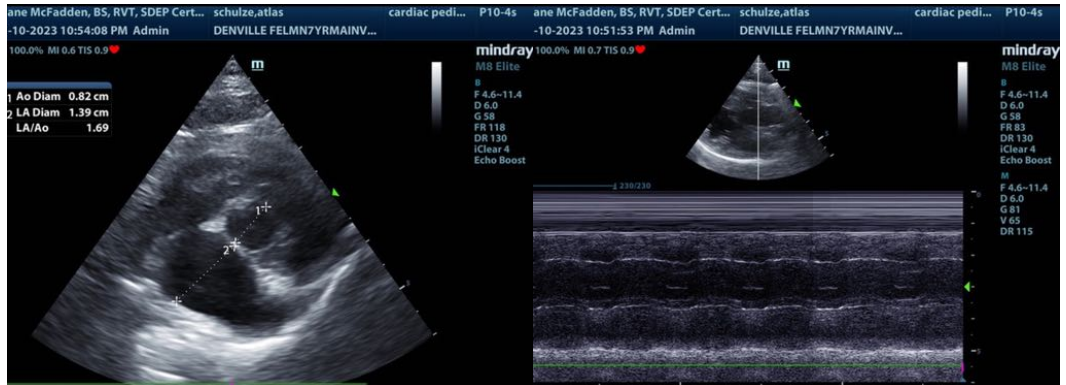
Atlas Schulz

**SPECIES**

Feline

**BREED**

Maine Coon Mix



**SEX**

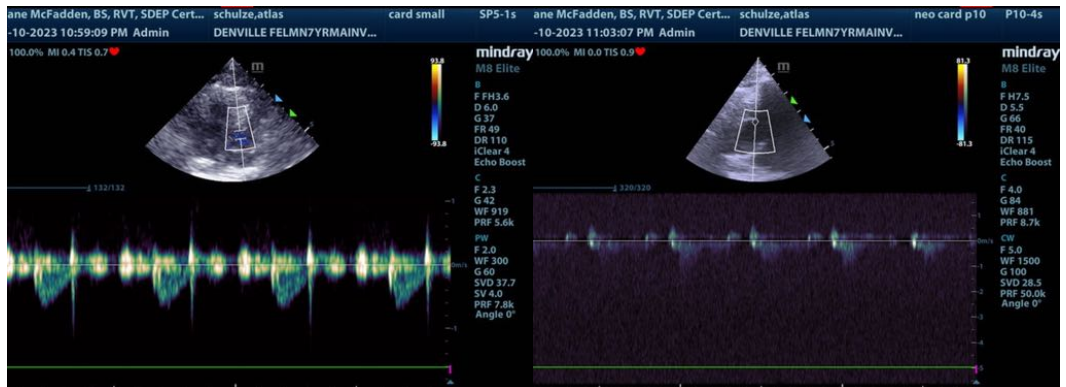
Neutered male

**AGE**

7 years

**WEIGHT**

17.6 lbs



**INTERPRETED BY**

Eric Lindquist, DMV  
DABVP, Cert. IVUSS

**IMAGING PERFORMED BY**

Diane McFadden, RVT

**HOSPITAL NAME**

Denville AH

**REFERRING VET**

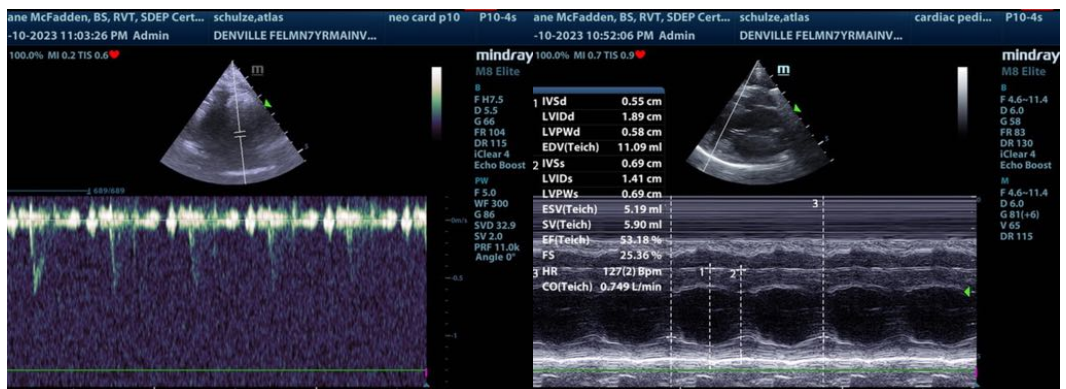
Dr. Reddy

**INVOICE**

43258

**DATE**

3/10/23



The information and recommendations provided are based on the images presented by the referring veterinarian/sonographer. No evaluation can be communicated regarding pathology that was not visible in the image/video clips provided.

Thank you for this referral. If the clinical or image interpretation does not parallel your findings or if I can be of any further assistance please contact me.

**Eric Lindquist, DMV, DABVP, Cert. IVUSS, CEO of SonoPath.com**  
Info@SonoPath.com