



**PATIENT**

Jack Wrede

**PRESENTING CLINICAL SIGNS**

History: Chronic diarrhea, very uncomfortable w/o metro, ALT trendy upwards  
Abnormal PE/Chem/CBC/UA Results: 1/17/23 ALT 207, 2/1/22 ALT 123 UA: 2+ protein, 2/1/22 Protein 2+ SG: 1.057

**SPECIES**

Feline

**ULTRASONOGRAPHIC EXAMINATION OF THE ABDOMEN**

**Urinary System**

The **urinary bladder**, trigone, and pelvic urethra presented normal thicknesses and normal tone. The ureters were not visible which is normal. No uroliths or sediment were visualized and anechoic urine was present. No evidence of inflammatory or neoplastic changes was noted. Ureteral papillae were normal.

**BREED**

Domestic Longhair

**SEX**

Neutered male

The **kidneys** revealed normal size and structure, corticomedullary definition and ratio for this age. The cortices presented largely uniform texture with normal echogenic relationship to liver and spleen. Medullary structure differed distinctly from the cortex and no evidence of pelvic dilation was present. The capsules were acceptably uniform without significant irregularities. The right kidney measured 5.0 cm. The left kidney measured 4.34 cm.

**AGE**

13 ½ years

**Adrenal Glands**

Both **adrenal glands** were visualized and recognized as having normal shape, size, position and echogenicity for this breed. The phrenic vasculature, glandular echogenicity and detail were unremarkable. Capsule, cortex, and medullary definition were normal for this age patient. The left adrenal gland measured 0.48 cm. The right adrenal gland measured 0.33 cm.

**WEIGHT**

13.4 lbs

**INTERPRETED BY**

Eric Lindquist, DMV  
DABVP, Cert. IVUSS

**Spleen**

The **spleen** presented a smooth homogeneous parenchyma hyperechoic to liver and renal cortical parenchyma. The capsule was smooth without noticeable expansion or deviation from within the spleen or adjacent pathology. The splenic vasculature demonstrated normal volume without signs of congestion or thrombosis. No sonographic evidence of acute or chronic inflammatory, neoplastic, or infarctual changes was noted.

**IMAGING PERFORMED BY**

Valeryia Shumskaya

**HOSPITAL NAME**

Ramapo Valley AH

**Liver**

The **liver** images submitted revealed subjectively normal liver size, contour, and structure. Parenchymal echogenicity was naturally coarse and hypoechoic to the spleen. Vascular and biliary tracts were of normal volume with no evidence of congestion. The gallbladder presented acceptably thin walls with primarily anechoic content. The cystic and common bile ducts were normal. No pathological hepatic lymphadenopathy was evident. No overt structural evidence of inflammatory, infiltrative or regenerative pathology was evident.

**REFERRING VET**

Dr. Katara

**INVOICE**

43048

**DATE**

3/1/23



**PATIENT**

**Gastrointestinal**

Jack Wrede

The **gastrointestinal** presentation revealed mild uniform prominence of the gastric mucosa as well as areas of "ropey" small intestinal wall with slight disruption of the normal 1:3 muscularis/mucosal ratio. The intestinal submucosa was slightly irregular, thickened and hyperechoic suggestive of low grade, chronic disease. No concerning lymphadenopathy was visible. No evidence of obstruction was present. Chronic inflammatory bowel disease is likely with a low possibility of an early neoplastic event such as lymphoma. Full thickness tissue biopsies via open laparotomy, ideally guided by intraoperative ultrasound in order to obtain the most representative mural sample, would be necessary to rule out this possibility.

**SPECIES**

Feline

**BREED**

Domestic Longhair

**SEX**

Neutered male

**Pancreas**

The base and limbs of the **pancreas** were observed to be largely isoechoic to surrounding omental fat. Pancreatic duct and capsular contour were acceptably normal and parenchyma respected normal curvilinear patterns. No overt evidence of active inflammatory or neoplastic disease was noted.

**AGE**

13 ½ years

**Free Abdomen**

A large amount of falciform fat was noted.

**WEIGHT**

13.4 lbs

**ULTRASONOGRAPHIC FINDINGS**

Minor intestinal thickening, structurally normal liver. Likely inflammatory bowel with reactive hepatopathy.

**INTERPRETED BY**

Eric Lindquist, DMV  
DABVP, Cert. IVUSS

**INTERPRETATION OF THE FINDINGS & FURTHER RECOMMENDATIONS**

**IMAGING PERFORMED BY**

Valeryia Shumskaya

The hepatic clinical sonographic presentation is most consistent with Reactive Hepatopathy which is the most common cause of liver enzyme elevation in dogs and cats. The presumption is that gut and other organ antigen stimuli may be causing a low-grade immune response through portal system with which the liver is reacting to causing low-grade enzyme elevations. US-guided FNA could be performed to assess if low grade lymphoplasmacytic inflammation is present that would support this theory. If FNA is performed, please ask the cytologist to emphasize the primary inflammatory cell type. Empirical treatment measures to address this issue can include diet change to hydrolyzed diet, probiotics, deworming, nutraceuticals (SAME, Actigall...), dental exam and cleaning, and potentially antibiotics such as Clavamox. Metronidazole and Tylosin have traditionally been utilized for this purpose but new studies show that both these antibiotics can disrupt the normal intestinal bacterial flora (intestinal dysbiosis) for weeks and up to 4-6 months. Therefore, Metronidazole and Tylosin should be utilized as a last resort if other efforts have not been effective and sonographic organ appearance remains benign.

**HOSPITAL NAME**

Ramapo Valley AH

**REFERRING VET**

Dr. Katara

**INVOICE**

43048

Change to hydrolyzed diet may be in this patient's best interest to reduce general antigenicity. FNA of the liver could be considered for further definition. Anti-parasitic protocol and a clinical trial of Zithromax and Metronidazole can also be considered. There was no evidence of neoplasia or foreign matter.

**DATE**

3/1/23



**PATIENT**

Jack Wrede

**SPECIES**

Feline

**BREED**

Domestic Longhair

**SEX**

Neutered male

**AGE**

13 ½ years

**WEIGHT**

13.4 lbs

**INTERPRETED BY**

Eric Lindquist, DMV  
DABVP, Cert. IVUSS

**IMAGING PERFORMED BY**

Valeryia Shumskaya

**HOSPITAL NAME**

Ramapo Valley AH

**REFERRING VET**

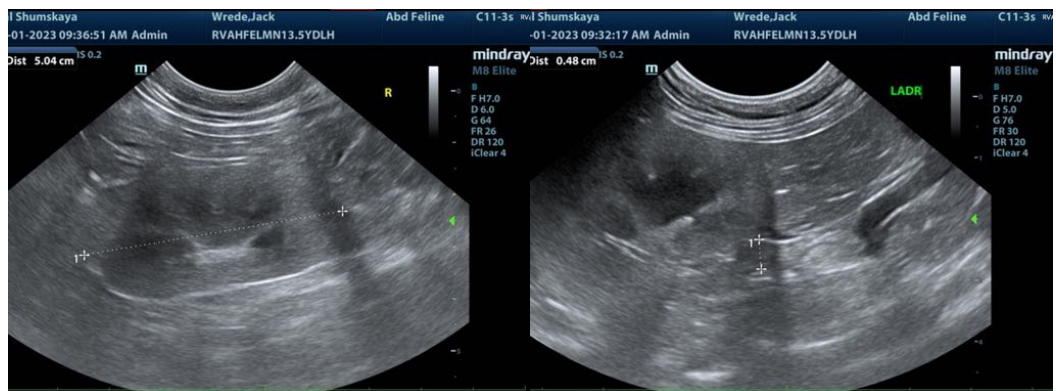
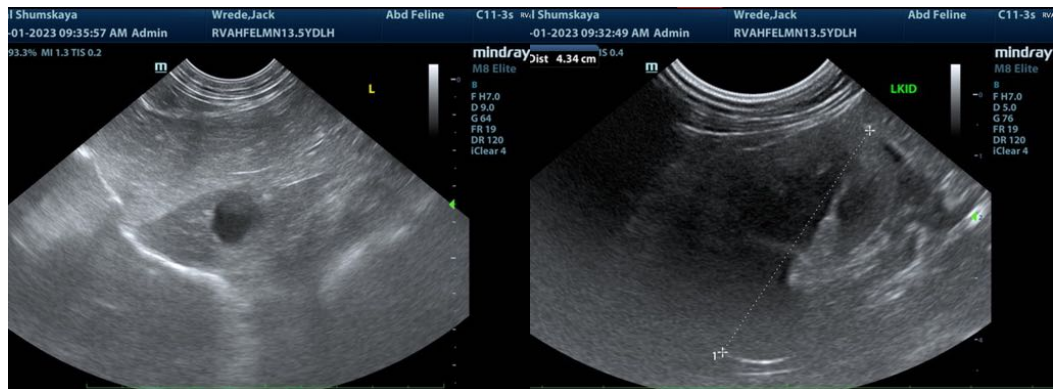
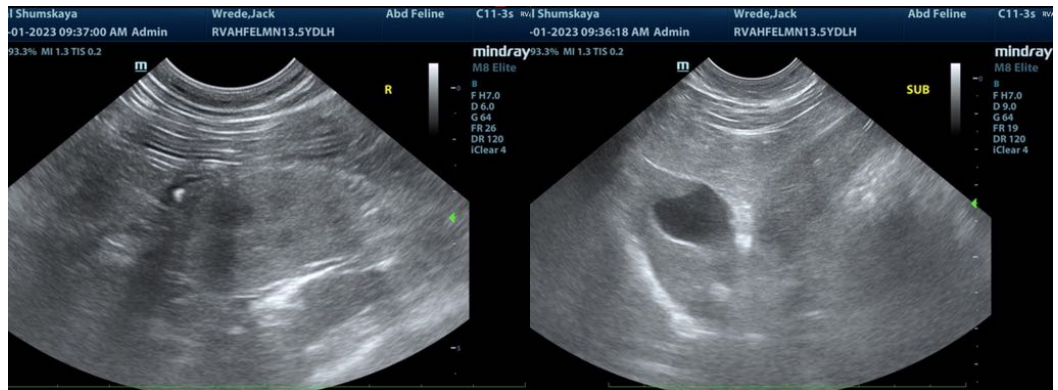
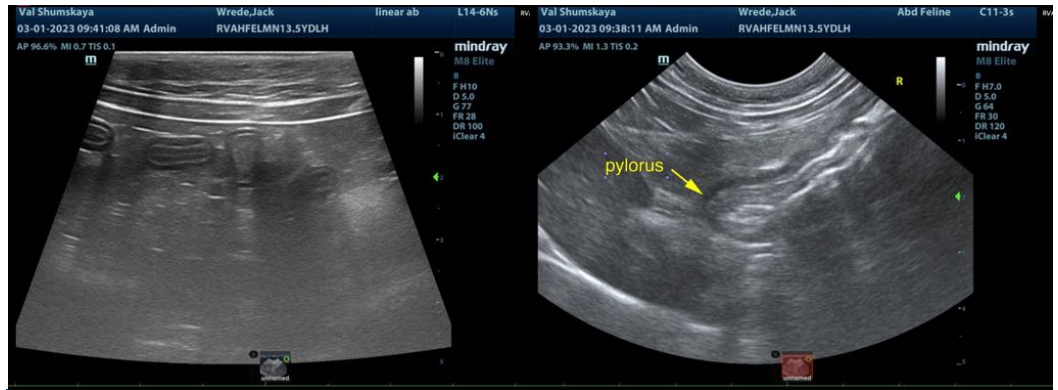
Dr. Katara

**INVOICE**

43048

**DATE**

3/1/23





**PATIENT**

Jack Wrede

The information and recommendations provided are based on the images presented by the referring veterinarian/sonographer. No evaluation can be communicated regarding pathology that was not visible in the image/video clips provided.

**SPECIES**

Feline

Thank you for this referral. If the clinical or image interpretation does not parallel your findings or if I can be of any further assistance please contact me.

**BREED**

Domestic Longhair

Eric Lindquist, DMV, DABVP, Cert. IVUSS  
info@SonoPath.com

**SEX**

Neutered male

**AGE**

13 ½ years

**WEIGHT**

13.4 lbs

**INTERPRETED BY**

Eric Lindquist, DMV  
DABVP, Cert. IVUSS

**IMAGING  
PERFORMED BY**

Valeryia Shumskaya

**HOSPITAL NAME**

Ramapo Valley AH

**REFERRING VET**

Dr. Katara

**INVOICE**

43048

**DATE**

3/1/23