



PATIENT PRESENTING CLINICAL SIGNS

Finn Miller History: polydipsia, behavior change around food - more aggressive. eats over 4 cups a day- stomach distension; hyper.
Abnormal PE/Chem/CBC/UA Results: UPC wnl

SPECIES

Canine

BREED

Pembroke Welsh Corgi

SEX

Neutered male

AGE

6 years

WEIGHT

39 lbs

INTERPRETED BY

Eric Lindquist, DMV
DABVP, Cert. IVUSS

IMAGING PERFORMED BY

Diane McFadden, RVT

HOSPITAL NAME

Animal Care Center of
Flanders

REFERRING VET

Dr. Hallihan

INVOICE

43025

DATE

2/28/23

ULTRASONOGRAPHIC EXAMINATION OF THE ABDOMEN
Urinary System

The **urinary bladder**, trigone, and pelvic urethra presented normal thicknesses and normal tone. The ureters were not visible which is normal. No uroliths or sediment were visualized and anechoic urine was present. No evidence of inflammatory or neoplastic changes was noted. Ureteral papillae were normal.

The residual prostate measured 0.5 cm.

The **kidneys** revealed normal size and structure, corticomedullary definition and ratio for this age. The cortices presented largely uniform texture with normal echogenic relationship to liver and spleen. Medullary structure differed distinctly from the cortex and no evidence of pelvic dilation was present. The capsules were acceptably uniform without significant irregularities. The right kidney measured 5.74 cm. The left kidney measured 4.81 cm.

Adrenal Glands

Both **adrenal glands** were visualized and recognized as having normal shape, size, position and echogenicity for this breed. The phrenic vasculature, glandular echogenicity and detail were unremarkable. Capsule, cortex, and medullary definition were normal for this age patient. The left adrenal gland measured 2.0 x 0.59 cm at the caudal pole and 0.48 cm at the cranial pole. The right adrenal gland measured 2.19 x 0.55 cm at the caudal pole and 0.3 cm at the cranial pole.

Spleen

The **spleen** presented a smooth homogeneous parenchyma hyperechoic to liver and renal cortical parenchyma. The capsule was smooth without noticeable expansion or deviation from within the spleen or adjacent pathology. The splenic vasculature demonstrated normal volume without signs of congestion or thrombosis. No sonographic evidence of acute or chronic inflammatory, neoplastic, or infarctual changes was noted.

Liver

The **liver** revealed slight coarse architecture and mildly increased portal markings. The gallbladder and common bile duct were unremarkable.

Gastrointestinal

Examination of the **gastrointestinal tract** revealed a stomach and intestine free of stasis, of normal wall thickness, acceptable curvilinear mural detail, and peristaltic activity. Small and large intestine



PATIENT Finn Miller demonstrated normal luminal chyme and stool consistency respectively. No obstructive or overt infiltrative disease was noted. No associated abnormal lymphatic activity was noted.

SPECIES *Pancreas*

Canine The base and limbs of the **pancreas** were observed to be largely isoechoic to surrounding omental fat. Pancreatic duct and capsular contour were acceptably normal and parenchyma respected normal curvilinear patterns. No overt evidence of active inflammatory or neoplastic disease was noted.

BREED

Pembroke Welsh Corgi

ULTRASONOGRAPHIC FINDINGS

SEX Minor hepatic remodeling.

Neutered male Otherwise, unremarkable abdomen.

AGE

6 years

INTERPRETATION OF THE FINDINGS & FURTHER RECOMMENDATIONS

WEIGHT

39 lbs

There was no evidence of abdominal disease responsible for the clinical signs. Causes of clinical signs such as CNS disease or orthopedic pain should be considered. Orthopedic pain should be considered. If any abnormal CNS signs are present then skull CT is indicated. If orthopedic pain is found then spinal or orthopedic CT would be appropriate.

ABOUT SONOPATH CT SERVICES:

SonoPath CT Services are offered at the SonoPath Imaging and Veterinary Education Center, 141 Main St (rt 206), Andover, New Jersey, a 20-minute drive west on route 80/206 North from the route 80/287 interchange/Parsippany, New Jersey. More information can be found at <https://sonopath.com/resources/sonopath-teleconsultation-services-and-sdep-certification/sonopath-ct-services>

INTERPRETED BY

Eric Lindquist, DMV DABVP, Cert. IVUSS

IMAGING PERFORMED BY

Diane McFadden, RVT

HOSPITAL NAME

Animal Care Center of Flanders

REFERRING VET

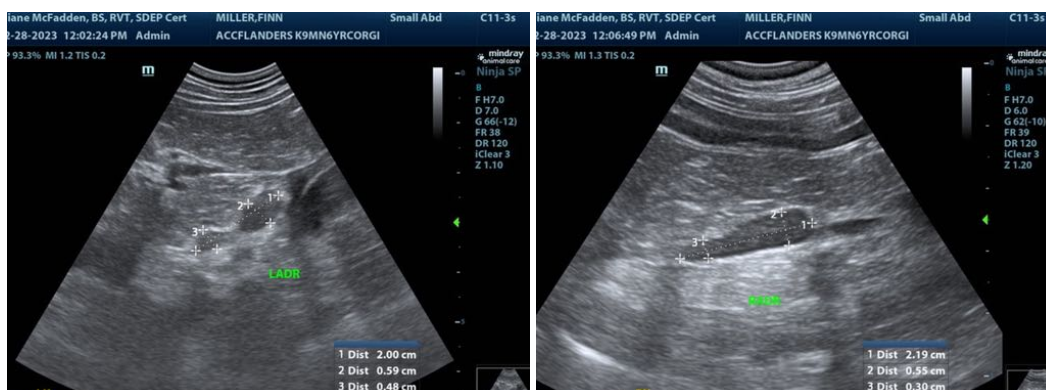
Dr. Hallihan

INVOICE

43025

DATE

2/28/23





PATIENT

Finn Miller

SPECIES

Canine

BREED

Pembroke Welsh Corgi

SEX

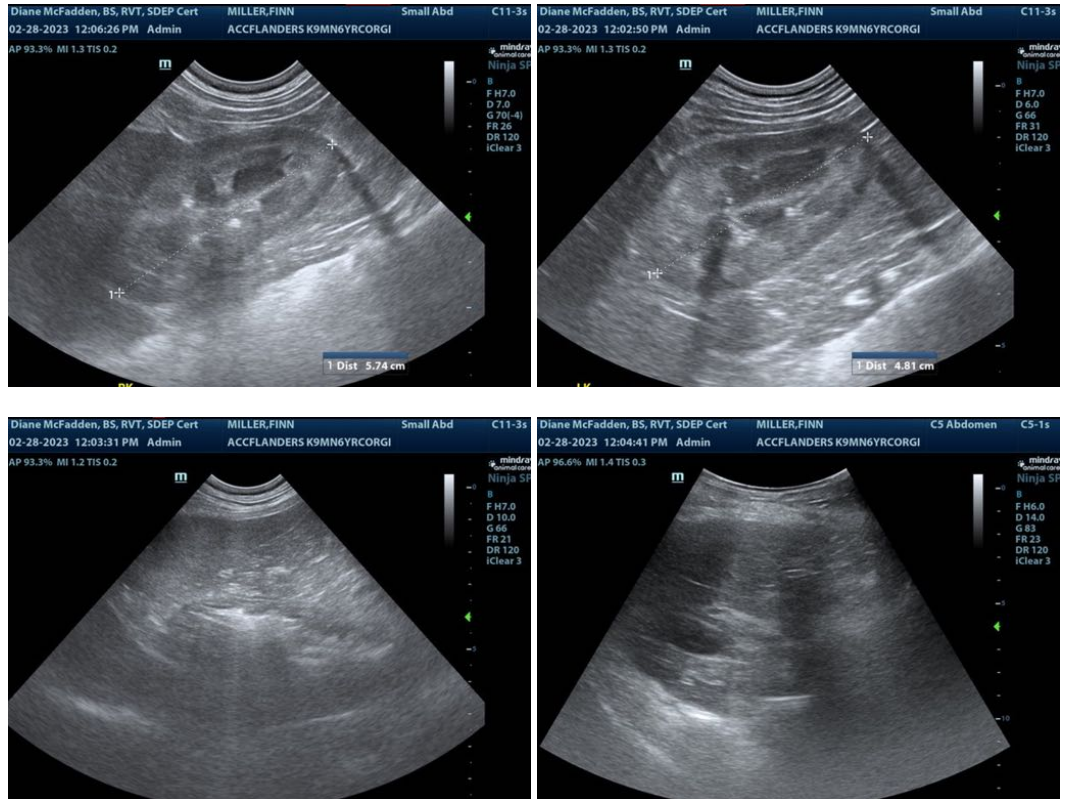
Neutered male

AGE

6 years

WEIGHT

39 lbs



INTERPRETED BY

Eric Lindquist, DMV
DABVP, Cert. IVUSS

IMAGING PERFORMED BY

Diane McFadden, RVT

HOSPITAL NAME

Animal Care Center of
Flanders

REFERRING VET

Dr. Hallihan

INVOICE

43025

DATE

2/28/23

The information and recommendations provided are based on the images presented by the referring veterinarian/sonographer. No evaluation can be communicated regarding pathology that was not visible in the image/video clips provided.

Thank you for this referral. If the clinical or image interpretation does not parallel your findings or if I can be of any further assistance please contact me.

Eric Lindquist, DMV, DABVP, Cert. IVUSS, CEO of SonoPath.com
Info@SonoPath.com