



PATIENT PRESENTING CLINICAL SIGNS

Inca Reiss History: Grade II/VI heart murmur, chronic cough, mild cardiomegaly. Current meds: Gabapentin, Theophylline, Carprofen prn, Probiotic.

SPECIES

Canine

ULTRASONOGRAPHIC EXAMINATION OF THE HEART

BREED

Labrador Retriever Mix

The echocardiogram in this patient demonstrated normal **left atrial** size based on 3 separate methods of LA evaluation. The cranial and caudal **mitral** valve leaflets presented normal linear structure, extension in systole, and union in diastole with normal kinesis. The **left ventricle** presented thicknesses with linear contour and was not dilated nor restricted. The **myocardium** presented normal echogenicity without subjective evidence of significant fibrotic or ischemic disease. **Contractility** of the ventricular walls was adequate and in normal range for this patient evidenced by the fractional shortening measurement and subjective evaluation of the different regions of the myocardium. The **left ventricular outflow** tract demonstrated normal laminar flow and subjective structural integrity. The **right atrium** and auricle revealed normal size, structure and content. No evidence of masses was noted. Trivial **tricuspid** insufficiency was noted. The **right ventricle** was of normal size (1/3 diameter of LV), chordae structure, myocardial echogenicity and thickness. **Pulmonary outflow** tract assessment revealed normal valve structure, laminar flow, and diameter (approx.1:1 pa/ao ratio). No visible **pericardial** or free pleura fluid was noted. The cranial **mediastinum and pericardial and extra-cardiac regions** were free of masses in the visible window. Occasional arrhythmia was noted in this patient.

SEX

Spayed female

AGE

13 years

WEIGHT

97.1 lbs

INTERPRETED BY

Eric Lindquist, DMV
DABVP, Cert. IVUSS

IMAGING PERFORMED BY

Shari Reffi, CVT

HOSPITAL NAME

Legacy AH

REFERRING VET

Dr. Pontenzone

CANINE CARDIAC PARAMETERS	MR VMAX (m/s)	TR VMAX (m/s)	LA/AO (Boon method)	LA/AO (Heart Base)	FS (%)	EF (%)	EPSS (cm)
NORMAL PARAMETER	4.5-5.5	<2.7	1.3	<1.6	28-40	40-100	<0.6
PATIENT		3.0	1.2		36	66	7.6
CANINE CARDIAC PARAMETERS	HR (BPM)	AV VMAX (m/s)	PV MAX (m/s)	BODY WEIGHT	LA 2D short axis Base view (cm)	LVIDd Avg; 2D and m- mode short axis (cm)	LVIDs Avg; 2D and m- mode short axis (cm)
NORMAL PARAMETER	50-100	0.7-1.7	0.7-1.6	BELOW	BELOW	BELOW	BELOW
PATIENT	116	1.46	0.98	97.1 lbs	4.38	3.84	

INVOICE

42990

DATE

2/27/23



PATIENT

Inca Reiss

ULTRASONOGRAPHIC FINDINGS

Essentially normal echocardiogram with minor tricuspid insufficiency. Early, non-clinical pulmonary hypertension and arrhythmia.

SPECIES

Canine

INTERPRETATION OF THE FINDINGS & FURTHER RECOMMENDATIONS

This is consistent with very early pulmonary hypertension. This is not a clinical issue at this time. This is likely secondary to primary respiratory disease. EKG or Holter monitor would be warranted. Holter monitor can be obtained from our office with cardiologist review. No cardiac medications are warranted at this time.

BREED

Labrador Retriever Mix

SEX

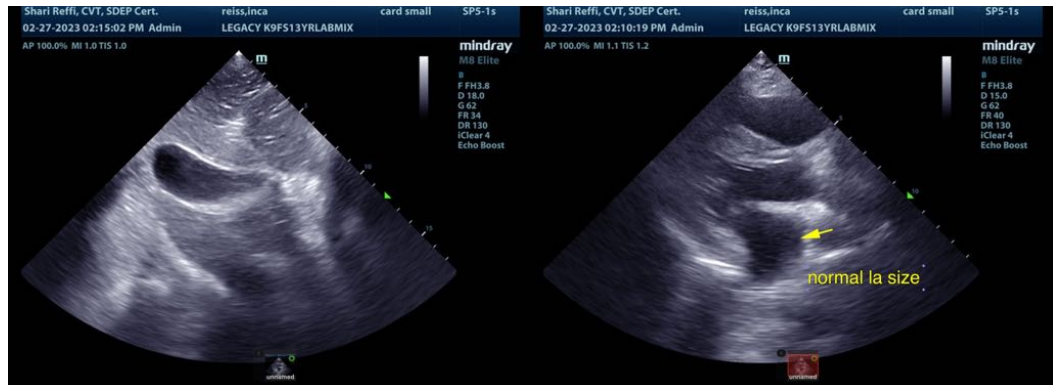
Spayed female

AGE

13 years

WEIGHT

97.1 lbs



INTERPRETED BY

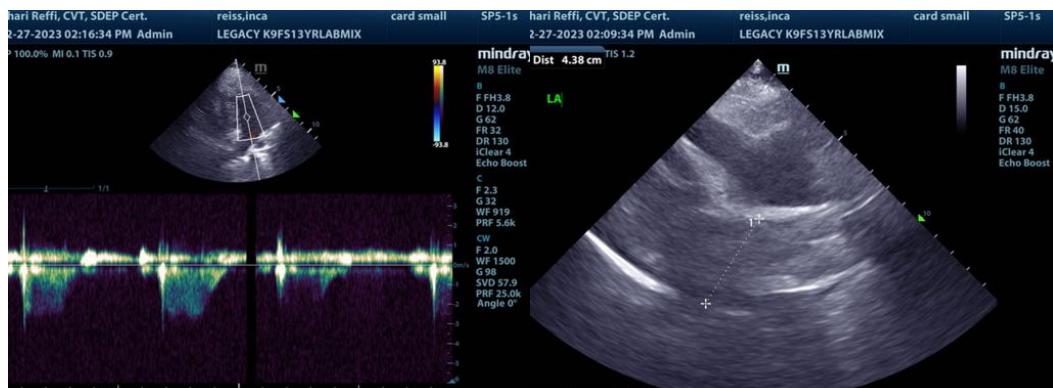
Eric Lindquist, DMV
DABVP, Cert. IVUSS

IMAGING PERFORMED BY

Shari Reffi, CVT

HOSPITAL NAME

Legacy AH



REFERRING VET

Dr. Pontenzone

INVOICE

42990

DATE

2/27/23



PATIENT

Inca Reiss

SPECIES

Canine

BREED

Labrador Retriever Mix

SEX

Spayed female

AGE

13 years

WEIGHT

97.1 lbs

INTERPRETED BY

Eric Lindquist, DMV
DABVP, Cert. IVUSS

IMAGING PERFORMED BY

Shari Reffi, CVT

HOSPITAL NAME

Legacy AH

REFERRING VET

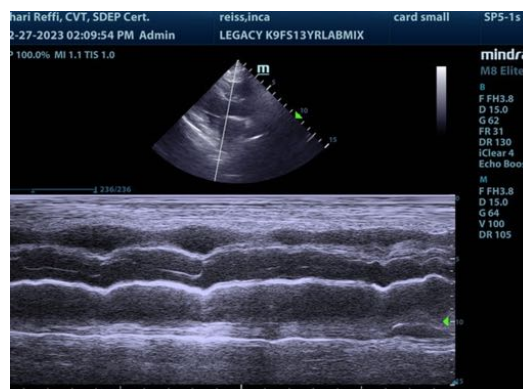
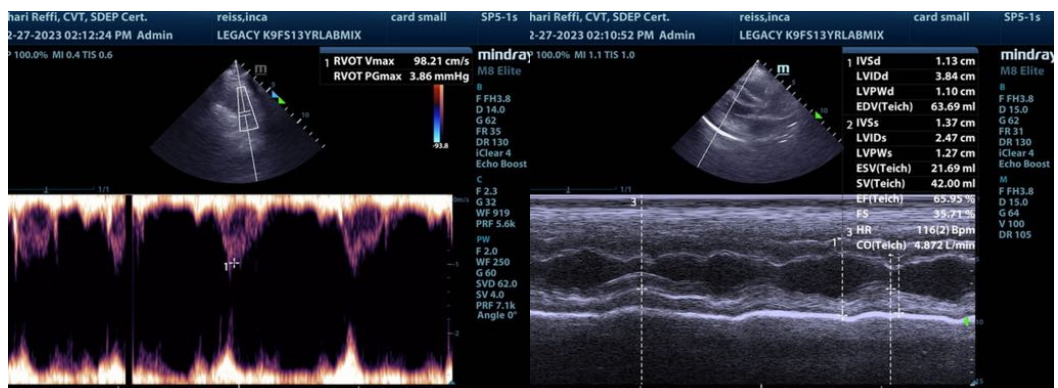
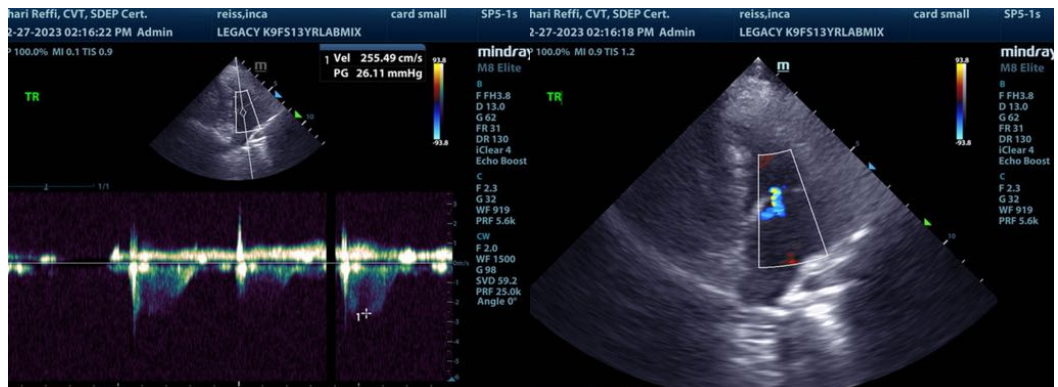
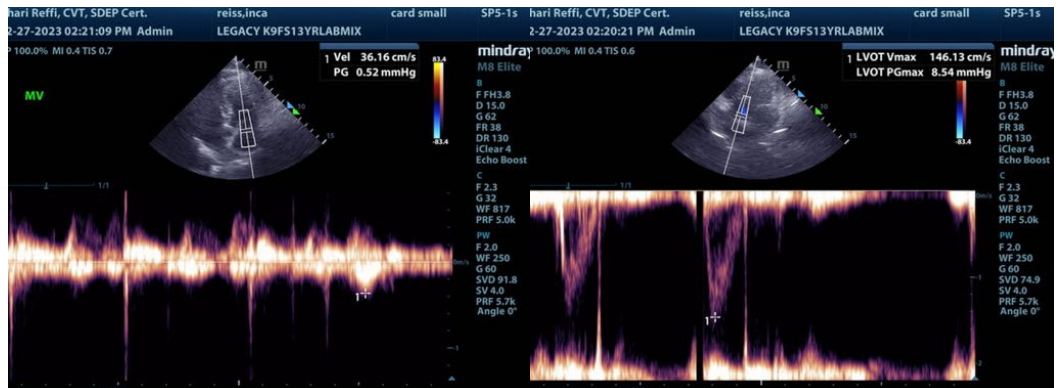
Dr. Pontenzone

INVOICE

42990

DATE

2/27/23





PATIENT

Inca Reiss

The information and recommendations provided are based on the images presented by the referring veterinarian/sonographer. No evaluation can be communicated regarding pathology that was not visible in the image/video clips provided.

SPECIES

Canine

Thank you for this referral. If the clinical or image interpretation does not parallel your findings or if I can be of any further assistance please contact me.

BREED

Labrador Retriever Mix

Eric Lindquist, DMV, DABVP, Cert. IVUSS, CEO of SonoPath.com
Info@SonoPath.com

SEX

Spayed female

AGE

13 years

WEIGHT

97.1 lbs

INTERPRETED BY

Eric Lindquist, DMV
DABVP, Cert. IVUSS

**IMAGING
PERFORMED BY**

Shari Reffi, CVT

HOSPITAL NAME

Legacy AH

REFERRING VET

Dr. Pontenzone

INVOICE

42990

DATE

2/27/23