



PATIENT

Willow Calderon

SPECIES

Feline

BREED

Domestic Shorthair

SEX

Spayed female

AGE

2 years

WEIGHT

11.9 lbs

INTERPRETED BY

Eric Lindquist, DMV,
DABVP, Cert. IVUSS,
CEO of SonoPath.com

IMAGING PERFORMED BY

Kelly Vazquez, CVT

HOSPITAL NAME

Franklin Lakes AH

PRESENTING CLINICAL SIGNS

History: Patient presents for grade 3/6 heart murmur. Owner is pursuing dental under general anesthesia. In-house ECG found "no pathologic arrhythmias noted on ECG tracing".

ULTRASONOGRAPHIC EXAMINATION OF THE HEART

The echocardiogram in this patient demonstrated normal **left atrial** size based on 3 separate LA measurements. Trivial **mitral** valve insufficiency was noted. The **left ventricle** presented mild concentric hypertrophy and minor turbulence in the **left ventricular outflow tract**. No systolic anterior motion was noted. The **right atrium** and auricle revealed normal size, structure and content. No evidence of masses was noted or chamber overload. **Tricuspid** valvular assessment demonstrated adequate linear morphology and kinetics. The **right ventricle** was of normal size (1/3 diameter of LV), chordae structure, myocardial echogenicity and thickness. **Pulmonic** tract assessment revealed normal valve structure, laminar flow, and diameter (approx. 1:1 pa/ao ratio). No visible **pericardial** or free pleura fluid was noted or extra cardiac pathology in the visible planes. The cranial **mediastinum and pericardial regions** were free of masses in the visible window.

FELINE CARDIAC PARAMETERS	BODY WEIGHT (kg)	HR (BPM)	IVSd (cm)	LVIDd (cm)	LVWd (cm)	FS (%)	EF (%)
NORMAL PARAMETER	-----	150-240	0.3-0.6	1.0-2.1	0.25-0.6	35-67	80-100
PATIENT		135	0.71	0.95	0.71	55	89
FELINE CARDIAC PARAMETERS	LA/AO (Boon)	LA/AO HEART BASE (Sisson)	LA 2D 4-chamber long axis AS to FW (Sisson) (cm)	LVOT VEL. (m/s)	RVOT VEL. (m/s)	IVRT (m/)	
NORMAL PARAMETER	<1.5	0.88-1.79	0.7-1.7	<1.6	<1.3	40-60	
PATIENT	1.4	1.2	1.3	1.23	1.1	NM	
Adapted from June Boon, Veterinary Echocardiography, 1998 Sisson D et al. JVIM 1991; 5: 232, Jacobs et al. Am J Vet Res 1985; 46:1705							

REFERRING VET

Dr. Ward

INVOICE

42932

DATE

2/23/23

ULTRASONOGRAPHIC FINDINGS

Minor left ventricular hypertrophy. Hypertrophic cardiomyopathy phenotype, not clinically significant at this time.

INTERPRETATION OF THE FINDINGS & FURTHER RECOMMENDATIONS

Torbutrol pre med, Propofol induction and Isoflurane maintenance or similar protocol is recommended. There was no overt contraindication to anesthetic procedure. Recheck echocardiogram is recommended in a year or earlier if clinical signs initiate.



PATIENT

Willow Calderon

SPECIES

Feline

BREED

Domestic Shorthair

SEX

Spayed female

AGE

2 years

WEIGHT

11.9 lbs

INTERPRETED BY

Eric Lindquist, DMV,
DABVP, Cert. IVUSS,
CEO of SonoPath.com

IMAGING PERFORMED BY

Kelly Vazquez, CVT

HOSPITAL NAME

Franklin Lakes AH

REFERRING VET

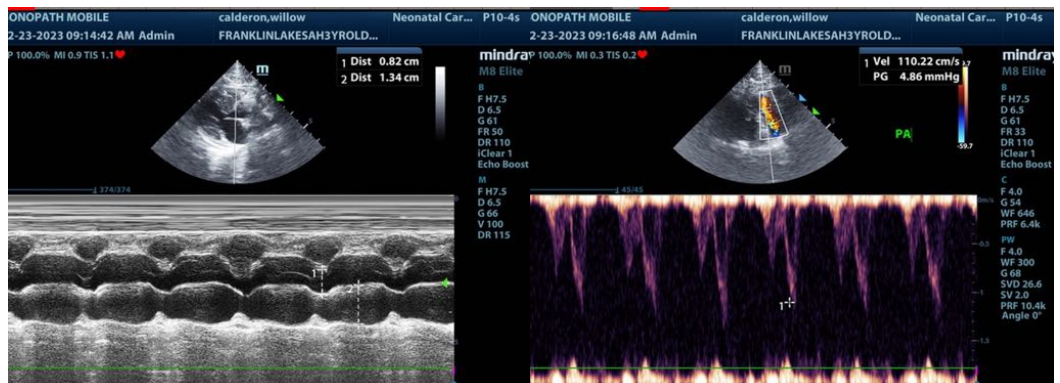
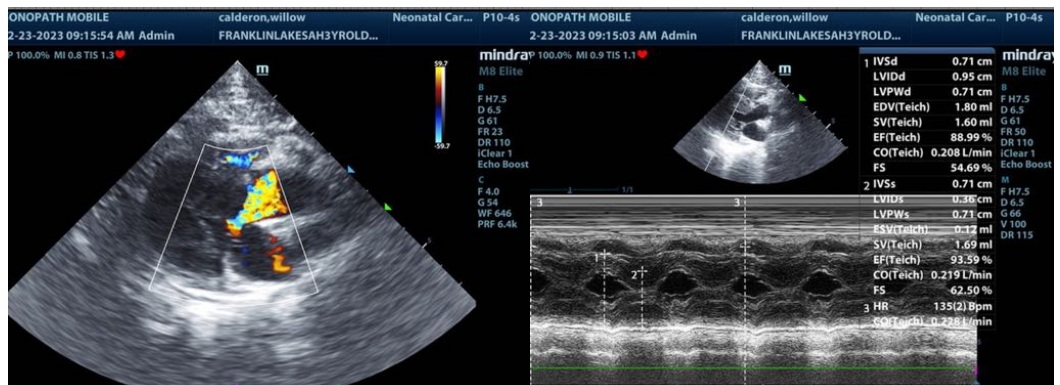
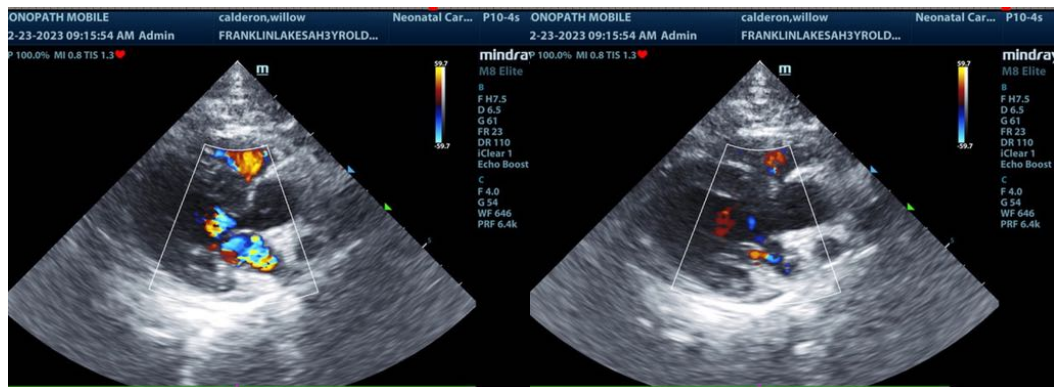
Dr. Ward

INVOICE

42932

DATE

2/23/23





PATIENT

Willow Calderon

SPECIES

Feline

BREED

Domestic Shorthair

SEX

Spayed female

AGE

2 years

WEIGHT

11.9 lbs

INTERPRETED BY

Eric Lindquist, DMV,
DABVP, Cert. IVUSS,
CEO of SonoPath.com

IMAGING PERFORMED BY

Kelly Vazquez, CVT

HOSPITAL NAME

Franklin Lakes AH

REFERRING VET

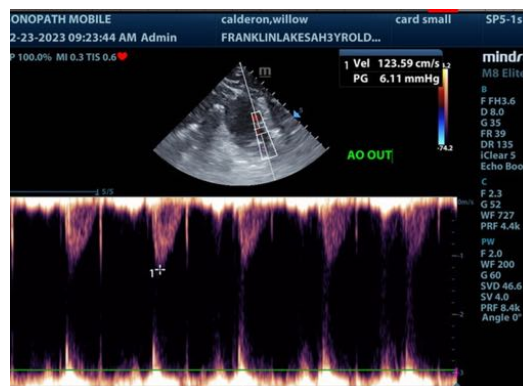
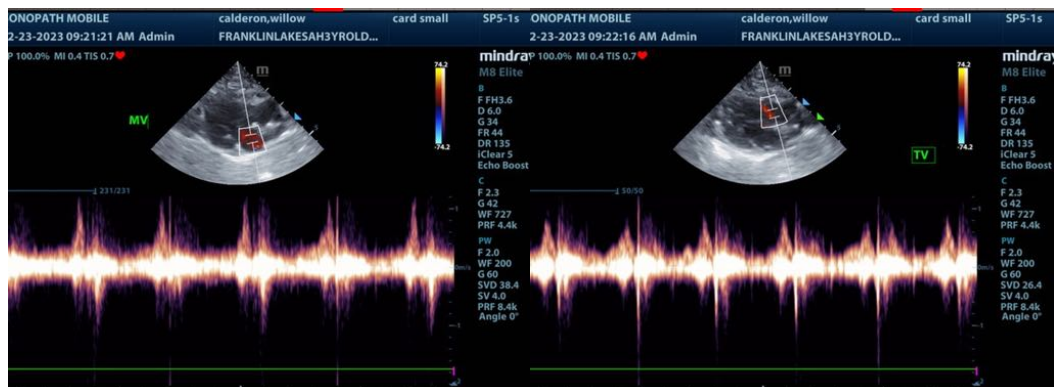
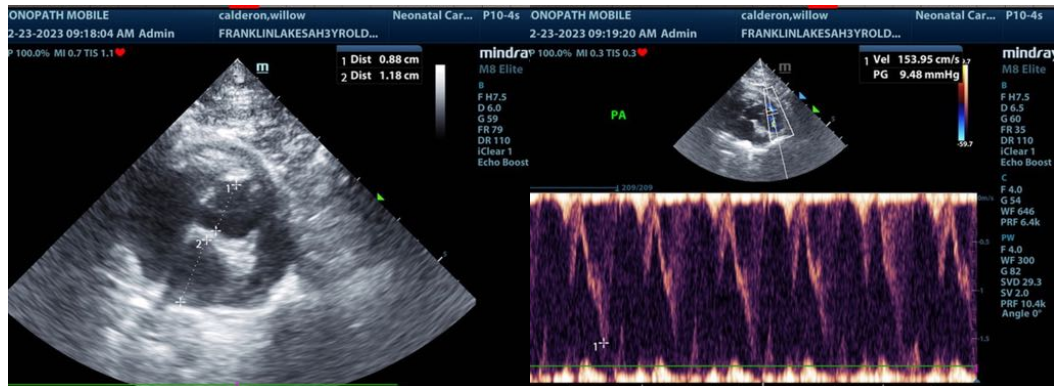
Dr. Ward

INVOICE

42932

DATE

2/23/23

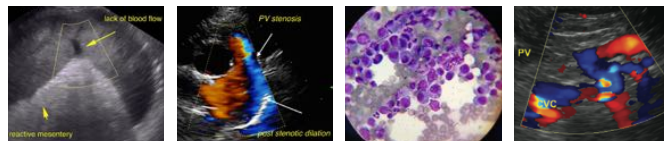


The information and recommendations provided are based on the images presented by the referring veterinarian/sonographer. No evaluation can be communicated regarding pathology that was not visible in the image/video clips provided.

Thank you for this referral. If the clinical or image interpretation does not parallel your findings or if I can be of any further assistance please contact me.

Eric Lindquist, DMV, DABVP, Cert. IVUSS, CEO of SonoPath.com

Info@SonoPath.com



PATIENT

Willow Calderon

SPECIES

Feline

BREED

Domestic Shorthair

SEX

Spayed female

AGE

2 years

WEIGHT

11.9 lbs

INTERPRETED BY

Eric Lindquist, DMV,
DABVP, Cert. IVUSS,
CEO of SonoPath.com

**IMAGING
PERFORMED BY**

Kelly Vazquez, CVT

HOSPITAL NAME

Franklin Lakes AH

REFERRING VET

Dr. Ward

INVOICE

42932

DATE

2/23/23