



**PATIENT**

Ringo Demartinis

**SPECIES**

Feline

**BREED**

Domestic Shorthair

**SEX**

Neutered male

**AGE**

10 years

**WEIGHT**

12.4 lbs

**INTERPRETED BY**

Eric Lindquist, DMV  
DABVP, Cert. IVUSS

**IMAGING PERFORMED BY**

Valeryia Shumskaya

**HOSPITAL NAME**

The Gentle Vet

**REFERRING VET**

Dr. Dulude

**INVOICE**

42896

**DATE**

2/21/23

**PRESENTING CLINICAL SIGNS**

History: Chronic intermittent vomiting, worse lately, elevated liver enzymes  
Abnormal PE/Chem/CBC/UA Results:

**ULTRASONOGRAPHIC EXAMINATION OF THE ABDOMEN**

**Urinary System**

The **urinary bladder**, trigone, and pelvic urethra presented normal thicknesses and normal tone. The ureters were not visible which is normal. No uroliths or sediment were visualized and anechoic urine was present. No evidence of inflammatory or neoplastic changes was noted. Ureteral papillae were normal.

The **kidneys** revealed largely normal size and structure, corticomedullary definition and ratio (cortex 1/3 of medulla) were essentially maintained with some age-related loss of curvilinear patterns regarding the capsule and C/M junction. The cortices presented largely uniform texture with some increased echogenicity expected for his age patient. Medullary structure differed distinctly from that of the cortex and no evidence of pelvic dilation was present. The left kidney measured 3.0 cm and the right kidney measured 3.8 cm.

**Adrenal Glands**

Both **adrenal glands** were visualized and recognized as having normal shape, size, position and echogenicity for this breed. The phrenic vasculature, glandular echogenicity and detail were unremarkable. Capsule, cortex, and medullary definition were normal for this age patient. The right adrenal gland measured 0.43 cm. The left adrenal gland measured 0.47 cm.

**Spleen**

The **spleen** was mildly enlarged with uniform, but subtly micronodular parenchyma, and undulating capsular contour. This is consistent with reactive spleen owing to immune stimulus or early infiltrative disease such as mast cell disease or lymphoma. 25-gauge FNA would be ideal if weight loss is an issue to differentiate early round cell neoplasia versus splenitis or reactive spleen all of which can present in this manner. The splenic width measured 1.1 cm.

**Liver**

The **liver** revealed increased portal markings. The liver was normal in size and vascularity. The gallbladder wall was slightly echogenic with sand accumulation/small calculus that measured 0.5 cm.

**Gastrointestinal**

The **gastrointestinal tract** revealed minor variable thickening and echogenic submucosal changes most consistent with low grade end result of chronic GI disease such as IBD and may be related to malassimilation of nutrients if any weight loss is present. The colon was also thickened. No obvious neoplastic patterns were noted and luminal content as unremarkable.



**PATIENT**

Ringo Demartinis

**SPECIES**

Feline

**BREED**

Domestic Shorthair

**SEX**

Neutered male

**AGE**

10 years

**WEIGHT**

12.4 lbs

**INTERPRETED BY**

Eric Lindquist, DMV  
DABVP, Cert. IVUSS

**IMAGING  
PERFORMED BY**

Valeryia Shumskaya

**HOSPITAL NAME**

The Gentle Vet

**REFERRING VET**

Dr. Dulude

**INVOICE**

42896

**DATE**

2/21/23

**Pancreas**

The base and limbs of the **pancreas** were observed to be largely isoechoic to surrounding omental fat. Some parenchymal remodeling, however, with mild deviation from curvilinear normalcy was observed. Pancreatic duct and capsular irregularities were present consistent with age related changes. If pain upon imaging (+ Murphy sign) was present or if the patient is focally painful in subxiphoid palpation then low-grade smoldering chronic pancreatitis should be suspected.

**ULTRASONOGRAPHIC FINDINGS**

Sand/calculus accumulation of the gallbladder/cholelithiasis, non-obstructive.

Chronic inflammatory pattern. Diffuse intestinal thickening without neoplastic criteria. This is consistent with chronic inflammatory bowel.

Chronic pancreatic changes.

Age related renal changes.

Reactive spleen, likely the possibility of emerging round cell neoplasia.

**INTERPRETATION OF THE FINDINGS & FURTHER RECOMMENDATIONS**

FNA of the spleen and liver is indicated. Ursodiol therapy would be appropriate. The following protocol may prove effective.

Part or all of this protocol may be considered based on your clinical impression of the patient:

Recommend pain management when anorexic with **Buprenorphine** (0.01-0.02 mg/kg IM or SC), clinical trial of **Zithromax** (50 mg sid/cat x 10 days, 3 weeks if bartonella +), **Prednisolone** (0.5-2 mg/kg tapering over 1 week to minimal effective dose), and **B12 injections** if weight loss (Cyanobalamine 250 mcg sub-q once-weekly x six weeks, then every other week for six weeks and then once-monthly, long-term if necessary), **novel-protein or hydrolyzed diet** (*Hydrolyzed diets have been shown to be more effective in dietary intolerance case management compared to hypoallergenic diets*) or the **magical Purina DM** (changing protein source is crucial and may need rotation every 6 months if clinical signs recur) Diet trials is a whatever works phenomenon. If vomiting becomes a persistent issue then endoscopy would be warranted and/or recheck sonogram to assess more emerging disease. One diet does not work for all patients so different trials may be necessary or protein source rotation every 6 months as new sensitivities develop.



**PATIENT**

Ringo Demartinis

**SPECIES**

Feline

**BREED**

Domestic Shorthair

**SEX**

Neutered male

**AGE**

10 years

**WEIGHT**

12.4 lbs

**INTERPRETED BY**

Eric Lindquist, DMV  
DABVP, Cert. IVUSS

**IMAGING PERFORMED BY**

Valeryia Shumskaya

**HOSPITAL NAME**

The Gentle Vet

**REFERRING VET**

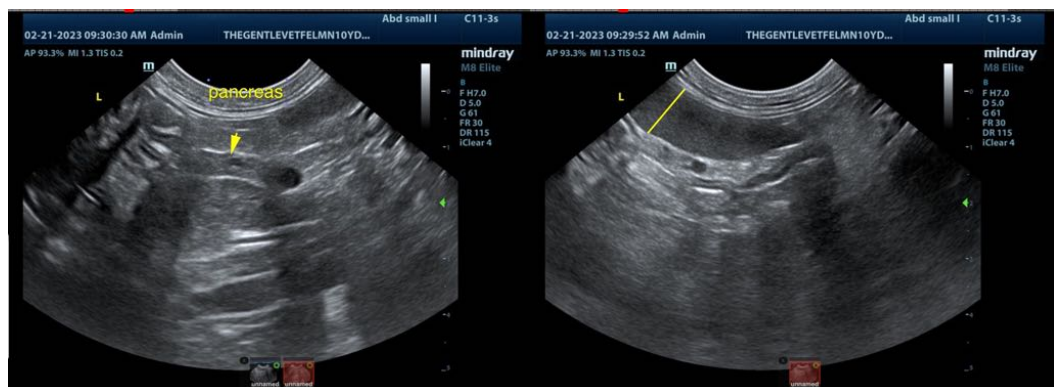
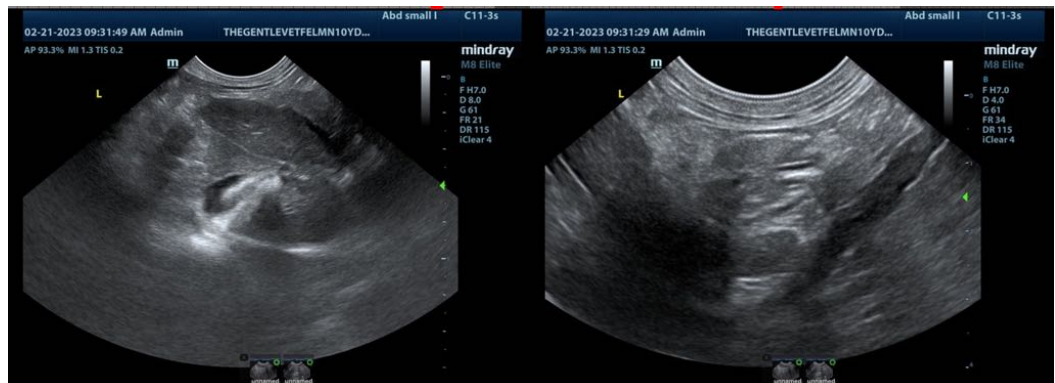
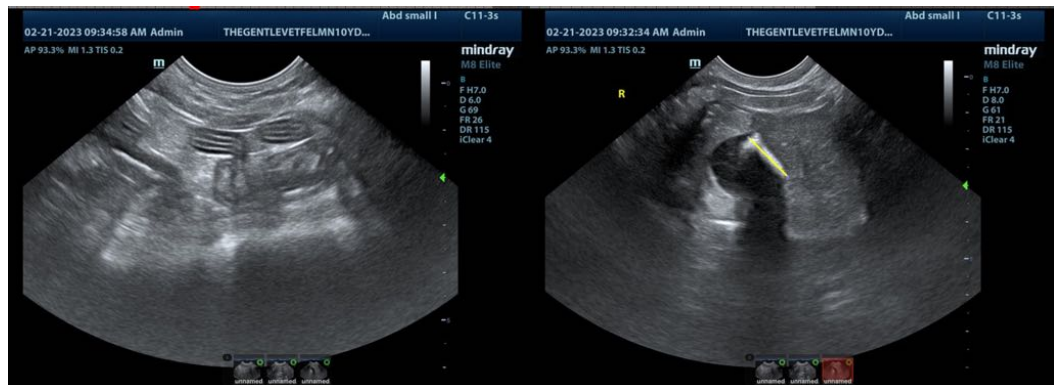
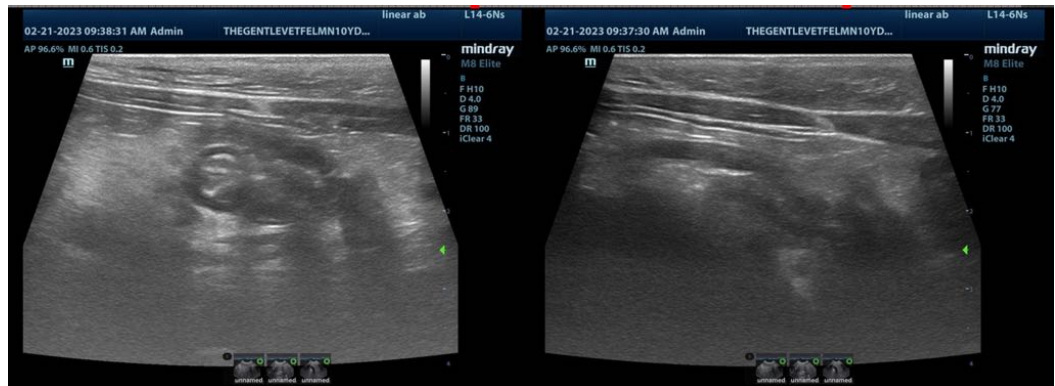Dr. Dulude

**INVOICE**

42896

**DATE**

2/21/23





**PATIENT**

Ringo Demartinis

**SPECIES**

Feline

**BREED**

Domestic Shorthair

**SEX**

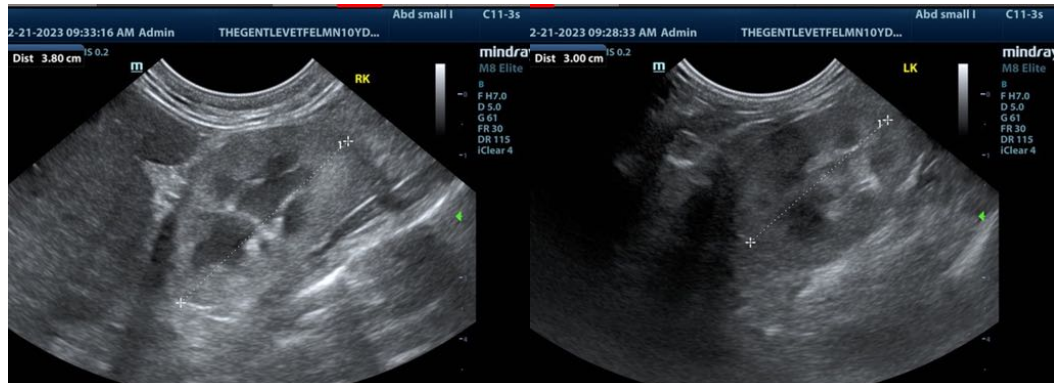
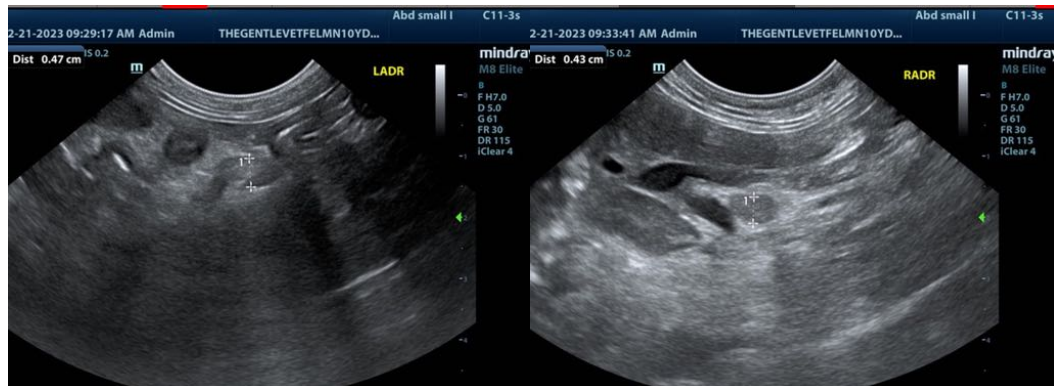
Neutered male

**AGE**

10 years

**WEIGHT**

12.4 lbs



**INTERPRETED BY**

Eric Lindquist, DMV  
DABVP, Cert. IVUSS

**IMAGING PERFORMED BY**

Valeryia Shumskaya

**HOSPITAL NAME**

The Gentle Vet

**REFERRING VET**

Dr. Dulude

**INVOICE**

42896

**DATE**

2/21/23

The information and recommendations provided are based on the images presented by the referring veterinarian/sonographer. No evaluation can be communicated regarding pathology that was not visible in the image/video clips provided.

Thank you for this referral. If the clinical or image interpretation does not parallel your findings or if I can be of any further assistance please contact me.

Eric Lindquist, DMV, DABVP, Cert. IVUSS  
info@SonoPath.com