



**PATIENT**

Benny Smith

**PRESENTING CLINICAL SIGNS**

History: Yeast/Allergies, PDH -Cushing's, deaf, elevated ionized Ca (Michigan) R/o Hyperparathyroid tumor. Current meds: vetoryl 10mg SID

**SPECIES**

Canine

Abnormal PE/Chem/CBC/UA Results: elevated liver enzymes, eos, elevated ionized Ca (Michigan)

**BREED**

Shih Tzu

**ULTRASONOGRAPHIC EXAMINATION OF THE THYROID**

The left thyroid lobe revealed a 0.93 x 0.5 cm hypoechoic, parathyroid nodule in the mid body of the left thyroid lobe. The cranial body revealed a 0.3 x 0.33 cm cranial nodule. This is most consistent with parathyroid hypertrophy. However, the mid nodule is most consistent with parathyroid adenoma. The right thyroid lobe is uniform with no evidence of pathology.

**SEX**

Neutered male

**ULTRASONOGRAPHIC FINDINGS**

Left parathyroid adenoma.

**AGE**

9 years

Normal right thyroid and parathyroids.

**WEIGHT**

14.6 lbs

**INTERPRETATION OF THE FINDINGS & FURTHER RECOMMENDATIONS**

A left parathyroidectomy is recommended. Surgical judgment call on whether the cranial and medial lesions in the left thyroid lobe need to be resected as the cranial nodule is at the upper limits of normal for parathyroid hyperplasia versus parathyroid adenoma. Two separate lesions may be present. Removal of the larger medial 1.0 cm lesion as well as the cranial lesion may be appropriate.

**INTERPRETED BY**

Eric Lindquist, DMV  
DABVP, Cert. IVUSS

**IMAGING PERFORMED BY**

Jessica Miller, RDMS

**HOSPITAL NAME**

Whippany VH

**REFERRING VET**

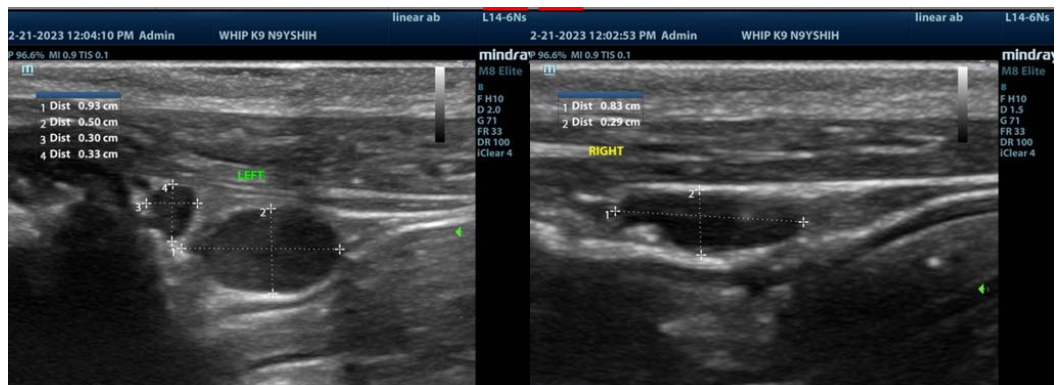
Dr. Smith

**INVOICE**

42894

**DATE**

2/21/23





**PATIENT**

Benny Smith

**SPECIES**

Canine

**BREED**

Shih Tzu

**SEX**

Neutered male

**AGE**

9 years

**WEIGHT**

14.6 lbs

**INTERPRETED BY**

Eric Lindquist, DMV  
DABVP, Cert. IVUSS

**IMAGING PERFORMED BY**

Jessica Miller, RDMS

**HOSPITAL NAME**

Whippany VH

**REFERRING VET**

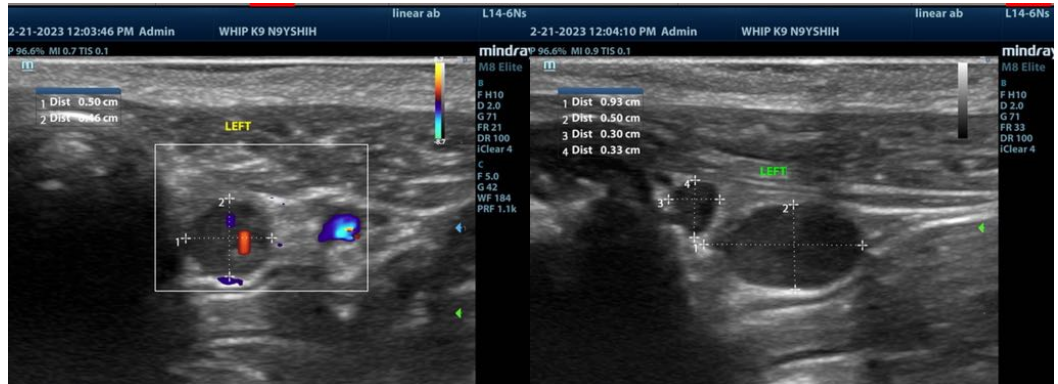Dr. Smith

**INVOICE**

42894

**DATE**

2/21/23



The information and recommendations provided are based on the images presented by the referring veterinarian/sonographer. No evaluation can be communicated regarding pathology that was not visible in the image/video clips provided.

Thank you for this referral. If the clinical or image interpretation does not parallel your findings or if I can be of any further assistance please contact me.

**Eric Lindquist**, DMV, DABVP, Cert. IVUSS, CEO of SonoPath.com  
Info@SonoPath.com