



PATIENT

Finley Giordano

PRESENTING CLINICAL SIGNS

History: Retained testicle, L testicle removed

SPECIES

Canine

ULTRASONOGRAPHIC EXAMINATION OF THE ABDOMEN

Urinary System

The **urinary bladder**, trigone, and pelvic urethra presented normal thicknesses and normal tone. The ureters were not visible which is normal. No uroliths or sediment were visualized and anechoic urine was present. No evidence of inflammatory or neoplastic changes was noted. Ureteral papillae were normal.

BREED

Bernese Mountain Dog

The **prostate** was uniformly enlarged with lobar swelling appeared to impinge upon the urethra and mildly deviate the descending colon. The prostatic tissue was hyperechoic containing focal areas of decreased echogenicity. These changes are suggestive of either chronic inflammatory episodes, benign cystic pathology or both. Underlying neoplasia cannot be completely ruled-out but is lower on the differential list. This presentation is most consistent with benign prostatic hyperplasia with possible active prostatitis. Neutering or off-label Finasteride (Propecia) (0.1-0.5 mg/kg Sid) treatment is indicated +/- FNA or prostatic wash cytology and culture. The retained testicle was noted at the intraabdominal base adjacent to the body wall on the right side at the level of the inguinal canal just cranial to the iliac trifurcation.

SEX

Male

AGE

1 year

WEIGHT

92 lbs

The **kidneys** revealed normal size and structure, corticomedullary definition and ratio for this age. The cortices presented largely uniform texture with normal echogenic relationship to liver and spleen. Medullary structure differed distinctly from the cortex and no evidence of pelvic dilation was present. The capsules were acceptably uniform without significant irregularities. The left kidney measured 6.2 cm. The right kidney measured 7.03 cm.

INTERPRETED BY

Tam Mengine, DVM,
DABVP (canine/feline
practice)

Adrenal Glands

Both **adrenal glands** were visualized and recognized as having normal shape, size, position and echogenicity for this breed. The phrenic vasculature, glandular echogenicity and detail were unremarkable. Capsule, cortex, and medullary definition were normal for this age patient. The left adrenal gland measured 2.13 x 0.48 cm at the cranial pole and 0.36 cm at the caudal pole. The right adrenal gland measured 2.42 x 0.6 cm at the cranial pole and 0.38 cm at the caudal pole.

IMAGING PERFORMED BY

Valeryia Shumskaya

HOSPITAL NAME

Legacy AH

Spleen

The **spleen** was mildly enlarged with subtle, micronodular changes. The spleen was folded upon itself caudally.

REFERRING VET

Dr. Pontenzone

Liver

The **liver** images submitted revealed subjectively normal liver size, contour, and structure. Parenchymal echogenicity was naturally coarse and hypoechoic to the spleen. Vascular and biliary tracts were of normal volume with no evidence of congestion. The gallbladder presented acceptably thin walls with primarily anechoic content. The cystic and common bile ducts were normal. No pathological hepatic lymphadenopathy was evident. No overt structural evidence of inflammatory, infiltrative or regenerative pathology was evident.

INVOICE

42874

DATE

2/15/23



PATIENT

Finley Giordano

SPECIES

Canine

BREED

Bernese Mountain Dog

SEX

Male

AGE

1 year

WEIGHT

92 lbs

INTERPRETED BY

Tam Mengine, DVM,
DABVP (canine/feline
practice)

**IMAGING
PERFORMED BY**

Valeryia Shumskaya

HOSPITAL NAME

Legacy AH

REFERRING VET

Dr. Pontenzone

INVOICE

42874

DATE

2/15/23

Gastrointestinal

Examination of the **gastrointestinal tract** revealed a stomach and intestine free of stasis, of normal wall thickness, acceptable curvilinear mural detail, and peristaltic activity. Small and large intestine demonstrated normal luminal chyme and stool consistency respectively. The mesenteric lymph nodes were reactive measuring up to 2.0 cm.

Pancreas

The base and limbs of the **pancreas** were observed to be largely isoechoic to surrounding omental fat. Pancreatic duct and capsular contour were acceptably normal and parenchyma respected normal curvilinear patterns. No overt evidence of active inflammatory or neoplastic disease was noted.

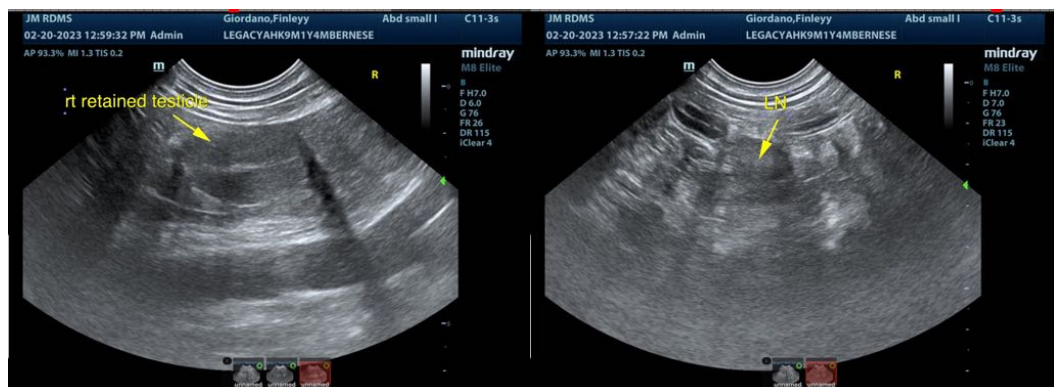
ULTRASONOGRAPHIC FINDINGS

Retained testicle at the intraabdominal inguinal canal just cranial dorsal to the iliac trifurcation adjacent to the colon.

Minor BPH prostate.

INTERPRETATION OF THE FINDINGS & FURTHER RECOMMENDATIONS

Surgical intervention is recommended.





PATIENT

Finley Giordano

SPECIES

Canine

BREED

Bernese Mountain Dog

SEX

Male

AGE

1 year

WEIGHT

92 lbs

INTERPRETED BY

Tam Mengine, DVM,
DABVP (canine/feline
practice)

**IMAGING
PERFORMED BY**

Valeryia Shumskaya

HOSPITAL NAME

Legacy AH

REFERRING VET

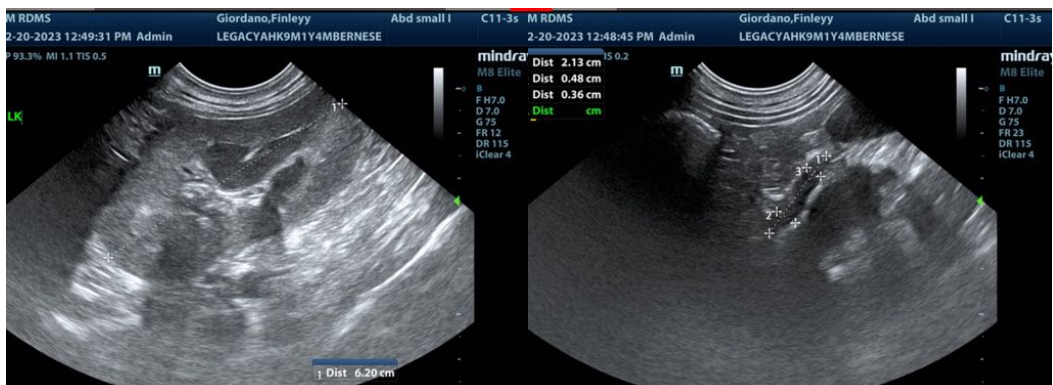
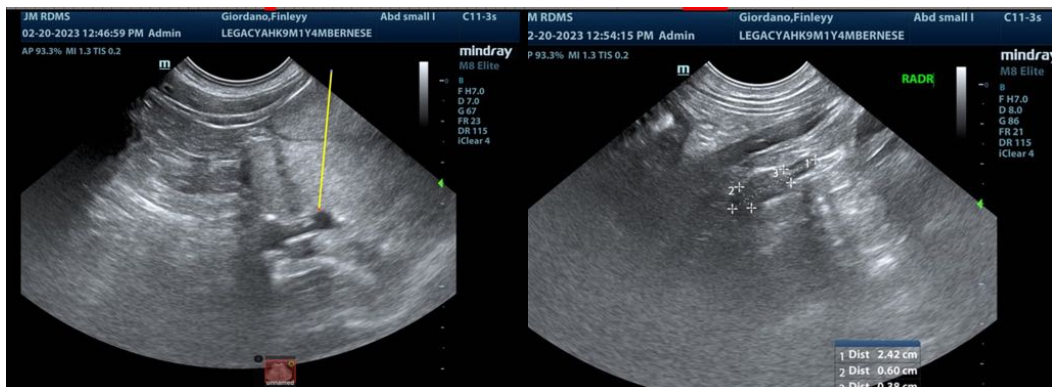
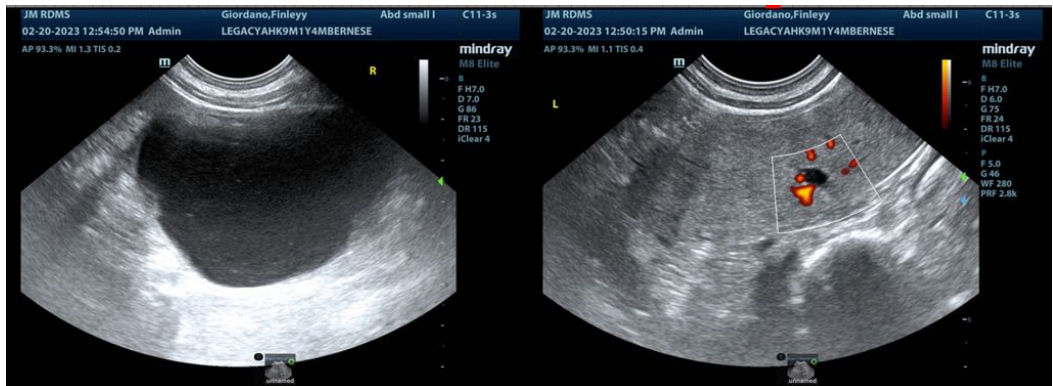
Dr. Pontenzone

INVOICE

42874

DATE

2/15/23



The information and recommendations provided are based on the images presented by the referring veterinarian/sonographer. No evaluation can be communicated regarding pathology that was not visible in the image/video clips provided.

Thank you for this referral. If the clinical or image interpretation does not parallel your findings or if I can be of any further assistance please contact me.

Tam Mengine, DVM, DABVP (canine/feline practice)

info@SonoPath.com