



PATIENT

Brody Dempsey

PRESENTING CLINICAL SIGNS

Cough, weight loss, cardiomegaly.
Increased platelets, ALP increased at 314.

SPECIES

Canine

ULTRASONOGRAPHIC EXAMINATION OF THE HEART

BREED

Shih Tzu

The echocardiogram in this patient demonstrated normal **left atrial** size based on 3 different LA measurement methods. Chamber volumes and echogenicity were normal. The cranial and caudal **mitral** valve leaflets presented vegetative thickening consistent with endocardiosis. Doppler indicated measurable insufficiency. The **left ventricle** presented thicknesses with linear contour and was not dilated nor restricted. The **myocardium** presented normal echogenicity without subjective evidence of significant fibrotic or ischemic disease. **Contractility** of the ventricular walls was adequate and in normal range for this patient evidenced by the fractional shortening measurement and subjective evaluation of the different regions of the myocardium. The **left ventricular outflow** tract demonstrated normal laminar flow and subjective structural integrity. The **right atrium** and auricle revealed normal size, structure and content. No evidence of masses was noted or chamber overload. **Tricuspid** valvular assessment demonstrated adequate linear morphology. The **right ventricle** was of normal size (1/3 diameter of LV), chordae structure, myocardial echogenicity and thickness. **Pulmonic** tract assessment revealed normal valve structure, laminar flow, and diameter (approx.1:1 pa/ao ratio). No visible **pericardial** or free pleura fluid was noted. No echographically detectable evidence of infiltrative disease was visible. The cranial **mediastinum and pericardial regions** were free of masses in the visible window.

SEX

Neutered male

AGE

12 years

INTERPRETED BY

Eric Lindquist, DMV
DABVP, Cert. IVUSS

IMAGING PERFORMED BY

Eric Lindquist, DMV
DABVP, Cert. IVUSS

HOSPITAL NAME

Butler VH

REFERRING VET

Dr. Garro

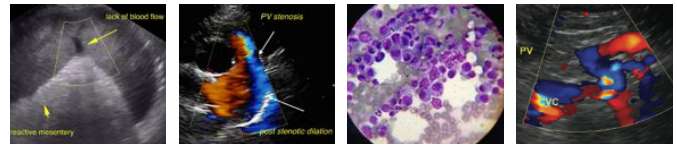
INVOICE

42519

DATE

2/2/23

CANINE	MR	TR	LA/AO	LA/AO	FS	EF	EPSS
CARDIAC PARAMETERS	VMAX (m/s)	VMAX (m/s)	(Boon method)	(Heart Base;)	(%)	(%)	(cm)
NORMAL PARAMETER	4.5-5.5	<2.7	1.3	<1.6	28-40	40-100	<0.6
PATIENT	5.21	2.9	1.6	2.1	52	84	0.2
CANINE	HR	AV	PV	BODY WEIGHT	LA	LVIDd	LVIDs
CARDIAC PARAMETERS	(BPM)	VMAX (m/s)	MAX (m/s)	(kg)	2D short axis Base view (cm)	Avg; 2D and m-mode short axis (cm)	Avg; 2D and m-mode short axis (cm)
NORMAL PARAMETER	50-100	0.7-1.7	0.7-1.6	BELOW	BELOW	BELOW	BELOW
PATIENT	90	1.1	0.78		4.34	3.09	



PATIENT

Brody Dempsey

SPECIES

Canine

BREED

Shih Tzu

SEX

Neutered male

AGE

12 years

INTERPRETED BY

Eric Lindquist, DMV
DABVP, Cert. IVUSS

IMAGING PERFORMED BY

Eric Lindquist, DMV
DABVP, Cert. IVUSS

HOSPITAL NAME

Butler VH

REFERRING VET

Dr. Garro

INVOICE

42519

DATE

2/2/23

ULTRASONOGRAPHIC EXAMINATION OF THE ABDOMEN

Urinary System

The **urinary bladder**, trigone, and pelvic urethra presented normal thicknesses and normal tone. The ureters were not visible which is normal. No uroliths or sediment were visualized and anechoic urine was present. No evidence of inflammatory or neoplastic changes was noted. Ureteral papillae were normal.

The **kidneys** revealed largely normal size and structure, corticomedullary definition and ratio (cortex 1/3 of medulla) were essentially maintained with some age-related loss of curvilinear patterns regarding the capsule and C/M junction. The cortices presented largely uniform texture with some increased echogenicity expected for his age patient. Medullary structure differed distinctly from that of the cortex and no evidence of pelvic dilation was present. The left kidney measured 3.87 cm. The right kidney measured 4.59 cm.

Adrenal Glands

Both **adrenal glands** were visualized and recognized as having normal shape, size, position and echogenicity for this breed. The phrenic vasculature, glandular echogenicity and detail were unremarkable. Capsule, cortex, and medullary definition were normal for this age patient. The left adrenal gland measured 1.88 x 0.58 cm at the cranial pole and 0.64 cm at the caudal pole. The right adrenal gland measured 1.93 x 0.88 cm at the cranial pole and 0.54 cm at the caudal pole.

Spleen

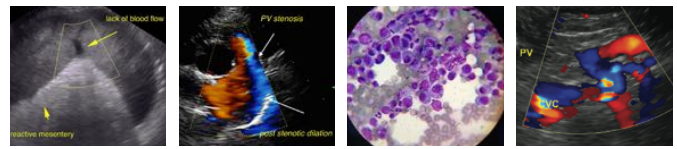
The **spleen** presented a smooth homogeneous parenchyma hyperechoic to liver and renal cortical parenchyma. The capsule was smooth without noticeable expansion or deviation from within the spleen or adjacent pathology. The splenic vasculature demonstrated normal volume without signs of congestion or thrombosis. No sonographic evidence of acute or chronic inflammatory, neoplastic, or infarctual changes was noted.

Liver

The **liver** was diffusely hyperechoic to the falciform fat. Multi-focal, hypoechoic nodules were noted without disruption of architecture. Curvilinear patterns within the nodule were maintained. There is no overt evidence of neoplasia, likely nodular hyperplasia with vacuolar hepatopathy. The **gallbladder** revealed a minor amount of debris. The cystic and common bile ducts were normal. No pathological hepatic lymphadenopathy was evident. No overt structural evidence of inflammatory, infiltrative or regenerative pathology was evident.

Gastrointestinal

The **gastrointestinal tract** revealed minor variable thickening and echogenic submucosal changes most consistent with low grade end result of chronic GI disease such as IBD and may be related to malassimilation of nutrients if any weight loss is present. Some areas of spastic bowel were noted. No obvious neoplastic patterns were noted and luminal content as unremarkable.



PATIENT

Pancreas

Brody Dempsey

The base and limbs of the **pancreas** were observed to be largely isoechoic to surrounding omental fat. Some parenchymal remodeling, however, with mild deviation from curvilinear normalcy was observed. Pancreatic duct and capsular irregularities were present consistent with age related changes. If pain upon imaging (+ Murphy sign) was present or if the patient is focally painful in subxiphoid palpation then low-grade smoldering chronic pancreatitis should be suspected.

SPECIES

Canine

BREED

Shih Tzu

ULTRASONOGRAPHIC FINDINGS

Chronic GI changes.

SEX

Neutered male

Age related abdominal changes.

Minor pancreatic remodeling.

Mitral valve insufficiency.

AGE

12 years

INTERPRETATION OF THE FINDINGS & FURTHER RECOMMENDATIONS

The patient is on Pimobendan, Lasix and ace inhibitor. The initial presentation based on radiographs is consistent with early state C1 valvular disease. I recommend continuation with triple therapy, yet add Spironolactone at 1-2 mg/kg b.i.d. and diminish Lasix to minimal effective dose. BUN, creatinine, urine specific gravity, blood pressure measurements and target respiratory rate are all indicated. Follow-up radiographs are warranted as a baseline. A recheck echocardiogram is recommended in 1-3 months depending on patient management.

INTERPRETED BY

Eric Lindquist, DMV
DABVP, Cert. IVUSS

IMAGING PERFORMED BY

Eric Lindquist, DMV
DABVP, Cert. IVUSS

The heart has some volume overload and is working to compensate for the valvular insufficiency. Target respiratory rate is < 20 resp/minute after therapy. After initiating therapy, I recommend recheck on the clinical exam, BUN, Creatinine, USG, Chest radiographs & Blood pressure in 5-7 days. Recheck echo in 1 month. Earlier if clinical decompensation is occurring. I do not recommend anesthesia at this time until stabilization has occurred on the recommended medications. Repeat preanesthetic echo is ideal if anesthesia is eventually necessary

HOSPITAL NAME

Butler VH

REFERRING VET

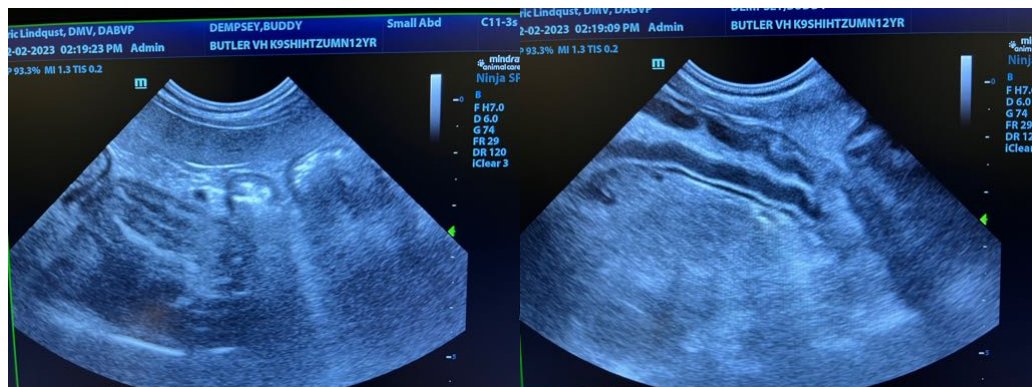
Dr. Garro

INVOICE

42519

DATE

2/2/23





PATIENT

Brody Dempsey

SPECIES

Canine

BREED

Shih Tzu

SEX

Neutered male

AGE

12 years

INTERPRETED BY

Eric Lindquist, DMV
DABVP, Cert. IVUSS

IMAGING PERFORMED BY

Eric Lindquist, DMV
DABVP, Cert. IVUSS

HOSPITAL NAME

Butler VH

REFERRING VET

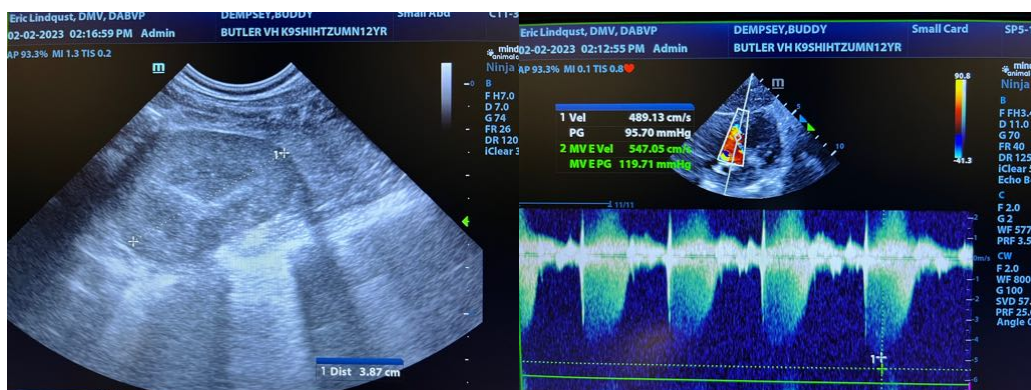
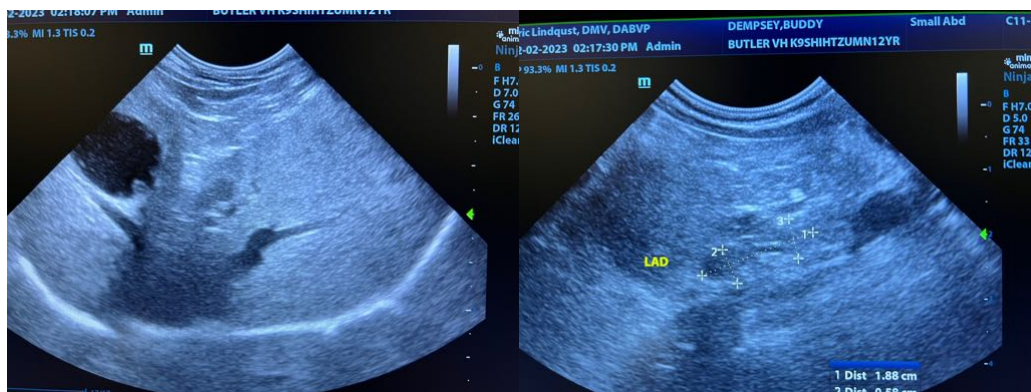
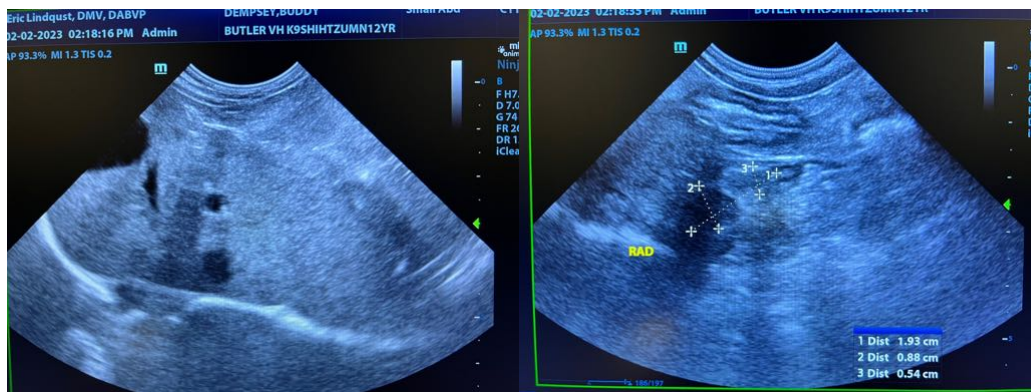
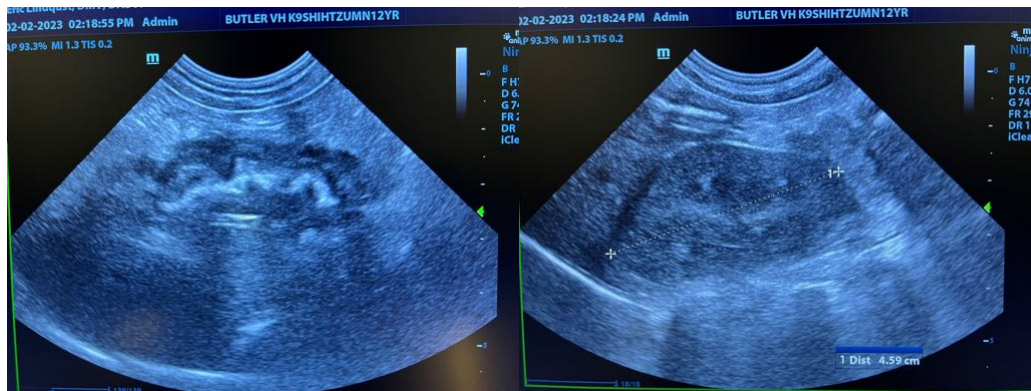
Dr. Garro

INVOICE

42519

DATE

2/2/23





PATIENT

Brody Dempsey

SPECIES

Canine

BREED

Shih Tzu

SEX

Neutered male

AGE

12 years

INTERPRETED BY

Eric Lindquist, DMV
DABVP, Cert. IVUSS

IMAGING PERFORMED BY

Eric Lindquist, DMV
DABVP, Cert. IVUSS

HOSPITAL NAME

Butler VH

REFERRING VET

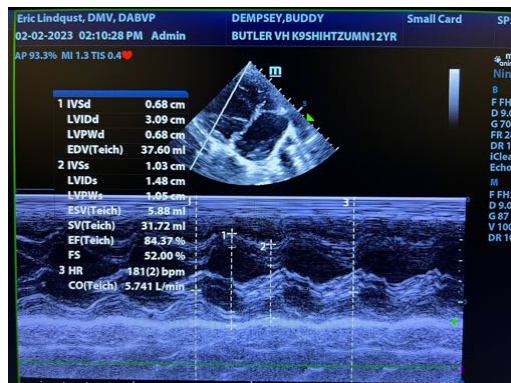
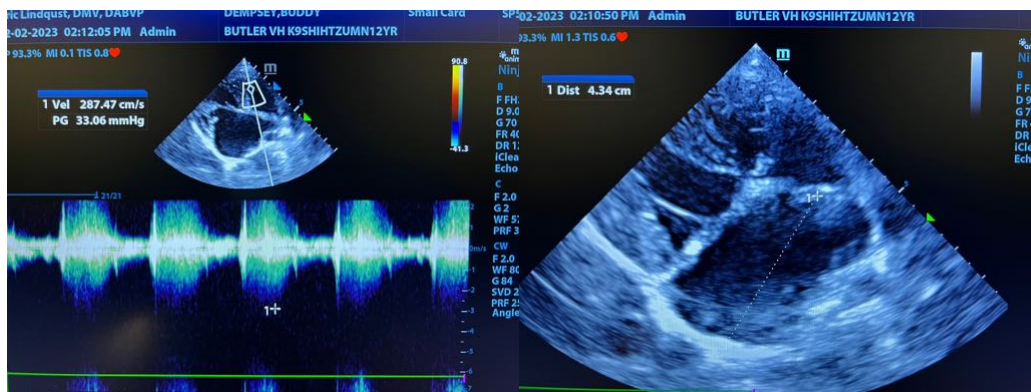
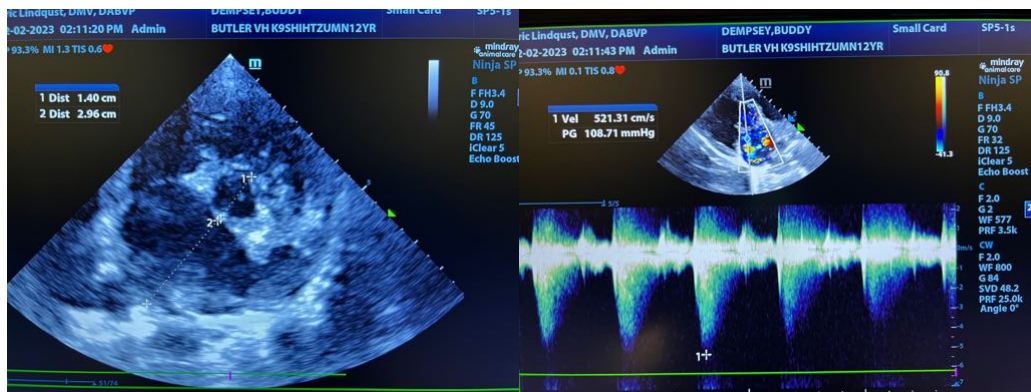
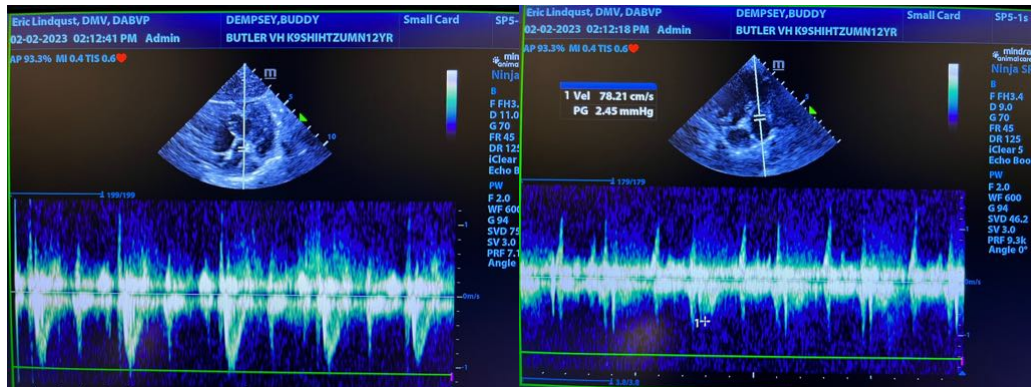
Dr. Garro

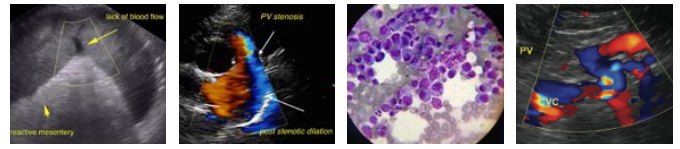
INVOICE

42519

DATE

2/2/23





PATIENT

Brody Dempsey

The information and recommendations provided are based on the images presented by the referring veterinarian/sonographer. No evaluation can be communicated regarding pathology that was not visible in the image/video clips provided.

SPECIES

Canine

Thank you for this referral. If the clinical or image interpretation does not parallel your findings or if I can be of any further assistance please contact me.

BREED

Shih Tzu

Eric Lindquist, DMV, DABVP, Cert. IVUSS, CEO of SonoPath.com
Info@SonoPath.com

SEX

Neutered male

AGE

12 years

INTERPRETED BY

Eric Lindquist, DMV
DABVP, Cert. IVUSS

**IMAGING
PERFORMED BY**

Eric Lindquist, DMV
DABVP, Cert. IVUSS

HOSPITAL NAME

Butler VH

REFERRING VET

Dr. Garro

INVOICE

42519

DATE

2/2/23