



**PATIENT**

Snoopy Ruben

**PRESENTING CLINICAL SIGNS**

History: 1 month recheck ultrasound - gallbladder sludge current meds: Ursodiol, Denamarin, Flagyl  
Abnormal PE/Chem/CBC/UA Results: ALT = 155, ALP = 1942, GGT= 20 UA SG = 1.012

**SPECIES**

Canine

**ULTRASONOGRAPHIC EXAMINATION OF THE ABDOMEN**

**Urinary System**

**BREED**

Beagle Mix

The **urinary bladder**, trigone, and pelvic urethra presented normal thicknesses and normal tone. The ureters were not visible which is normal. No uroliths or sediment were visualized and anechoic urine was present. No evidence of inflammatory or neoplastic changes was noted. Ureteral papillae were normal.

**SEX**

Spayed female

The **kidneys** revealed normal size and structure, corticomedullary definition and ratio for this age. The cortices presented largely uniform texture with normal echogenic relationship to liver and spleen. Medullary structure differed distinctly from the cortex and no evidence of pelvic dilation was present. The capsules were acceptably uniform without significant irregularities. The right kidney measured 6.73 cm. The left kidney measured 5.91 cm.

**AGE**

11 years

**WEIGHT**

**Adrenal Glands**

The left **adrenal gland** was mildly enlarged at the caudal pole and mildly heterogenous measuring 2.38 x 0.91 cm at the caudal pole and 0.51 cm at the cranial pole. The right adrenal gland measured 2.57 x 0.9 cm at the cranial pole and 0.63 cm at the caudal pole.

**INTERPRETED BY**

Eric Lindquist, DMV  
DABVP, Cert. IVUSS

**Spleen**

The **spleen** presented a smooth homogeneous parenchyma hyperechoic to liver and renal cortical parenchyma. The capsule was smooth without noticeable expansion or deviation from within the spleen or adjacent pathology. The splenic vasculature demonstrated normal volume without signs of congestion or thrombosis. No sonographic evidence of acute or chronic inflammatory, neoplastic, or infarctual changes was noted.

**IMAGING PERFORMED BY**

Valeryia Shumskaya

**HOSPITAL NAME**

Blairstown AH

**Liver**

The **liver** images submitted revealed subjectively normal liver size, contour, and structure. Parenchymal echogenicity was naturally coarse and hypoechoic to the spleen. The caudate process is mildly swollen at 5.6 x 5.4 cm. Vascular and biliary tracts were of normal volume with no evidence of congestion. The gallbladder presented a minor amount of debris, yet the gallbladder appears reduced in size in long axis measuring 6.0 x 3.2 cm. Flattened, tear drop appearance was maintained, yet sludge was persistently excessive.

**REFERRING VET**

Dr. Lovell

**INVOICE**

42802

**DATE**

2/14/23

**Gastrointestinal**

Examination of the **gastrointestinal tract** revealed a stomach and intestine free of stasis, of normal wall thickness, acceptable curvilinear mural detail, and peristaltic activity. Small and large intestine



**PATIENT**

Snoopy Ruben

demonstrated normal luminal chyme and stool consistency respectively. No obstructive or overt infiltrative disease was noted. No associated abnormal lymphatic activity was noted.

**SPECIES**

Canine

**Pancreas**

The base and limbs of the **pancreas** were observed to be largely isoechoic to surrounding omental fat. Pancreatic duct and capsular contour were acceptably normal and parenchyma respected normal curvilinear patterns. No overt evidence of active inflammatory or neoplastic disease was noted.

**BREED**

Beagle Mix

**ULTRASONOGRAPHIC FINDINGS**

**SEX**

Spayed female

Persistently prominent caudate process, likely normal variant.

Excessive gallbladder debris, mild subjective improvement compared to the prior sonogram.

**AGE**

11 years

**INTERPRETATION OF THE FINDINGS & FURTHER RECOMMENDATIONS**

Ursodiol therapy should be continued along with gallbladder motility study to assess gallbladder function.

**WEIGHT**

**INTERPRETED BY**

Eric Lindquist, DMV  
DABVP, Cert. IVUSS

**IMAGING PERFORMED BY**

Valeryia Shumskaya

**HOSPITAL NAME**

Blairstown AH

**REFERRING VET**

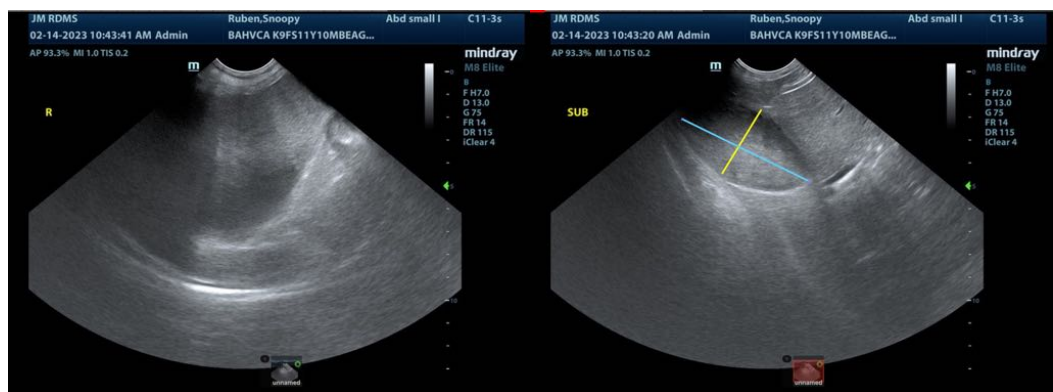
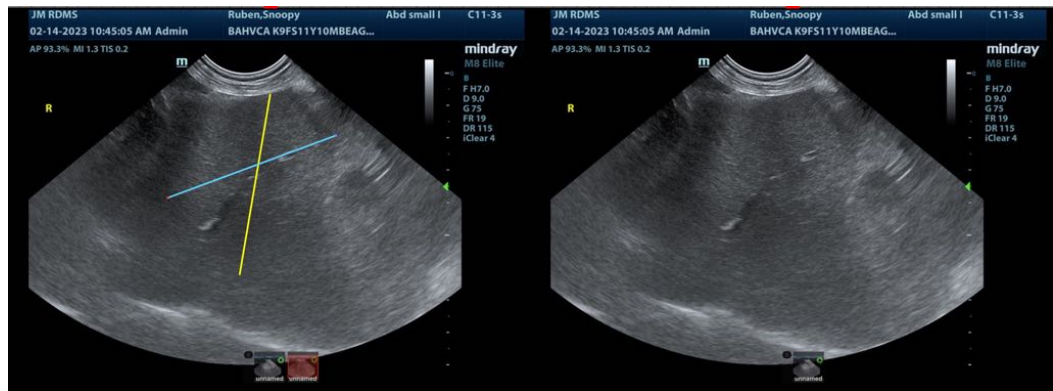
Dr. Lovell

**INVOICE**

42802

**DATE**

2/14/23





**PATIENT**

Snoopy Ruben

**SPECIES**

Canine

**BREED**

Beagle Mix

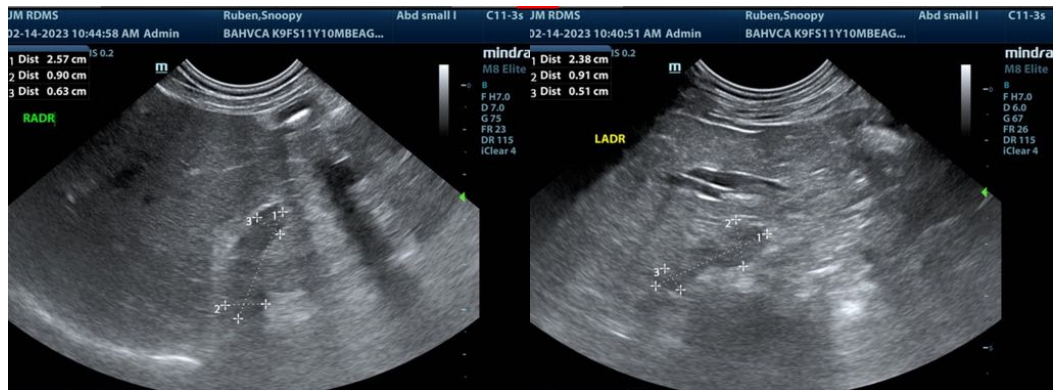
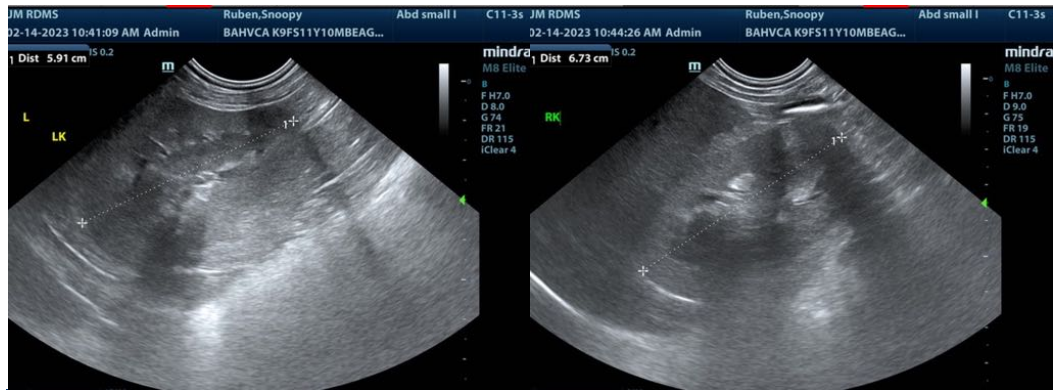
**SEX**

Spayed female

**AGE**

11 years

**WEIGHT**



**INTERPRETED BY**

Eric Lindquist, DMV  
DABVP, Cert. IVUSS

**IMAGING PERFORMED BY**

Valeryia Shumskaya

**HOSPITAL NAME**

Blairstown AH

**REFERRING VET**

Dr. Lovell

**INVOICE**

42802

**DATE**

2/14/23

The information and recommendations provided are based on the images presented by the referring veterinarian/sonographer. No evaluation can be communicated regarding pathology that was not visible in the image/video clips provided.

Thank you for this referral. If the clinical or image interpretation does not parallel your findings or if I can be of any further assistance please contact me.

**Eric Lindquist**, DMV, DABVP, Cert. IVUSS, CEO of SonoPath.com  
info@SonoPath.com