



PATIENT

Brewster Tode

PRESENTING CLINICAL SIGNS

Chronic intermittent vomiting.
Chem/CBC normal

SPECIES

Canine

ULTRASONOGRAPHIC EXAMINATION OF THE ABDOMEN

Urinary System

BREED

Labradoodle

The **urinary bladder** and visible pelvic urethra were unremarkable for the level of repletion presented. The urine, however, did present some mildly echogenic debris consistent with mucous, exfoliated cells from renal or bladder origin, and/or blood clots as these echogenic changes can all present similarly. This is often related to urinary tract infection but may represent simple evidence of exfoliated debris or sterile inflammation. Cystocentesis, urinalysis, +/- culture would be recommended to rule out and define any UTI.

SEX

Neutered male

The residual prostate measured 0.7 cm.

AGE

4 years

The **kidneys** revealed normal size and structure, corticomedullary definition and ratio for this age. The cortices presented largely uniform texture with normal echogenic relationship to liver and spleen. Medullary structure differed distinctly from the cortex and no evidence of pelvic dilation was present. The capsules were acceptably uniform without significant irregularities. The left kidney measured 6.94 cm. The right kidney measured 6.15 cm.

INTERPRETED BY

Eric Lindquist, DMV
DABVP, Cert. IVUSS

Adrenal Glands

IMAGING PERFORMED BY

Eric Lindquist, DMV
DABVP, Cert. IVUSS

Both **adrenal glands** were visualized and recognized as having normal shape, size, position and echogenicity for this breed. The phrenic vasculature, glandular echogenicity and detail were unremarkable. Capsule, cortex, and medullary definition were normal for this age patient. The left adrenal gland measured 2.26 x 0.53 cm. The right adrenal gland measured 2.19 x 0.73 cm.

HOSPITAL NAME

Franklin Lakes AH

Spleen

REFERRING VET

Dr. Hudson

The **spleen** presented a smooth homogeneous parenchyma hyperechoic to liver and renal cortical parenchyma. The capsule was smooth without noticeable expansion or deviation from within the spleen or adjacent pathology. The splenic vasculature demonstrated normal volume without signs of congestion or thrombosis. No sonographic evidence of acute or chronic inflammatory, neoplastic, or infarctual changes was noted.

INVOICE

42783

Liver

DATE

2/14/23

The **liver** images submitted revealed subjectively normal liver size, contour, and structure. Parenchymal echogenicity was naturally coarse and hypoechoic to the spleen. Vascular and biliary tracts were of normal volume with no evidence of congestion. The gallbladder presented acceptably thin walls with primarily anechoic content. The cystic and common bile ducts were normal. No pathological hepatic lymphadenopathy was evident. No overt structural evidence of inflammatory, infiltrative or regenerative pathology was evident.



PATIENT

Gastrointestinal

Brewster Tode

Examination of the **gastrointestinal tract** revealed a stomach and intestine free of stasis, of normal wall thickness, acceptable curvilinear mural detail, and peristaltic activity. Small and large intestine demonstrated normal luminal chyme and stool consistency respectively. No obstructive or overt infiltrative disease was noted. No associated abnormal lymphatic activity was noted.

SPECIES

Canine

Pancreas

BREED

Labradoodle

The base and limbs of the **pancreas** were observed to be largely isoechoic to surrounding omental fat. Pancreatic duct and capsular contour were acceptably normal and parenchyma respected normal curvilinear patterns. No overt evidence of active inflammatory or neoplastic disease was noted.

SEX

Neutered male

ULTRASONOGRAPHIC FINDINGS

Structurally unremarkable abdomen with bladder debris.

AGE

4 years

INTERPRETATION OF THE FINDINGS & FURTHER RECOMMENDATIONS

Dietary indiscretion, food intolerance, structurally significant inflammatory bowel or occult parasitism and occult Addison's are all potentials.

INTERPRETED BY

Eric Lindquist, DMV
DABVP, Cert. IVUSS

IMAGING PERFORMED BY

Eric Lindquist, DMV
DABVP, Cert. IVUSS

HOSPITAL NAME

Franklin Lakes AH

REFERRING VET

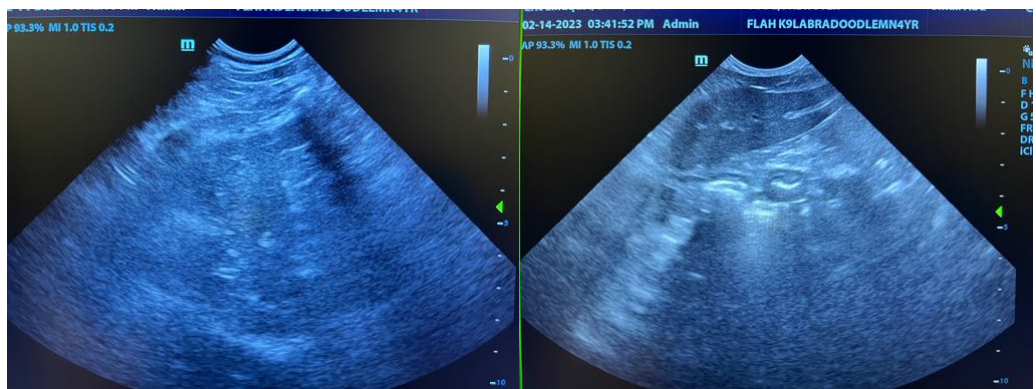
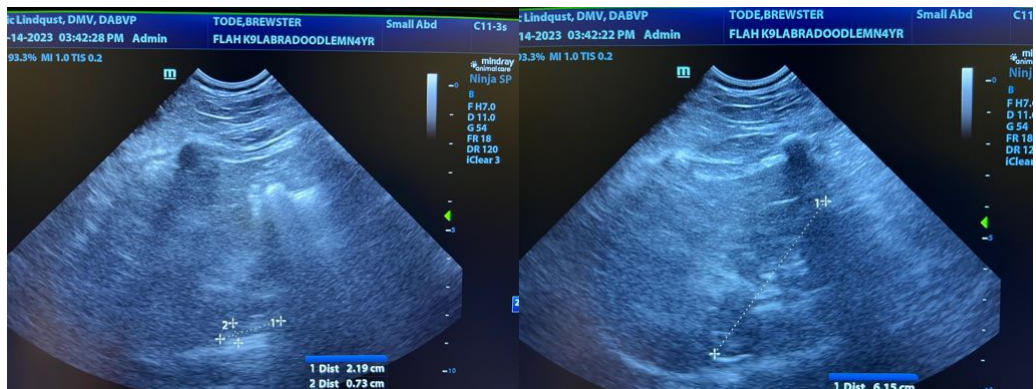
Dr. Hudson

INVOICE

42783

DATE

2/14/23





PATIENT

Brewster Tode

SPECIES

Canine

BREED

Labradoodle

SEX

Neutered male

AGE

4 years

INTERPRETED BY

Eric Lindquist, DMV
DABVP, Cert. IVUSS

IMAGING PERFORMED BY

Eric Lindquist, DMV
DABVP, Cert. IVUSS

HOSPITAL NAME

Franklin Lakes AH

REFERRING VET

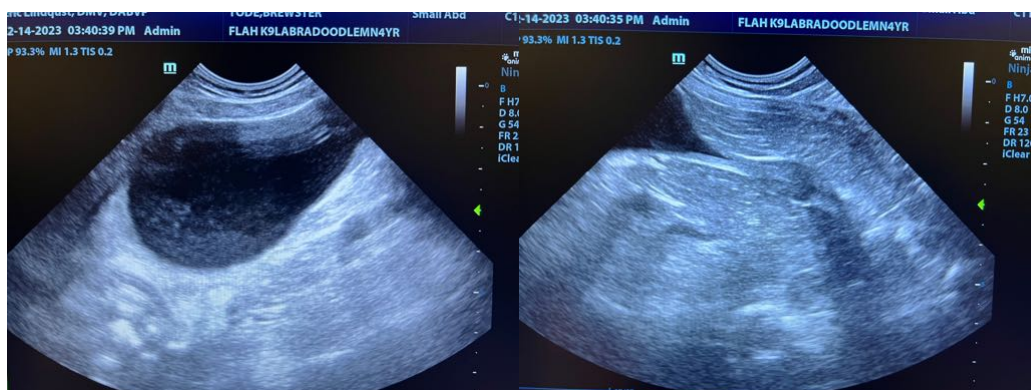
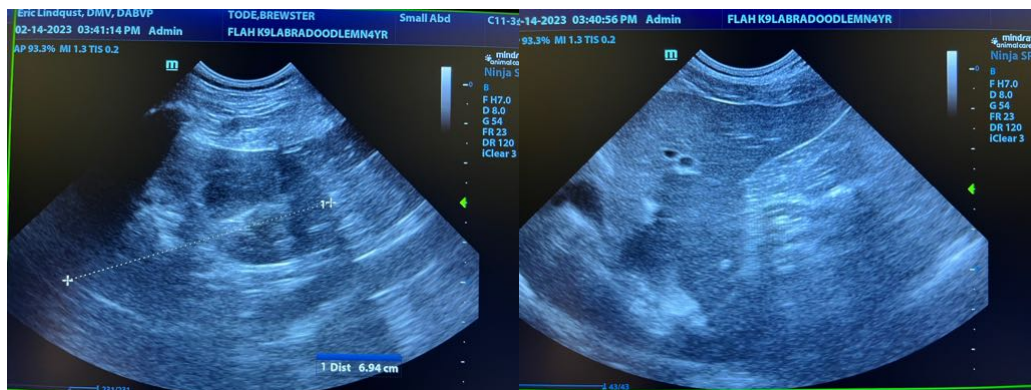
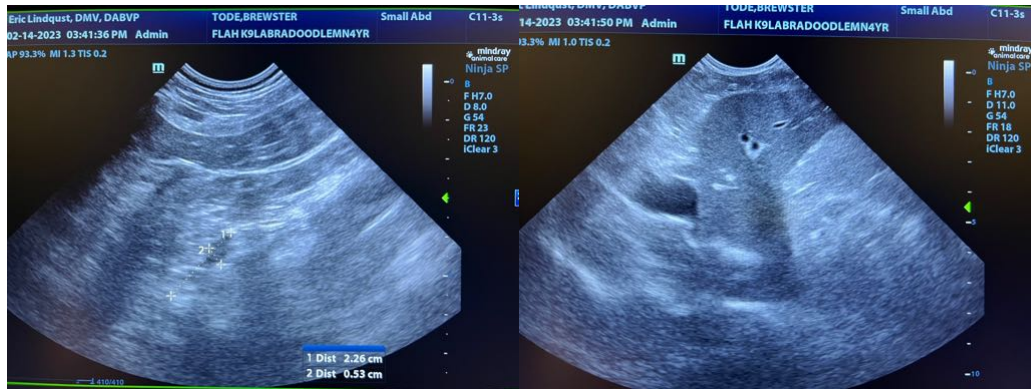
Dr. Hudson

INVOICE

42783

DATE

2/14/23



The information and recommendations provided are based on the images presented by the referring veterinarian/sonographer. No evaluation can be communicated regarding pathology that was not visible in the image/video clips provided.

Thank you for this referral. If the clinical or image interpretation does not parallel your findings or if I can be of any further assistance please contact me.

Eric Lindquist, DMV, DABVP, Cert. IVUSS, CEO of SonoPath.com
Info@SonoPath.com