



PATIENT PRESENTING CLINICAL SIGNS

Wallace Wiley

History: Heart murmur III/VI mitral, coughing

SPECIES ULTRASONOGRAPHIC EXAMINATION OF THE HEART

Canine

BREED

Beagle

SEX

Neutered male

AGE

7 years

WEIGHT

41 lbs

INTERPRETED BY

Eric Lindquist, DMV
DABVP, Cert. IVUSS

IMAGING PERFORMED BY

Jessica Miller, RDMS

HOSPITAL NAME

The Gentle Vet

REFERRING VET

Dr. Dulude

INVOICE

42702

DATE

2/10/23

The echocardiogram in this patient demonstrated normal **left atrial** size based on 3 different LA measurement methods. Chamber volumes and echogenicity were normal. The cranial and caudal **mitral** valve leaflets presented vegetative thickening consistent with endocardiosis. Doppler indicated measurable insufficiency. The **left ventricle** presented thicknesses with linear contour and was not dilated nor restricted. The **myocardium** presented normal echogenicity without subjective evidence of significant fibrotic or ischemic disease. **Contractility** of the ventricular walls was adequate and in normal range for this patient evidenced by the fractional shortening measurement and subjective evaluation of the different regions of the myocardium. The **left ventricular outflow** tract demonstrated normal laminar flow and subjective structural integrity. The **right atrium** and auricle revealed normal size, structure and content. No evidence of masses was noted or chamber overload. **Tricuspid** insufficiency was noted. The **right ventricle** was of normal size (1/3 diameter of LV), chordae structure, myocardial echogenicity and thickness. **Pulmonic** tract assessment revealed normal valve structure, laminar flow, and diameter (approx. 1:1 pa/ao ratio). No visible **pericardial** or free pleura fluid was noted. No echographically detectable evidence of infiltrative disease was visible. The cranial **mediastinum and pericardial regions** were free of masses in the visible window.

| CANINE CARDIAC PARAMETERS | MR VMAX (m/s) | TR VMAX (m/s) | LA/AO (Boon method) | LA/AO (Heart Base) | FS (%) | EF (%) | EPSS (cm) |
|---------------------------|---------------|---------------|---------------------|--------------------|-----------------------------------|--|--|
| NORMAL PARAMETER | 4.5-5.5 | <2.7 | 1.3 | <1.6 | 28-40 | 40-100 | <0.6 |
| PATIENT | 5.86 | 2.0 | 1.15 | 1.13 | 45 | 77 | 0.1 |
| CANINE CARDIAC PARAMETERS | HR (BPM) | AV VMAX (m/s) | PV MAX (m/s) | BODY WEIGHT | LA (2D short axis Base view) (cm) | LVIDd (Avg; 2D and m-mode short axis) (cm) | LVIDs (Avg; 2D and m-mode short axis) (cm) |
| NORMAL PARAMETER | 50-100 | 0.7-1.7 | 0.7-1.6 | BELOW | BELOW | BELOW | BELOW |
| PATIENT | 171 | 1.33 | 1.09 | 41 lbs | 3.3 max | 3.73 | |



PATIENT

Wallace Wiley

ULTRASONOGRAPHIC FINDINGS

Stage B1 valvular disease, compensated.

SPECIES

Canine

INTERPRETATION OF THE FINDINGS & FURTHER RECOMMENDATIONS

There was no evidence of volume overload. No treatment is recommended at this time.

BREED

Beagle

The heart is stable without clinical disease. No overt contraindication for anesthesia of brief to moderate duration. I suggest Torbutrol premed, Propofol induction, Isoflo maintenance or similar protocol if anesthesia is desired. Blood pressure recommended if not already performed and target white coat negative systolic pressure of < 160 mmHg. If higher than this ACE-inhibitor is suggested to reach this level. Recheck echocardiogram is recommended in 6 months, earlier if murmur grade increases or clinical signs initiate.

SEX

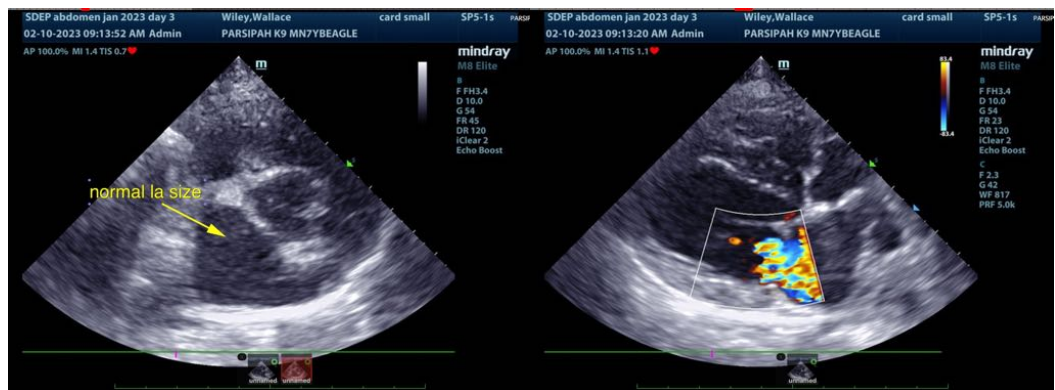
Neutered male

AGE

7 years

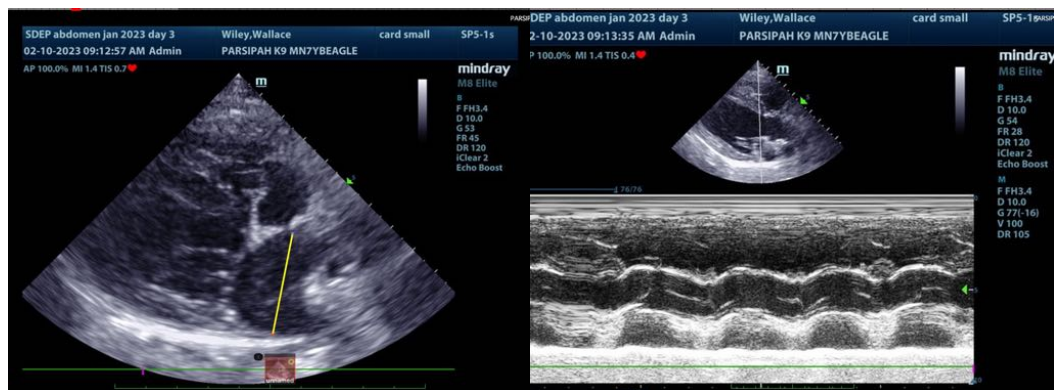
WEIGHT

41 lbs



INTERPRETED BY

Eric Lindquist, DMV
DABVP, Cert. IVUSS



IMAGING PERFORMED BY

Jessica Miller, RDMS

HOSPITAL NAME

The Gentle Vet

REFERRING VET

Dr. Dulude

INVOICE

42702

DATE

2/10/23



PATIENT

Wallace Wiley

SPECIES

Canine

BREED

Beagle

SEX

Neutered male

AGE

7 years

WEIGHT

41 lbs

INTERPRETED BY

Eric Lindquist, DMV
DABVP, Cert. IVUSS

IMAGING PERFORMED BY

Jessica Miller, RDMS

HOSPITAL NAME

The Gentle Vet

REFERRING VET

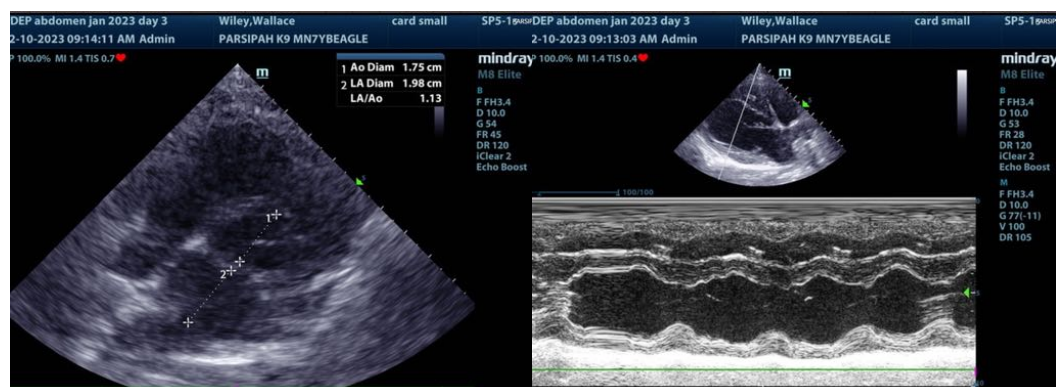
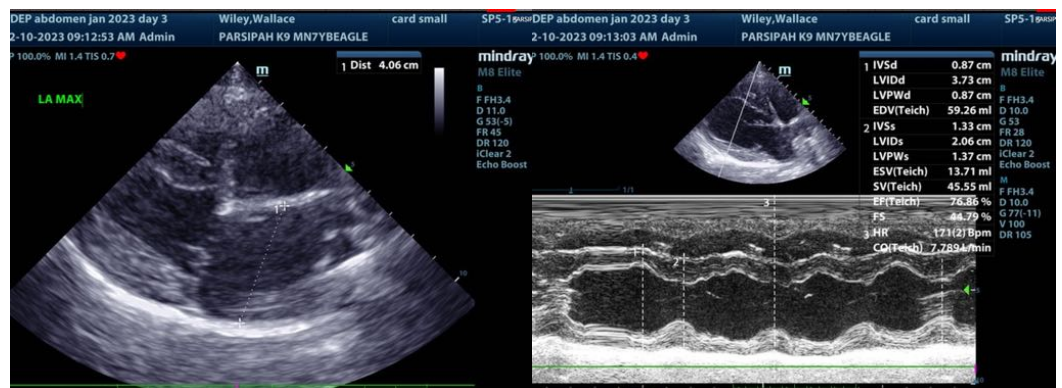
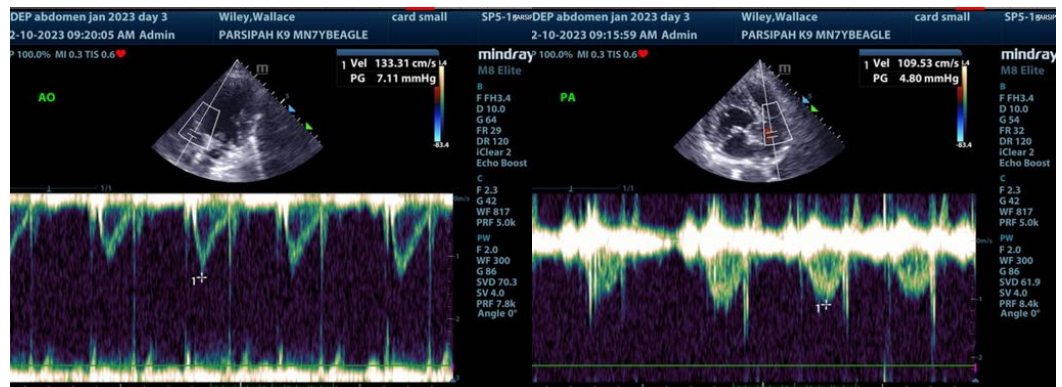
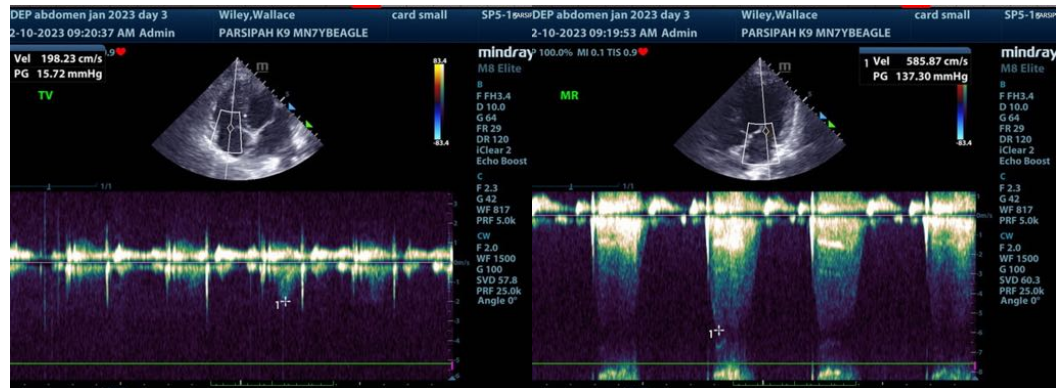
Dr. Dulude

INVOICE

42702

DATE

2/10/23





PATIENT

Wallace Wiley

The information and recommendations provided are based on the images presented by the referring veterinarian/sonographer. No evaluation can be communicated regarding pathology that was not visible in the image/video clips provided.

SPECIES

Canine

Thank you for this referral. If the clinical or image interpretation does not parallel your findings or if I can be of any further assistance please contact me.

Eric Lindquist, DMV, DABVP, Cert. IVUSS, CEO of SonoPath.com
info@SonoPath.com

BREED

Beagle

SEX

Neutered male

AGE

7 years

WEIGHT

41 lbs

INTERPRETED BY

Eric Lindquist, DMV
DABVP, Cert. IVUSS

**IMAGING
PERFORMED BY**

Jessica Miller, RDMS

HOSPITAL NAME

The Gentle Vet

REFERRING VET

Dr. Dulude

INVOICE

42702

DATE

2/10/23