



PATIENT

Miley Gintile Dulude

PRESENTING CLINICAL SIGNS

History: Vomiting- can palpate stool in colon? Our x-ray machine broken- foreign body?
Abnormal PE/Chem/CBC/UA Results: pending

SPECIES

Canine

ULTRASONOGRAPHIC EXAMINATION OF THE ABDOMEN

Urinary System

BREED

Mix

The **urinary bladder**, trigone, and pelvic urethra presented normal thicknesses and normal tone. The ureters were not visible which is normal. No uroliths or sediment were visualized and anechoic urine was present. No evidence of inflammatory or neoplastic changes was noted. Ureteral papillae were normal.

SEX

Female

The **kidneys** revealed normal size and structure, corticomedullary definition and ratio for this age. The cortices presented largely uniform texture with normal echogenic relationship to liver and spleen. Medullary structure differed distinctly from the cortex and no evidence of pelvic dilation was present. The capsules were acceptably uniform without significant irregularities. The left kidney measured 6.24 cm. The right kidney measured 6.0 cm.

AGE

5 months

Adrenal Glands

WEIGHT

30 lbs

Both **adrenal glands** were visualized and recognized as having normal shape, size, position and echogenicity for this breed. The phrenic vasculature, glandular echogenicity and detail were unremarkable. Capsule, cortex, and medullary definition were normal for this age patient. The right adrenal gland measured 2.57 x 0.75 cm at the cranial pole and 0.58 cm at the caudal pole. The left adrenal gland measured 2.4 x 0.47 cm at the caudal pole and 0.42 cm at the cranial pole.

INTERPRETED BY

Eric Lindquist, DMV
DABVP, Cert. IVUSS

Spleen

IMAGING PERFORMED BY

Jessica Miller, RDMS

The **spleen** presented a smooth homogeneous parenchyma hyperechoic to liver and renal cortical parenchyma. The capsule was smooth without noticeable expansion or deviation from within the spleen or adjacent pathology. The splenic vasculature demonstrated normal volume without signs of congestion or thrombosis. No sonographic evidence of acute or chronic inflammatory, neoplastic, or infarctual changes was noted.

HOSPITAL NAME

Parsippany Troy Hills
AH

Liver

REFERRING VET

Dr. Dulude

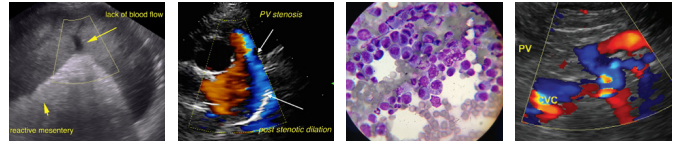
The **liver** images submitted revealed subjectively normal liver size, contour, and structure. Parenchymal echogenicity was naturally coarse and hypoechoic to the spleen. Vascular and biliary tracts were of normal volume with no evidence of congestion. The gallbladder presented acceptably thin walls with primarily anechoic content. The cystic and common bile ducts were normal. No pathological hepatic lymphadenopathy was evident. No overt structural evidence of inflammatory, infiltrative or regenerative pathology was evident.

INVOICE

42686

DATE

2/10/23



PATIENT

Miley Gintile Dulude

SPECIES

Canine

BREED

Mix

SEX

Female

AGE

5 months

WEIGHT

30 lbs

INTERPRETED BY

Eric Lindquist, DMV
DABVP, Cert. IVUS

IMAGING PERFORMED BY

Jessica Miller, RDMS

HOSPITAL NAME

Parsippany Troy Hills
AH

REFERRING VET

Dr. Dulude

INVOICE

42686

DATE

2/10/23

Gastrointestinal

The **stomach** revealed a mild amount of chyme. A minor amount of chyme was noted in the stomach. The pylorus was patent with no evidence of obstruction. The small intestine was peristaltic. This is consistent with enteritis. The mesenteric lymph nodes were reactive and measured 4.6 x 0.68 cm.

Pancreas

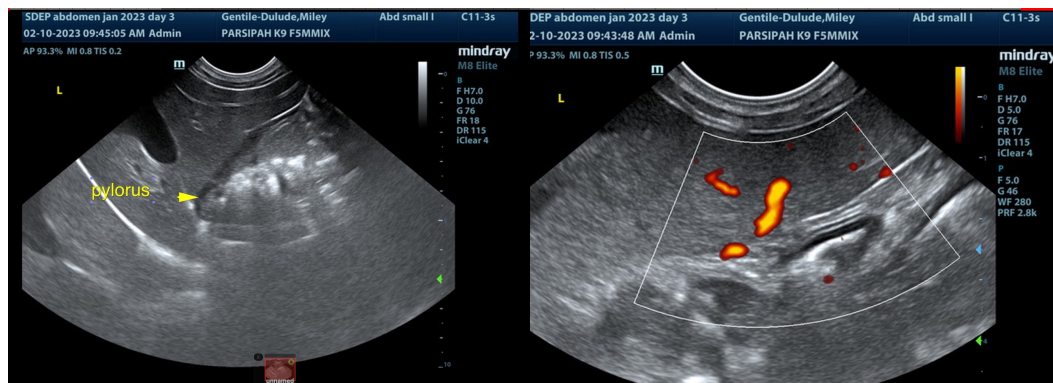
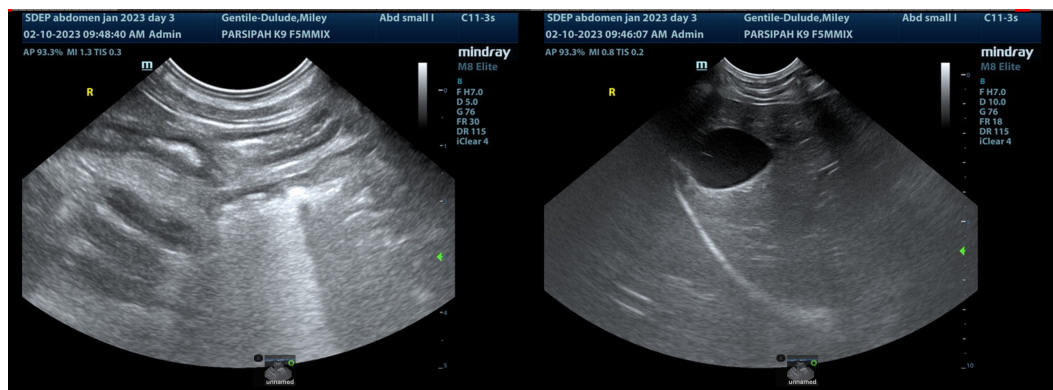
The base and limbs of the **pancreas** were observed to be largely isoechoic to surrounding omental fat. Pancreatic duct and capsular contour were acceptably normal and parenchyma respected normal curvilinear patterns. No overt evidence of active inflammatory or neoplastic disease was noted.

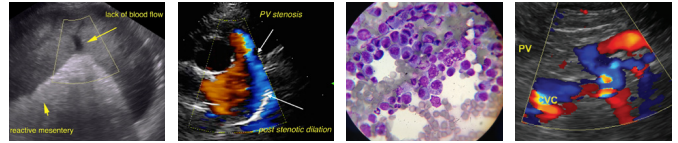
ULTRASONOGRAPHIC FINDINGS

Gastroenteritis with reactive mesenteric lymph nodes.

INTERPRETATION OF THE FINDINGS & FURTHER RECOMMENDATIONS

There was no evidence of foreign body, intussusception or other obstructive disease. Supportive care should prove effective.





PATIENT

Miley Gintile Dulude

SPECIES

Canine

BREED

Mix

SEX

Female

AGE

5 months

WEIGHT

30 lbs

INTERPRETED BY

Eric Lindquist, DMV
DABVP, Cert. IVUSS

IMAGING PERFORMED BY

Jessica Miller, RDMS

HOSPITAL NAME

Parsippany Troy Hills
AH

REFERRING VET

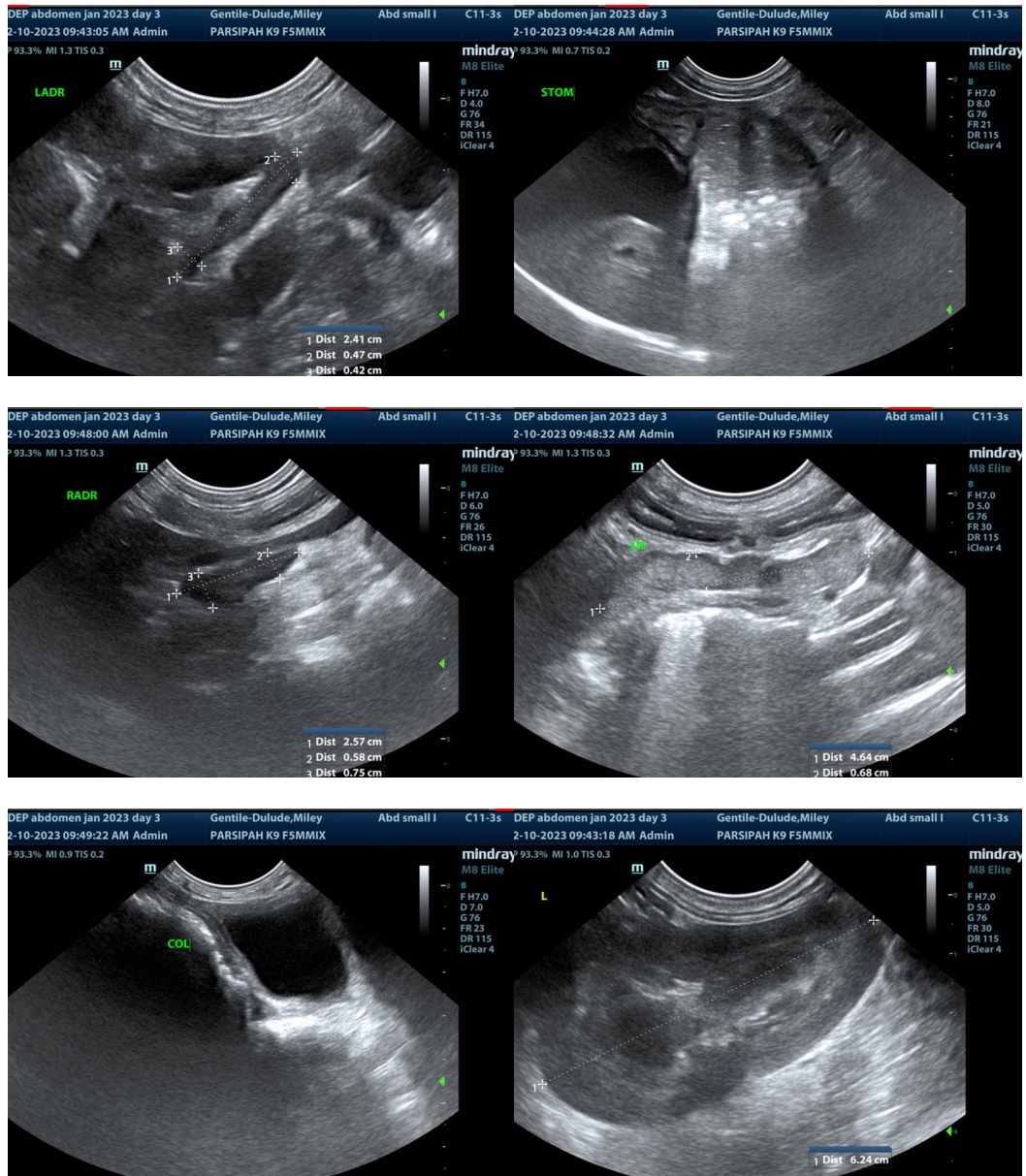
Dr. Dulude

INVOICE

42686

DATE

2/10/23



The information and recommendations provided are based on the images presented by the referring veterinarian/sonographer. No evaluation can be communicated regarding pathology that was not visible in the image/video clips provided.

Thank you for this referral. If the clinical or image interpretation does not parallel your findings or if I can be of any further assistance please contact me.

Eric Lindquist, DMV, DABVP, Cert. IVUSS, CEO of SonoPath.com
info@SonoPath.com