



PATIENT PRESENTING CLINICAL SIGNS

Blu Robinson

History: mass located on right ischial area, to right of right anal gland. US to determine if it is a true mass +/- cytology, vs fluid. Unchanged after antibiotics and nsaid. FNA 25g and 22 g performed.

SPECIES

Canine

ULTRASONOGRAPHIC EXAMINATION

BREED

Boxer

The right anal gland lumen was fluid filled with no evidence of pathology.

SEX

Neutered male

The pelvic region was imaged in this patient and revealed a soft tissue mass in the subcutaneous region of the attenuating sound beam present. The mass measured 3.5-4.0 cm and appears to be somewhat encapsulated. The mass is adjacent to the right anal gland, yet not related to it. There is a strong concern for sarcoma. Ultrasound-guided FNA was performed without complication.

AGE

7 years

ULTRASONOGRAPHIC FINDINGS

Muscle base or soft tissue sarcoma, potentially resectable.

WEIGHT

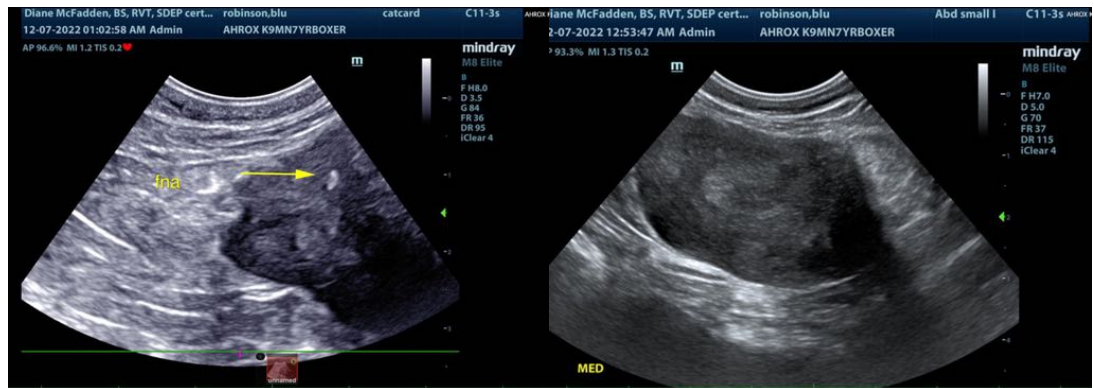
93.4 lbs

INTERPRETATION OF THE FINDINGS & FURTHER RECOMMENDATIONS

Abdominal and thoracic ultrasound with radiographs +/- CT would be ideal as this mass may be a focal manifestation of a multi-centric process. There is a strong concern for round cell neoplasia with necrosis. The mass appears to be circumscribed and potentially resectable if no comorbidity is present.

INTERPRETED BY

Eric Lindquist, DMV
DABVP, Cert. IVUSS



IMAGING PERFORMED BY

Diane McFadden, RVT

HOSPITAL NAME

Animal Hospital of
Roxbury

REFERRING VET

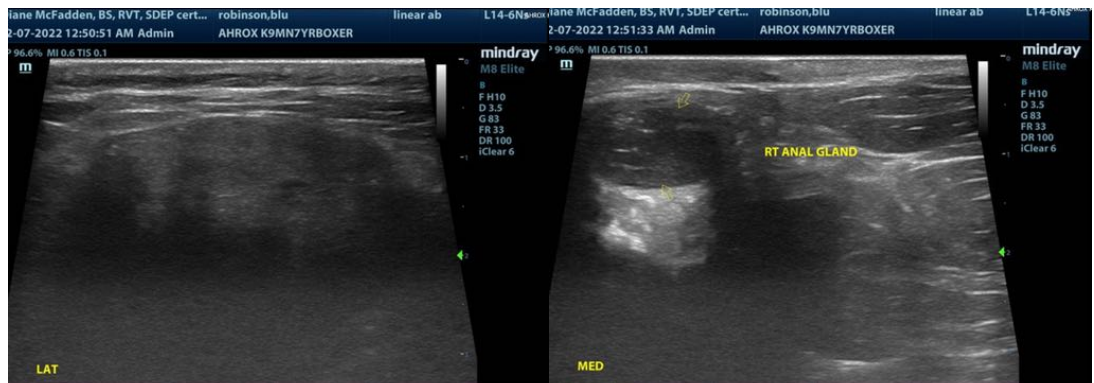Dr Flia

INVOICE

42905

DATE

12/6/22





PATIENT

Blu Robinson

SPECIES

Canine

BREED

Boxer

SEX

Neutered male

AGE

7 years

WEIGHT

93.4 lbs

INTERPRETED BY

Eric Lindquist, DMV
DABVP, Cert. IVUSS

**IMAGING
PERFORMED BY**

Diane McFadden, RVT

HOSPITAL NAME

Animal Hospital of
Roxbury

REFERRING VET

Dr. Flia

INVOICE

42905

DATE

12/6/22

The information and recommendations provided are based on the images presented by the referring veterinarian/sonographer. No evaluation can be communicated regarding pathology that was not visible in the image/video clips provided.

Thank you for this referral. If the clinical or image interpretation does not parallel your findings or if I can be of any further assistance please contact me.

Eric Lindquist, DMV, DABVP, Cert. IVUSS, CEO of SonoPath.com
Info@SonoPath.com