



PATIENT

Roger Rezach

SPECIES

Canine

BREED

Yorkshire Terrier

SEX

Neutered male

AGE

11 years

WEIGHT

PRESENTING CLINICAL SIGNS

History: Seen at other DVM and diagnosed with splenic mass; second opinion today.
Abnormal PE/Chem/CBC/UA Results: CBC: WNL. Chem: elevated liver enzymes.

ULTRASONOGRAPHIC EXAMINATION OF THE ABDOMEN

Urinary System

The **urinary bladder**, trigone, and pelvic urethra presented normal thicknesses and normal tone. The ureters were not visible which is normal. No uroliths or sediment were visualized and anechoic urine was present. No evidence of inflammatory or neoplastic changes was noted. Ureteral papillae were normal.

The residual prostate was uniform and measured 0.6 cm.

The **kidneys** revealed largely normal size and structure, corticomedullary definition and ratio (cortex 1/3 of medulla) were essentially maintained with some age-related loss of curvilinear patterns regarding the capsule and C/M junction. The cortices presented largely uniform texture with some increased echogenicity expected for his age patient. Medullary structure differed distinctly from that of the cortex and no evidence of pelvic dilation was present. Mineralization was noted in the kidneys. The right kidney measured 3.56 cm. The left kidney measured 3.8 cm.

Adrenal Glands

Both **adrenal glands** were visualized and recognized as having normal shape, size, position and echogenicity for this breed. The phrenic vasculature, glandular echogenicity and detail were unremarkable. Capsule, cortex, and medullary definition were normal for this age patient. The left adrenal gland measured 1.68 x 0.54 cm at the caudal pole and 0.53 cm at the cranial pole. The right adrenal gland measured 1.4 x 0.63 cm at the caudal pole and 0.54 cm at the cranial pole.

Spleen

The **spleen** revealed a cystic mass that measured 2.5 cm and was deriving from the mid cranial body. The splenic mass appeared to be solitary and may be benign.

Liver

The **liver** images from right and left intercostal as well as subcostal views revealed subjectively normal liver size, contour, and structure. Some age-related parenchymal remodeling was noted but likely not clinically significant at this time. Vascular and biliary tracts were of normal volume and no evidence of congestion was noted. The gallbladder was mildly over distended with suspended and dependent debris, yet not to the level of emerging mucocele, yet sludge appears to be mildly excessive. No adjunctive inflammation was noted.

INTERPRETED BY

Eric Lindquist, DMV,
DABVP, Cert. IVUSS,
CEO of SonoPath.com

IMAGING PERFORMED BY

Kelly Vazquez, CVT

HOSPITAL NAME

New Bridge VP

REFERRING VET

Dr. Glennon

INVOICE

42860

DATE

12/5/22



PATIENT

Roger Rezach

SPECIES

Canine

BREED

Yorkshire Terrier

SEX

Neutered male

AGE

11 years

WEIGHT

Gastrointestinal

Examination of the **gastrointestinal tract** revealed a stomach and intestine free of stasis, of normal wall thickness, acceptable curvilinear mural detail, and peristaltic activity. Small and large intestine demonstrated normal luminal chyme and stool consistency respectively. No obstructive or overt infiltrative disease was noted. No associated abnormal lymphatic activity was noted.

Pancreas

The base and limbs of the **pancreas** were observed to be largely isoechoic to surrounding omental fat. Pancreatic duct and capsular contour were acceptably normal and parenchyma respected normal curvilinear patterns. No overt evidence of active inflammatory or neoplastic disease was noted.

Heart

Rapid view of the heart revealed no evidence of pathology in the right auricle or pericardium.

ULTRASONOGRAPHIC FINDINGS

Cystic splenic mass. Solitary hemangiosarcoma versus cystic hyperplasia or other benign lesion. Splenic abscess is less likely.

INTERPRETED BY

Eric Lindquist, DMV,
DABVP, Cert. IVUSS,
CEO of SonoPath.com

INTERPRETATION OF THE FINDINGS & FURTHER RECOMMENDATIONS

Chest radiographs followed by splenectomy is indicated.

IMAGING PERFORMED BY

Kelly Vazquez, CVT

HOSPITAL NAME

New Bridge VP

REFERRING VET

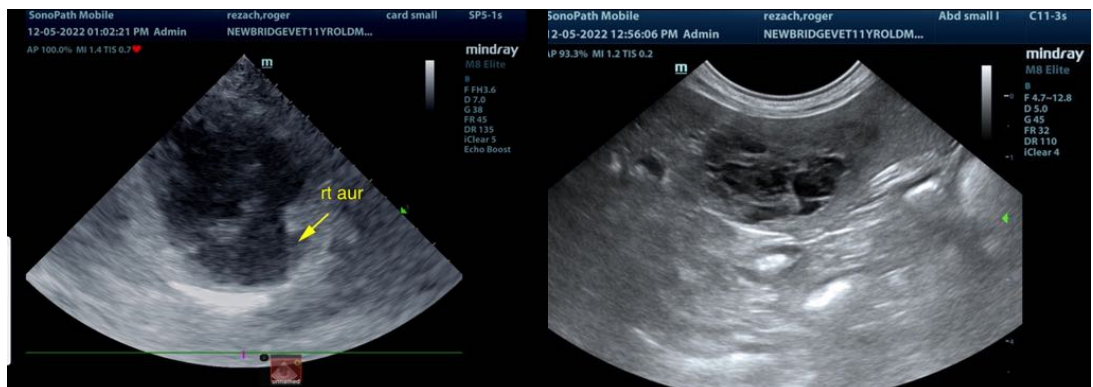
Dr. Glennon

INVOICE

42860

DATE

12/5/22





PATIENT

Roger Rezach

SPECIES

Canine

BREED

Yorkshire Terrier

SEX

Neutered male

AGE

11 years

WEIGHT

INTERPRETED BY

Eric Lindquist, DMV,
DABVP, Cert. IVUSS,
CEO of SonoPath.com

IMAGING PERFORMED BY

Kelly Vazquez, CVT

HOSPITAL NAME

New Bridge VP

REFERRING VET

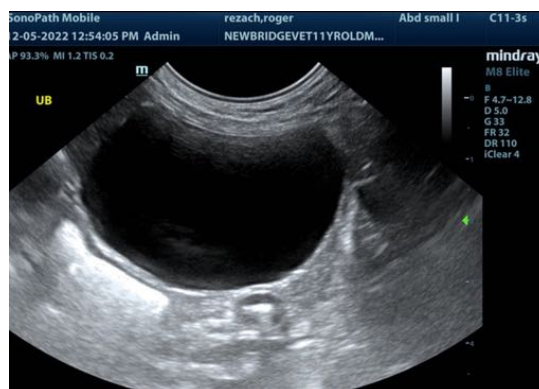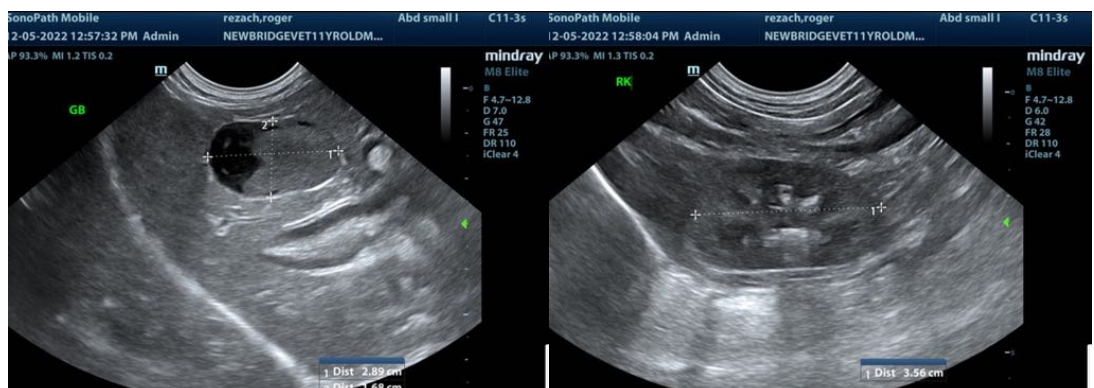
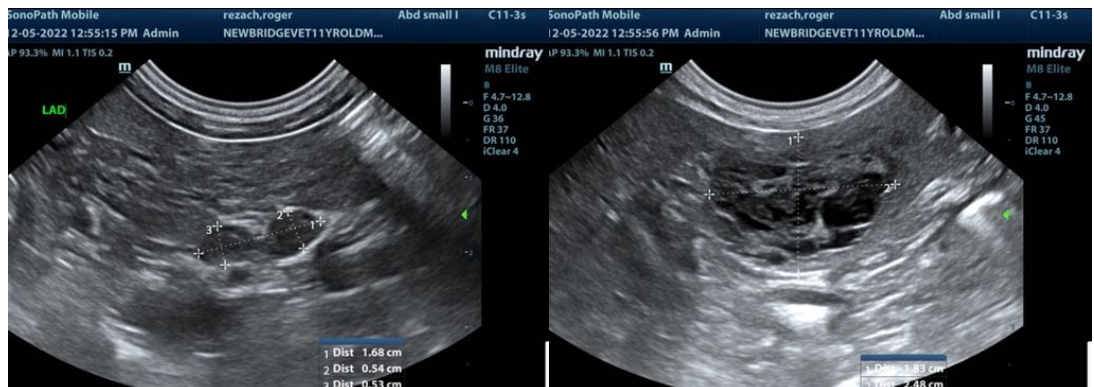
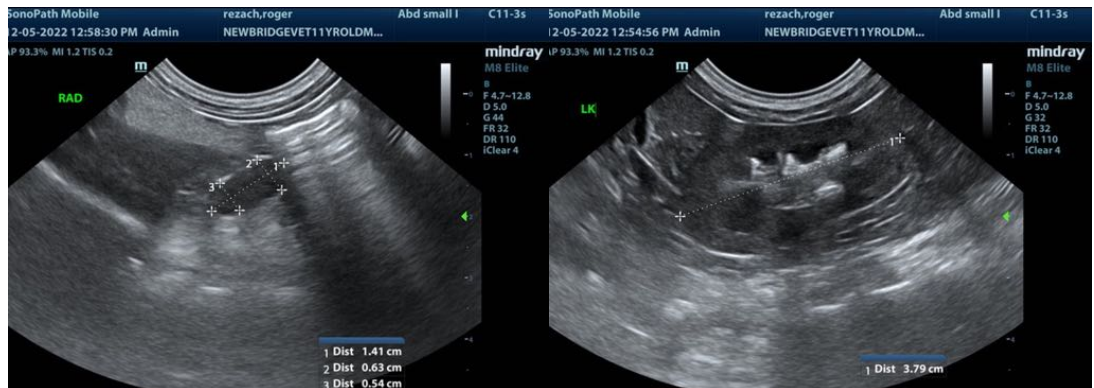
Dr. Glennon

INVOICE

42860

DATE

12/5/22





PATIENT

Roger Rezach

SPECIES

Canine

BREED

Yorkshire Terrier

SEX

Neutered male

AGE

11 years

WEIGHT

INTERPRETED BY

Eric Lindquist, DMV,
DABVP, Cert. IVUSS,
CEO of SonoPath.com

**IMAGING
PERFORMED BY**

Kelly Vazquez, CVT

HOSPITAL NAME

New Bridge VP

REFERRING VET

Dr. Glennon

INVOICE

42860

DATE

12/5/22

The information and recommendations provided are based on the images presented by the referring veterinarian/sonographer. No evaluation can be communicated regarding pathology that was not visible in the image/video clips provided.

Thank you for this referral. If the clinical or image interpretation does not parallel your findings or if I can be of any further assistance please contact me.

Eric Lindquist, DMV, DABVP, Cert. IVUSS, CEO of SonoPath.com

Info@SonoPath.com