



**PATIENT**

Ruby Siegel

**SPECIES**

Canine

**BREED**

Miniature Schnauzer

**SEX**

Spayed female

**AGE**

12 years

**WEIGHT**

**PRESENTING CLINICAL SIGNS**

History: Patient presents for history of several year ALP elevation, recent bout of inappetence, and a grade 2-3/6 left systolic heart murmur - asymptomatic. Patient needs dental under general anesthesia. Current meds: Ursodiol and Denamarin. Abnormal PE/Chem/CBC/UA Results: ALP 971.

**ULTRASONOGRAPHIC EXAMINATION OF THE ABDOMEN**

**Urinary System**

The **urinary bladder**, trigone, and pelvic urethra presented normal thicknesses and normal tone. The ureters were not visible which is normal. No uroliths or sediment were visualized and anechoic urine was present. No evidence of inflammatory or neoplastic changes was noted. Ureteral papillae were normal.

The **kidneys** revealed largely normal size and structure, corticomedullary definition and ratio (cortex 1/3 of medulla) were essentially maintained with some age-related loss of curvilinear patterns regarding the capsule and C/M junction. The cortices presented largely uniform texture with some increased echogenicity expected for his age patient. Medullary structure differed distinctly from that of the cortex and no evidence of pelvic dilation was present. Mild mineralization was noted. The left kidney measured 4.54 cm. The right kidney measured 4.62 cm.

**Adrenal Glands**

Both **adrenal glands** were visualized and recognized as having normal shape, size, position and echogenicity for this breed. The phrenic vasculature, glandular echogenicity and detail were unremarkable. Capsule, cortex, and medullary definition were normal for this age patient. The right adrenal gland measured 1.64 x 0.42 cm at the caudal pole and 0.92 cm at the cranial pole. The left adrenal gland measured 1.46 x 0.34 cm at the caudal pole and 0.35 cm at the cranial pole.

**Spleen**

The **spleen** in this patient was mildly enlarged with uniform parenchyma and was folded upon itself cranially. This is a positional variant and is not pathological. There was no evidence of significant disease.

**Liver**

The **liver** revealed coarse architecture with multi-focal, non-disruptive, hypoechoic nodular changes with gallbladder polyps. The gallbladder itself measured 3.75 x 2.14 cm. Generalized hepatic enlargement was noted.

**Gastrointestinal**

Examination of the **gastrointestinal tract** revealed a stomach and intestine free of stasis, of normal wall thickness, acceptable curvilinear mural detail, and peristaltic activity. Small and large intestine

**INTERPRETED BY**

Eric Lindquist, DMV, DABVP, Cert. IVUSS, CEO of SonoPath.com

**IMAGING PERFORMED BY**

Kelly Vazquez, CVT

**HOSPITAL NAME**

Millburn VH

**REFERRING VET**

Dr. Turowsky

**INVOICE**

42247

**DATE**

12/20/22



**PATIENT**

Ruby Siegel

demonstrated normal luminal chyme and stool consistency respectively. No obstructive or overt infiltrative disease was noted. No associated abnormal lymphatic activity was noted.

**SPECIES**

Canine

**Pancreas**

The base and limbs of the **pancreas** were observed to be largely isoechoic to surrounding omental fat. Pancreatic duct and capsular contour were acceptably normal and parenchyma respected normal curvilinear patterns. No overt evidence of active inflammatory or neoplastic disease was noted.

**BREED**

Miniature Schnauzer

**ULTRASONOGRAPHIC EXAMINATION OF THE HEART**

**SEX**

Spayed female

The echocardiogram in this patient demonstrated normal **left atrial** size based on 3 different LA measurement methods. Chamber volumes and echogenicity were normal. The cranial and caudal **mitral** valve leaflets presented vegetative thickening consistent with endocardiosis. Slight prolapse of the anterior mitral valve leaflet was noted. Doppler indicated measurable insufficiency. The **left ventricle** presented normal thicknesses with linear contour and was not dilated nor restricted. The **myocardium** presented normal echogenicity without subjective evidence of significant fibrotic or ischemic disease. **Contractility** of the ventricular walls was adequate and in normal range for this patient evidenced by the fractional shortening measurement and subjective evaluation of the different regions of the myocardium. The **left ventricular outflow** tract demonstrated normal laminar flow and subjective structural integrity. The **right atrium** and auricle revealed normal size, structure and content. No evidence of masses was noted or chamber overload. **Tricuspid** valvular assessment demonstrated adequate linear morphology. The **right ventricle** was of normal size (1/3 diameter of LV), chordae structure, myocardial echogenicity and thickness. **Pulmonic** tract assessment revealed normal valve structure, laminar flow, and diameter (approx. 1:1 pa/ao ratio). No visible **pericardial** or free pleura fluid was noted. No echographically detectable evidence of infiltrative disease was visible. The cranial **mediastinum and pericardial regions** were free of masses in the visible window.

**AGE**

12 years

**WEIGHT**

**INTERPRETED BY**

Eric Lindquist, DMV,  
DABVP, Cert. IVUSS,  
CEO of SonoPath.com

**IMAGING PERFORMED BY**

Kelly Vazquez, CVT

**HOSPITAL NAME**

Millburn VH

**REFERRING VET**

Dr. Turowsky

**INVOICE**

42247

**DATE**

12/20/22

CANINE CARDIAC PARAMETERS	MR VMAX (m/s)	TR VMAX (m/s)	LA/AO (Boon method)	LA/AO (Heart Base; Swe)	FS (%)	EF (%)	EPSS (cm)
NORMAL PARAMETER	4.5-5.5	<2.7	1.3	<1.6	28-40	40-100	<0.6
PATIENT	6.0		1.2	1.4	30	60	0.37
CANINE CARDIAC PARAMETERS	HR (BPM)	AV VMAX (m/s)	PV MAX (m/s)	BODY WEIGHT (kg)	LA (2D short axis Base view) (cm)	LVIDd (Avg; 2D and m-mode short axis) (cm)	LVIDs (Avg; 2D and m-mode short axis) (cm)
NORMAL PARAMETER	50-100	0.7-1.7	0.7-1.6	BELOW	BELOW	BELOW	BELOW
PATIENT		1.34	10.2		2.74	2.39	



**PATIENT**

Ruby Siegel

**ULTRASONOGRAPHIC FINDINGS**

Subjectively benign nodular hyperplasia liver pattern with vacuolar hepatopathy and nodular hyperplasia liver pattern.

**SPECIES**

Canine

Gallbladder polyps, subjectively benign, yet should be monitored for any progression.

**BREED**

Age related renal changes with mineralization, non-obstructive.

Stage B1 valvular disease.

**INTERPRETATION OF THE FINDINGS & FURTHER RECOMMENDATIONS**

**SEX**

Spayed female

FNA of the liver can be considered for further definition. I cannot completely rule out biliary carcinoma. Recheck of the liver is recommended in a month +/- FNA. I wish to assess the gallbladder polyps to ensure no significant progression has occurred. The polypoid changes extended for 3.2 cm.

**AGE**

12 years

The heart is stable without clinical disease. No overt contraindication for anesthesia of brief to moderate duration. I suggest Torbutrol premed, Propofol induction, Isoflor maintenance or similar protocol if anesthesia is desired. Blood pressure recommended if not already performed and target white coat negative systolic pressure of < 160 mmHg. If higher than this ACE-inhibitor is suggested to reach this level. Recheck echocardiogram is recommended in 6 months, earlier if murmur grade increases or clinical signs initiate.

**WEIGHT**

**INTERPRETED BY**

Eric Lindquist, DMV,  
DABVP, Cert. IVUSS,  
CEO of SonoPath.com

**IMAGING PERFORMED BY**

Kelly Vazquez, CVT

**HOSPITAL NAME**

Millburn VH

**REFERRING VET**

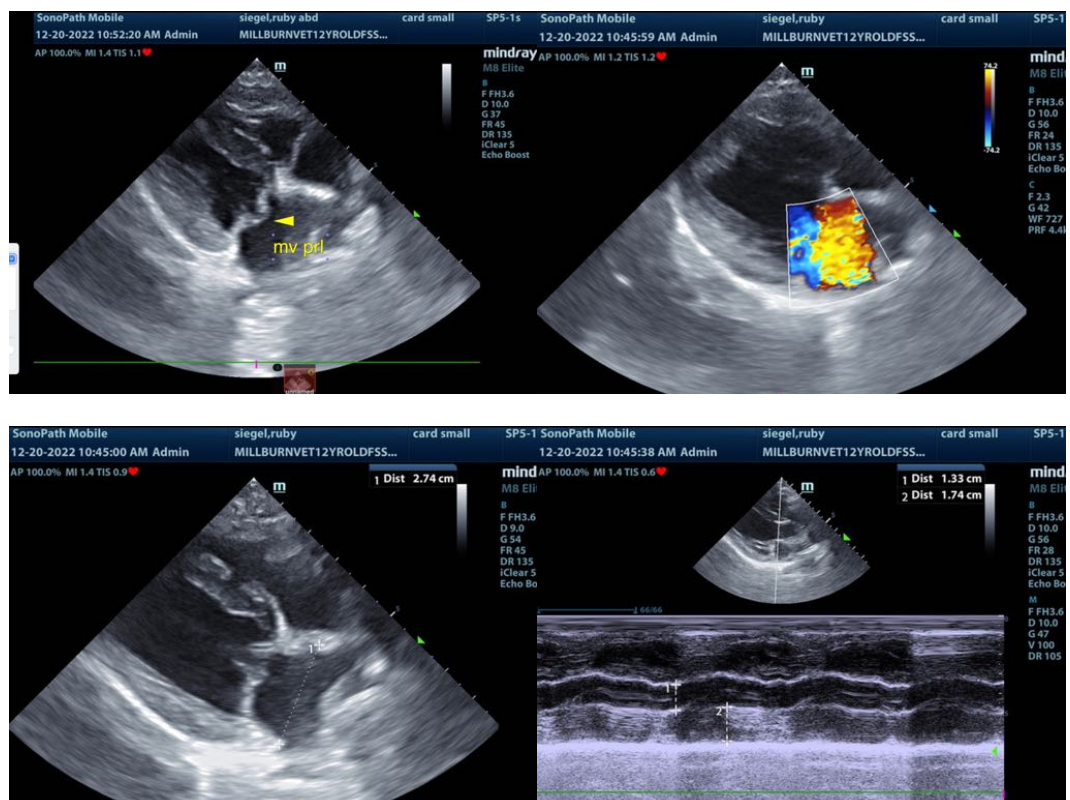
Dr. Turowsky

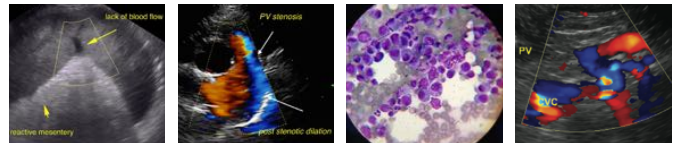
**INVOICE**

42247

**DATE**

12/20/22





**PATIENT**

Ruby Siegel

**SPECIES**

Canine

**BREED**

Miniature Schnauzer

**SEX**

Spayed female

**AGE**

12 years

**WEIGHT**

**INTERPRETED BY**

Eric Lindquist, DMV,  
DABVP, Cert. IVUSS,  
CEO of SonoPath.com

**IMAGING  
PERFORMED BY**

Kelly Vazquez, CVT

**HOSPITAL NAME**

Millburn VH

**REFERRING VET**

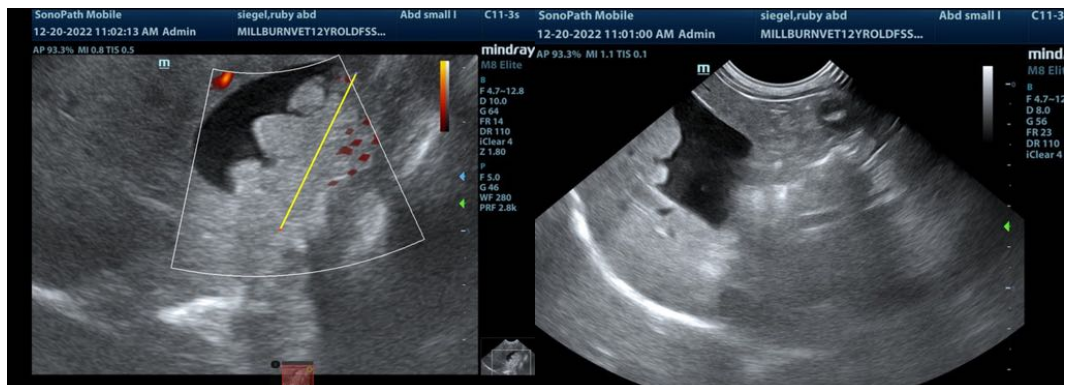
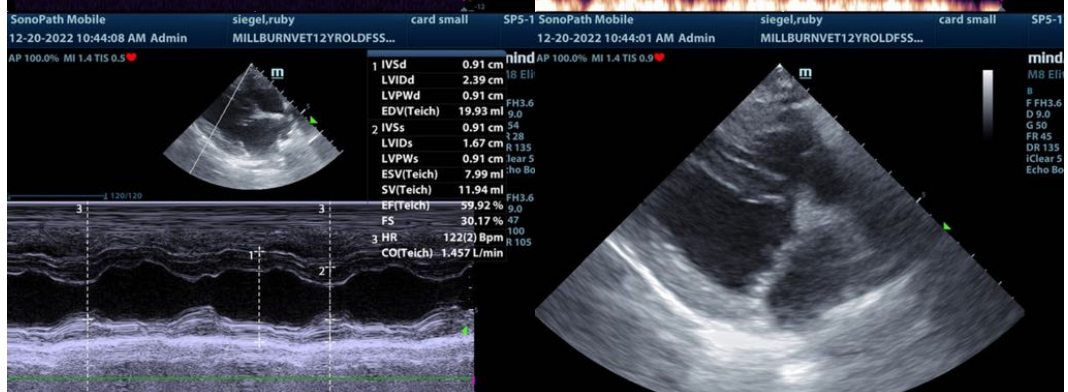
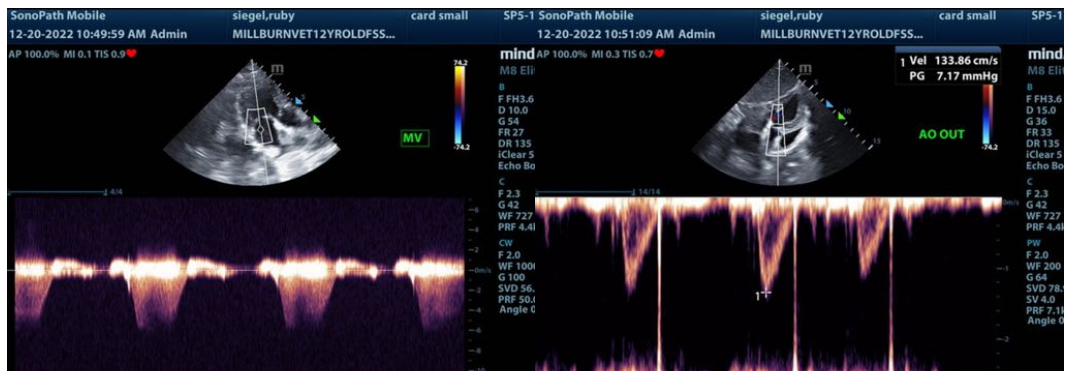
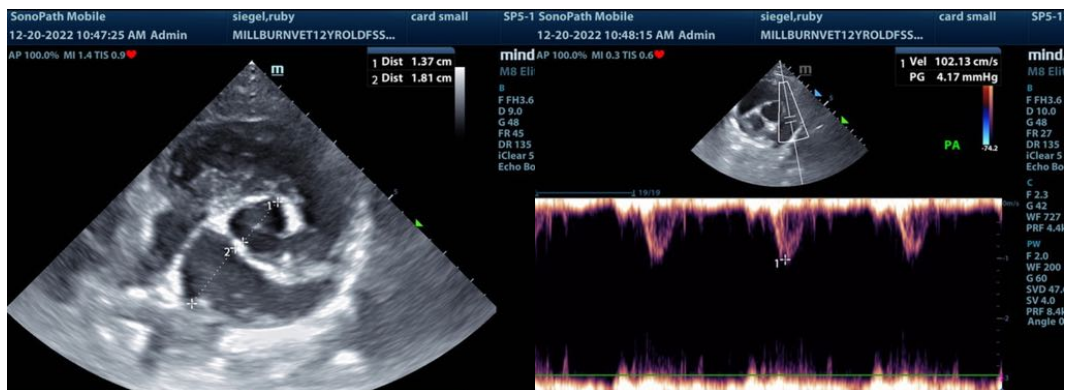
Dr. Turowsky

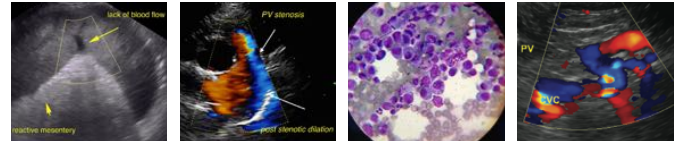
**INVOICE**

42247

**DATE**

12/20/22





**PATIENT**

Ruby Siegel

**SPECIES**

Canine

**BREED**

Miniature Schnauzer

**SEX**

Spayed female

**AGE**

12 years

**WEIGHT**

**INTERPRETED BY**

Eric Lindquist, DMV,  
DABVP, Cert. IVUSS,  
CEO of SonoPath.com

**IMAGING PERFORMED BY**

Kelly Vazquez, CVT

**HOSPITAL NAME**

Millburn VH

**REFERRING VET**

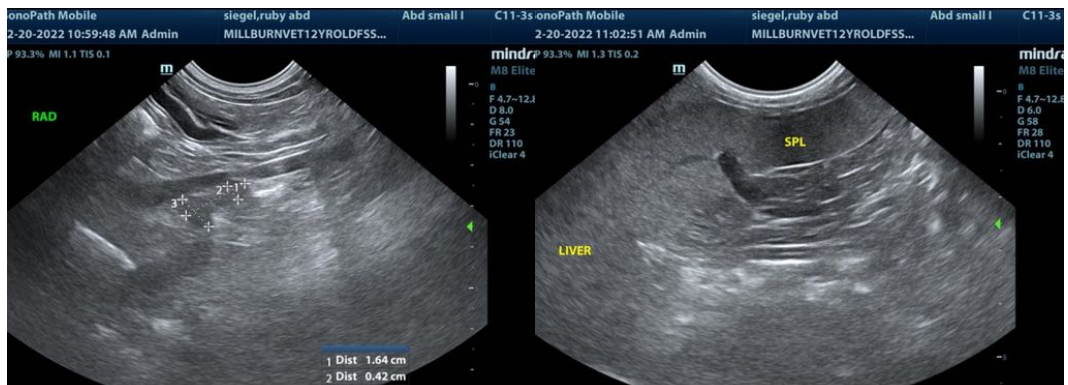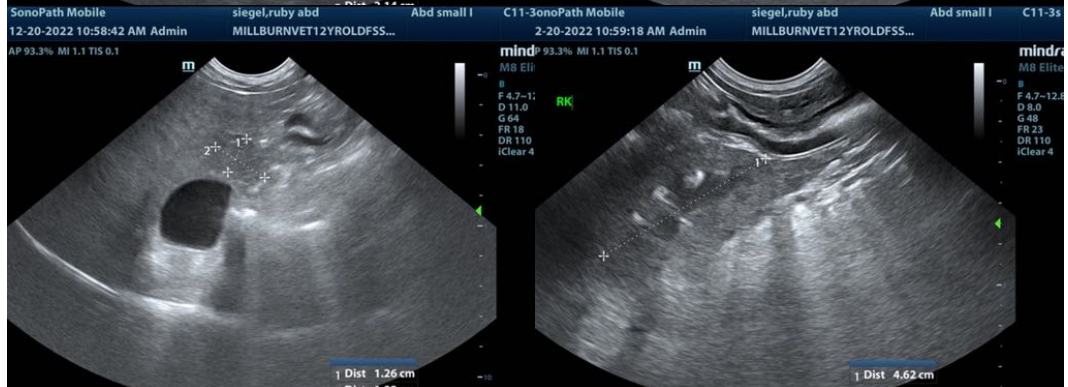
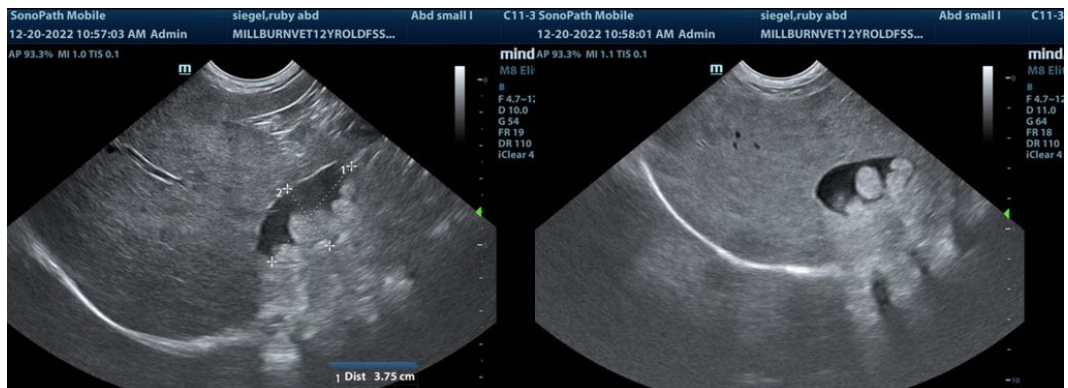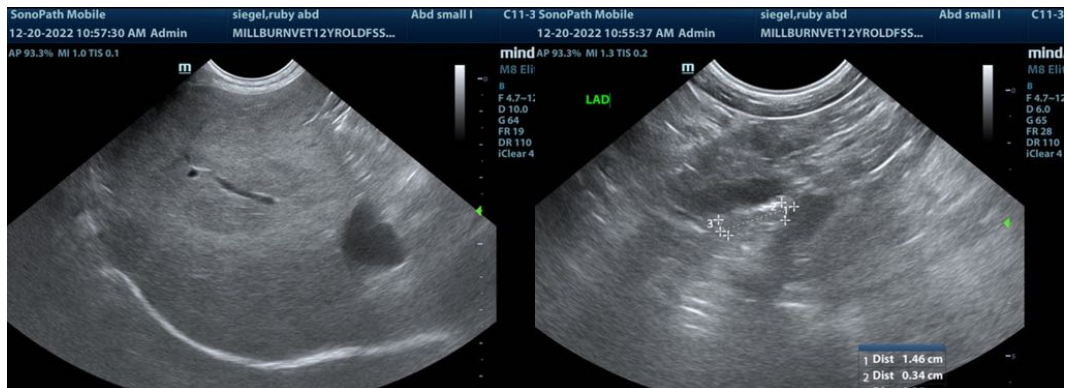
Dr. Turowsky

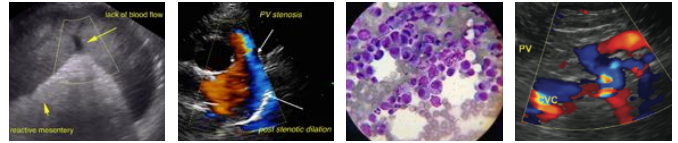
**INVOICE**

42247

**DATE**

12/20/22





**PATIENT**

Ruby Siegel

**SPECIES**

Canine

**BREED**

Miniature Schnauzer

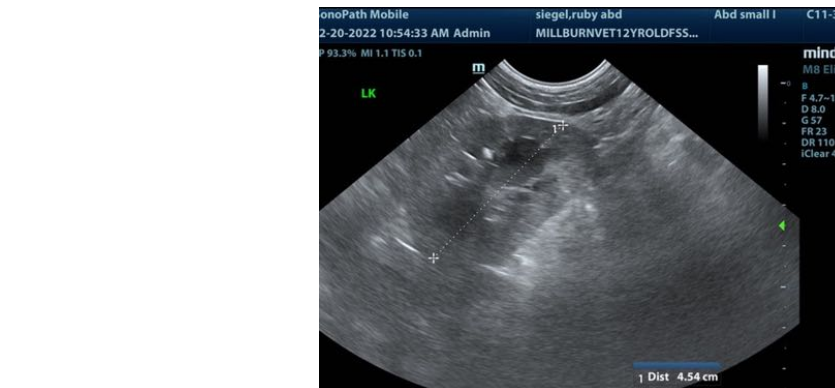**SEX**

Spayed female

**AGE**

12 years

**WEIGHT**



The information and recommendations provided are based on the images presented by the referring veterinarian/sonographer. No evaluation can be communicated regarding pathology that was not visible in the image/video clips provided.

Thank you for this referral. If the clinical or image interpretation does not parallel your findings or if I can be of any further assistance please contact me.

**Eric Lindquist**, DMV, DABVP, Cert. IVUSS, CEO of SonoPath.com

Info@SonoPath.com

**INTERPRETED BY**

**Eric Lindquist**, DMV,  
DABVP, Cert. IVUSS,  
CEO of SonoPath.com

**IMAGING  
PERFORMED BY**

Kelly Vazquez, CVT

**HOSPITAL NAME**

Millburn VH

**REFERRING VET**

Dr. Turowsky

**INVOICE**

42247

**DATE**

12/20/22