



PATIENT

Snowflake Moraski

PRESENTING CLINICAL SIGNS

History: Elevated BUN w/ + fecal occult blood. R/o GI mass. No current meds.
Abnormal PE/Chem/CBC/UA Results: BUN 50, Cl 1.0, Platelet 608

SPECIES

Canine

ULTRASONOGRAPHIC EXAMINATION OF THE ABDOMEN

Urinary System

BREED

Maltese Mix

The **urinary bladder**, trigone, and pelvic urethra presented normal thicknesses and normal tone. The ureters were not visible which is normal. No uroliths or sediment were visualized and anechoic urine was present. No evidence of inflammatory or neoplastic changes was noted. Ureteral papillae were normal.

SEX

Spayed female

The **kidneys** revealed largely normal size and structure, corticomedullary definition and ratio (cortex 1/3 of medulla) were essentially maintained with some age-related loss of curvilinear patterns regarding the capsule and C/M junction. The cortices presented largely uniform texture with some increased echogenicity expected for his age patient. Medullary structure differed distinctly from that of the cortex and no evidence of pelvic dilation was present. The right kidney measured 3.13 cm. The left kidney measured 3.5 cm.

AGE

13 years

WEIGHT

Adrenal Glands

The left **adrenal gland** was uniform and measured 1.52 x 0.68 cm at the caudal pole and 0.64 cm at the cranial pole. The right adrenal gland revealed a slightly expansive, hyperechoic nodule that is consistent with adenoma. The right adrenal measured 1.57 x 0.97 cm at the cranial pole and 0.67 cm at the caudal pole.

INTERPRETED BY

Eric Lindquist, DMV
DABVP, Cert. IVUSS

Spleen

The **spleen** presented a smooth homogeneous parenchyma hyperechoic to liver and renal cortical parenchyma. The capsule was smooth without noticeable expansion or deviation from within the spleen or adjacent pathology. The splenic vasculature demonstrated normal volume without signs of congestion or thrombosis. No sonographic evidence of acute or chronic inflammatory, neoplastic, or infarctual changes was noted.

IMAGING PERFORMED BY

Jessica Miller, RDMS

HOSPITAL NAME

Andover AH

Liver

REFERRING VET

Dr. Hummel

The **liver** images from right and left intercostal as well as subcostal views revealed subjectively normal liver size, contour, and structure. Some age-related parenchymal remodeling was noted but likely not clinically significant at this time. Vascular and biliary tracts were of normal volume and no evidence of congestion was noted. The gallbladder presented some dependent debris with essentially normal contour. The cystic and common bile ducts were normal. No overt evidence of active inflammatory, infiltrative or regenerative pathology was noted but should be paired with current or past LE elevations regarding any clinical significance to this presentation. The hepatic lymph nodes were unremarkable.

INVOICE

42207

DATE

12/19/22



PATIENT

Gastrointestinal

Snowflake Moraski

Examination of the **gastrointestinal tract** revealed a stomach and intestine free of stasis, of normal wall thickness, acceptable curvilinear mural detail, and peristaltic activity. Small and large intestine demonstrated normal luminal chyme and stool consistency respectively. No obstructive or overt infiltrative disease was noted. No associated abnormal lymphatic activity was noted.

SPECIES

Canine

BREED

Maltese Mix

Pancreas

The base and limbs of the **pancreas** were observed to be largely isoechoic to surrounding omental fat. Pancreatic duct and capsular contour were acceptably normal and parenchyma respected normal curvilinear patterns. No overt evidence of active inflammatory or neoplastic disease was noted.

SEX

Spayed female

ULTRASONOGRAPHIC FINDINGS

Age related adrenal glands with right adrenal adenoma.

AGE

13 years

Age related renal and hepatic changes.

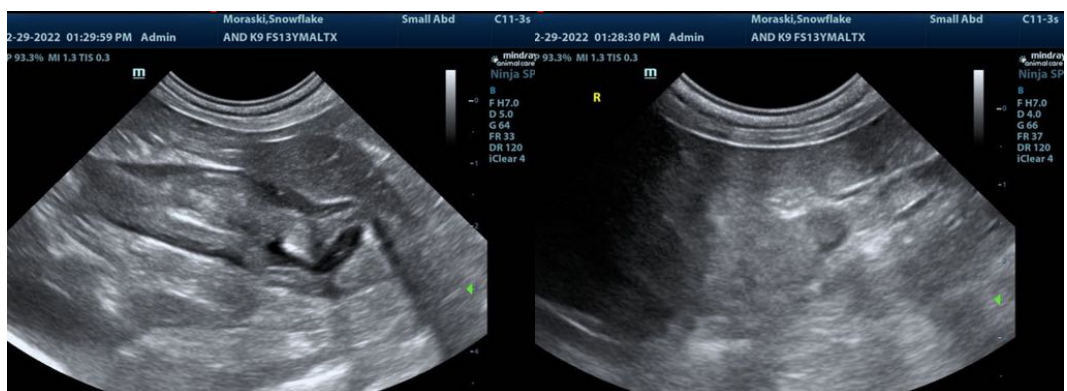WEIGHT

INTERPRETATION OF THE FINDINGS & FURTHER RECOMMENDATIONS

The kidneys do not appear end stage in this patient. Supportive care should prove effective. IV fluid support is recommended to correct azotemia.

INTERPRETED BY

Eric Lindquist, DMV
DABVP, Cert. IVUSS



IMAGING PERFORMED BY

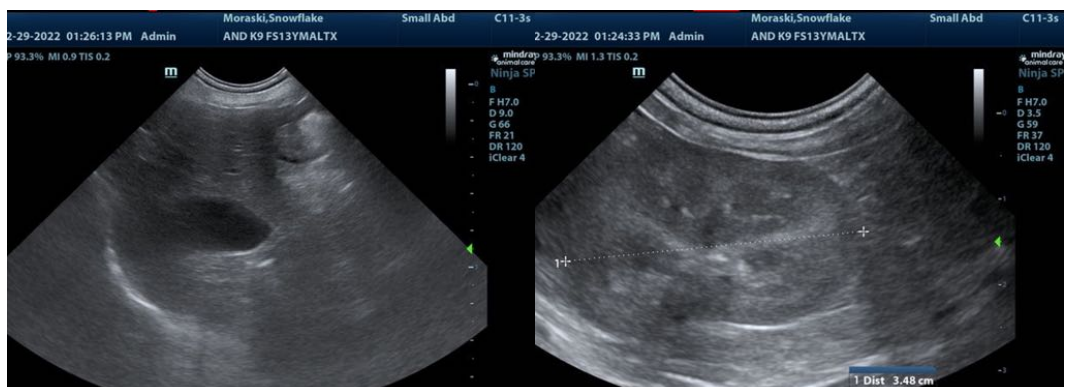
Jessica Miller, RDMS

HOSPITAL NAME

Andover AH

REFERRING VET

Dr. Hummel



INVOICE

42207

DATE

12/19/22



PATIENT

Snowflake Moraski

SPECIES

Canine

BREED

Maltese Mix

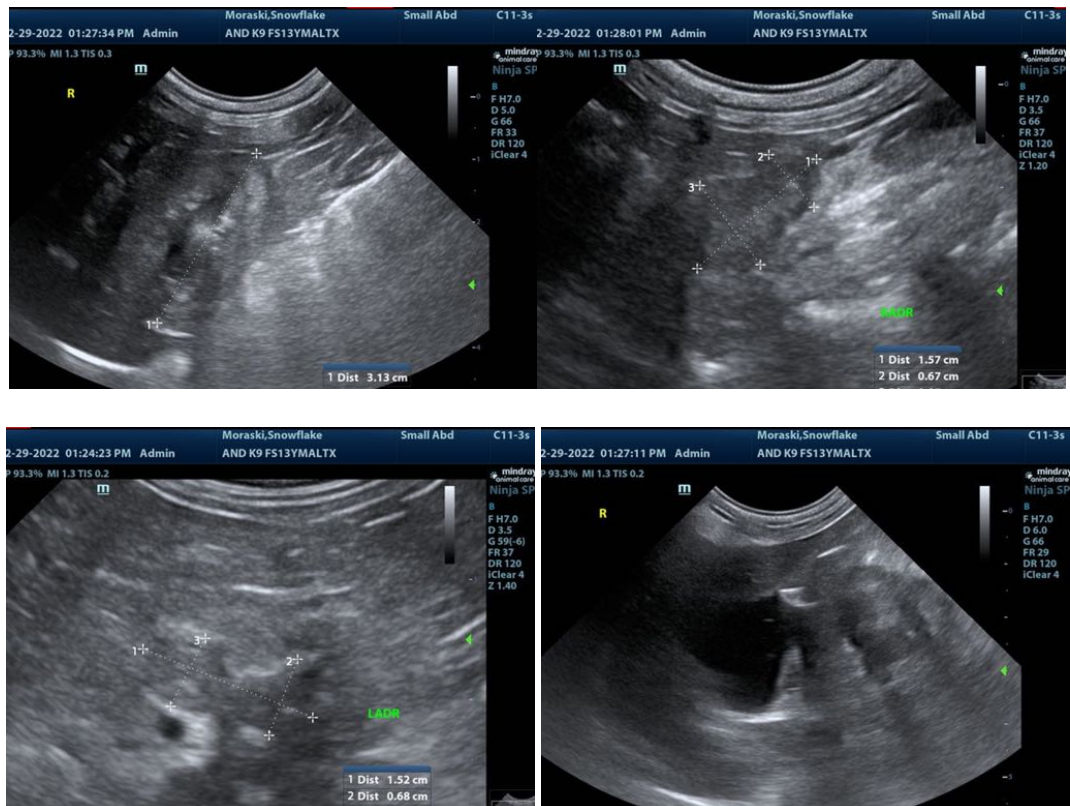
SEX

Spayed female

AGE

13 years

WEIGHT



INTERPRETED BY

Eric Lindquist, DMV
DABVP, Cert. IVUSS

The information and recommendations provided are based on the images presented by the referring veterinarian/sonographer. No evaluation can be communicated regarding pathology that was not visible in the image/video clips provided.

IMAGING PERFORMED BY

Jessica Miller, RDMS

Thank you for this referral. If the clinical or image interpretation does not parallel your findings or if I can be of any further assistance please contact me.

Eric Lindquist, DMV, DABVP, Cert. IVUSS, CEO of SonoPath.com
info@SonoPath.com

HOSPITAL NAME

Andover AH

REFERRING VET

Dr. Hummel

INVOICE

42207

DATE

12/19/22