



**PATIENT PRESENTING CLINICAL SIGNS**

Spyder Sicsko

History: Look for signs of GI lymphoma. Dx of ITP, bruising. On mycophenolate 500mg x 1/4 tab bid, prednisone

**SPECIES**

Abnormal PE/Chem/CBC/UA Results: WBC 44,000 with neutrophilia, monocytosis and lymphocytopenia. Alkp 208, precision PSL 185

Canine

**BREED**

**ULTRASONOGRAPHIC EXAMINATION OF THE ABDOMEN**  
*Urinary System*

Mix

The **urinary bladder**, trigone, and pelvic urethra presented normal thicknesses and normal tone. The pelvic urethra was imaged 2.0 cm beyond the cystourethral junction and appeared normal. The ureters were not visible which is normal. No uroliths or sediment were visualized and anechoic urine was present. No evidence of inflammatory or neoplastic changes was noted. Ureteral papillae were normal.

**SEX**

Spayed female

**AGE**

10 years

The **kidneys** revealed largely normal size and structure, corticomedullary definition and ratio (cortex 1/3 of medulla) were essentially maintained with some age-related loss of curvilinear patterns regarding the capsule and C/M junction. The cortices presented largely uniform texture with some increased echogenicity expected for his age patient. Medullary structure differed distinctly from that of the cortex and no evidence of pelvic dilation was present. The right kidney measured 6.04 cm.

**WEIGHT**

40 lbs

*Adrenal Glands*

**INTERPRETED BY**

Eric Lindquist, DMV  
DABVP, Cert. IVUSS

Both **adrenal glands** were heterogenous, yet measured within normal limits. The right adrenal gland measured 2.18 x 1.03 cm at the cranial pole and 0.5 cm at the caudal pole. The left adrenal gland measured 2.24 x 0.75 cm at the cranial pole and 0.75 cm at the caudal pole.

**IMAGING PERFORMED BY**

Diane McFadden, RVT

*Spleen*

The **spleen** presented a smooth homogeneous parenchyma hyperechoic to liver and renal cortical parenchyma. The capsule was smooth without noticeable expansion or deviation from within the spleen or adjacent pathology. The splenic vasculature demonstrated normal volume without signs of congestion or thrombosis. No sonographic evidence of acute or chronic inflammatory, neoplastic, or infarctual changes was noted.

**HOSPITAL NAME**

Animal Hospital of  
Roxbury

**REFERRING VET**

Dr. Flia

*Liver*

The **liver** images from right and left intercostal as well as subcostal views revealed subjectively normal liver size, contour, and structure. Some age-related parenchymal remodeling was noted but likely not clinically significant at this time. Vascular and biliary tracts were of normal volume and no evidence of congestion was noted. The gallbladder presented some dependent debris with essentially normal contour. The cystic and common bile ducts were normal. No overt evidence of active inflammatory, infiltrative or regenerative pathology was noted but should be paired with current or past LE elevations regarding any clinical significance to this presentation. The hepatic lymph nodes were unremarkable.

**INVOICE**

43133

**DATE**

12/15/22



**PATIENT** *Gastrointestinal*

Spyder Sicsko

Examination of the **gastrointestinal tract** revealed a stomach and intestine free of stasis, of normal wall thickness, acceptable curvilinear mural detail, and peristaltic activity. Small and large intestine demonstrated normal luminal chyme and stool consistency respectively. No obstructive or overt infiltrative disease was noted. No associated abnormal lymphatic activity was noted.

**SPECIES**

Canine

**BREED**

Mix

**Pancreas**

The base and limbs of the **pancreas** were observed to be largely isoechoic to surrounding omental fat. Pancreatic duct and capsular contour were acceptably normal and parenchyma respected normal curvilinear patterns. No overt evidence of active inflammatory or neoplastic disease was noted.

**SEX**

Spayed female

**ULTRASONOGRAPHIC FINDINGS**

Unremarkable abdomen.

**AGE**

10 years

Heterogenous adrenal glands.

Age related liver and kidneys.

**WEIGHT**

40 lbs

**INTERPRETATION OF THE FINDINGS & FURTHER RECOMMENDATIONS**

There was no evidence of clinical visceral disease. If the patient appears Cushingoid then work-up for pituitary dependent Cushing's can be considered.

**INTERPRETED BY**

Eric Lindquist, DMV  
DABVP, Cert. IVUSS

**IMAGING PERFORMED BY**

Diane McFadden, RVT

**HOSPITAL NAME**

Animal Hospital of  
Roxbury

**REFERRING VET**

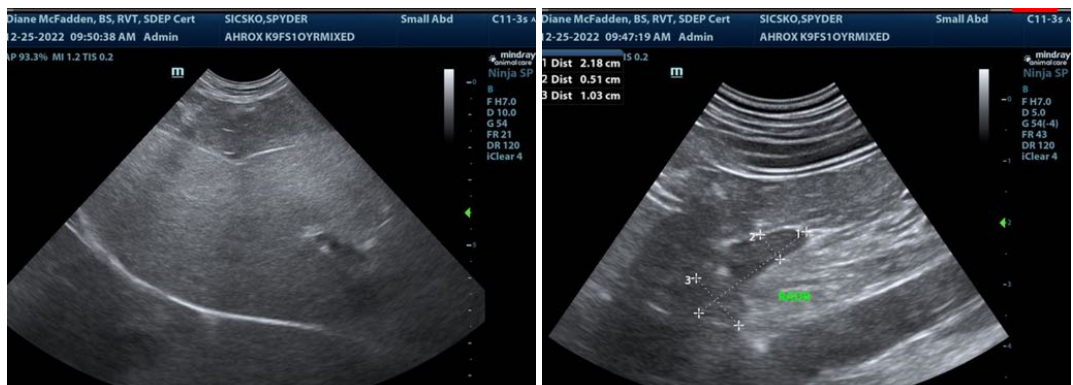
Dr. Flia

**INVOICE**

43133

**DATE**

12/15/22





**PATIENT**

Spyder Sicsko

**SPECIES**

Canine

**BREED**

Mix

**SEX**

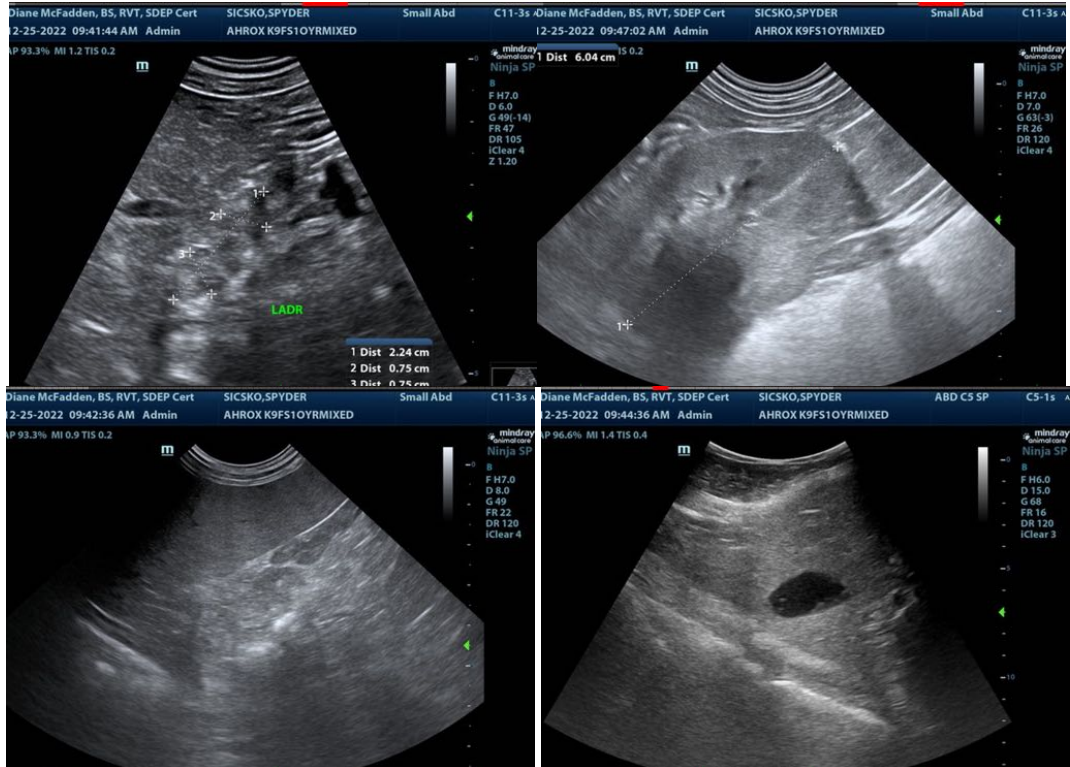
Spayed female

**AGE**

10 years

**WEIGHT**

40 lbs



**INTERPRETED BY**

Eric Lindquist, DMV  
DABVP, Cert. IVUSS

**IMAGING PERFORMED BY**

Diane McFadden, RVT

**HOSPITAL NAME**

Animal Hospital of  
Roxbury

**REFERRING VET**

Dr. Flia

**INVOICE**

43133

**DATE**

12/15/22

The information and recommendations provided are based on the images presented by the referring veterinarian/sonographer. No evaluation can be communicated regarding pathology that was not visible in the image/video clips provided.

Thank you for this referral. If the clinical or image interpretation does not parallel your findings or if I can be of any further assistance please contact me.

Eric Lindquist, DMV, DABVP, Cert. IVUSS, CEO of SonoPath.com  
Info@SonoPath.com