



PATIENT PRESENTING CLINICAL SIGNS

Otis Iradi History: Anesthesia for dental / g/R - heart murmur III/VI mitral. Current meds: KBioVet
Abnormal PE/Chem/CBC/UA Results: WNL

SPECIES ULTRASONOGRAPHIC EXAMINATION OF THE HEART

Canine

BREED

Shih Tzu Mix

SEX

Neutered male

AGE

12 years

WEIGHT

9.5 lbs

The echocardiogram in this patient demonstrated normal **left atrial** size based on 3 different LA measurement methods. Chamber volumes and echogenicity were normal. The cranial and caudal **mitral** valve leaflets presented vegetative thickening consistent with endocardiosis. Slight prolapse of the anterior mitral valve leaflet was noted. Doppler indicated measurable insufficiency. The **left ventricle** presented normal thicknesses with linear contour and was not dilated nor restricted. The **myocardium** presented normal echogenicity without subjective evidence of significant fibrotic or ischemic disease. **Contractility** of the ventricular walls was adequate and in normal range for this patient evidenced by the fractional shortening measurement and subjective evaluation of the different regions of the myocardium. The **left ventricular outflow** tract demonstrated normal laminar flow and subjective structural integrity. The **right atrium** and auricle revealed normal size, structure and content. No evidence of masses was noted or chamber overload. **Tricuspid** valvular assessment demonstrated adequate linear morphology. The **right ventricle** was of normal size (1/3 diameter of LV), chordae structure, myocardial echogenicity and thickness. **Pulmonic** tract assessment revealed normal valve structure, laminar flow, and diameter (approx. 1:1 pa/ao ratio). No visible **pericardial** or free pleura fluid was noted. No echographically detectable evidence of infiltrative disease was visible. The cranial **mediastinum and pericardial regions** were free of masses in the visible window.

INTERPRETED BY

Eric Lindquist, DMV
DABVP, Cert. IVUSS

IMAGING PERFORMED BY

Jessica Miller, RDMS

HOSPITAL NAME

Parsiappany AH

REFERRING VET

Dr. Dulude

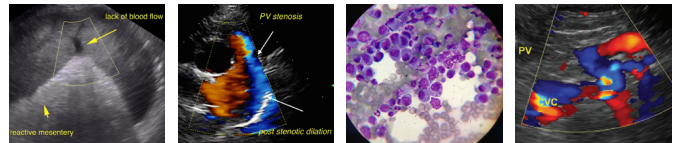
INVOICE

42392

DATE

11/8/22

| CANINE CARDIAC PARAMETERS | MR VMAX (m/s) | TR VMAX (m/s) | LA/AO (Boon method) | LA/AO (Heart Base; Swe) | FS (%) | EF (%) | EPSS (cm) |
|---------------------------------|---------------------|---------------------|------------------------|-------------------------------|--|--|--|
| NORMAL PARAMETER | 4.5-5.5 | <2.7 | 1.3 | <1.6 | 28-40 | 40-100 | <0.6 |
| PATIENT | 6.0 | 3.5 | 1.27 | 1.5 | 27 | 55 | 0.1 |
| CANINE CARDIAC PARAMETERS | HR (BPM) | AV VMAX (m/s) | PV MAX (m/s) | BODY WEIGHT | LA 2D short axis Base view (cm) | LVIDd Avg; 2D and m- mode short axis (cm) | LVIDs Avg; 2D and m-mode short axis (cm) |
| NORMAL PARAMETER | 50-100 | 0.7-1.7 | 0.7-1.6 | BELOW | BELOW | BELOW | BELOW |
| PATIENT | 136 | 1.06 | 0.84 | 9.5 lbs | 2.86 | 2.31 | |



PATIENT

Otis Iradi

ULTRASONOGRAPHIC FINDINGS

Stage B1 valvular disease with early pulmonary hypertension.

SPECIES

Canine

INTERPRETATION OF THE FINDINGS & FURTHER RECOMMENDATIONS

No therapy is recommended at this time.

BREED

Shih Tzu Mix

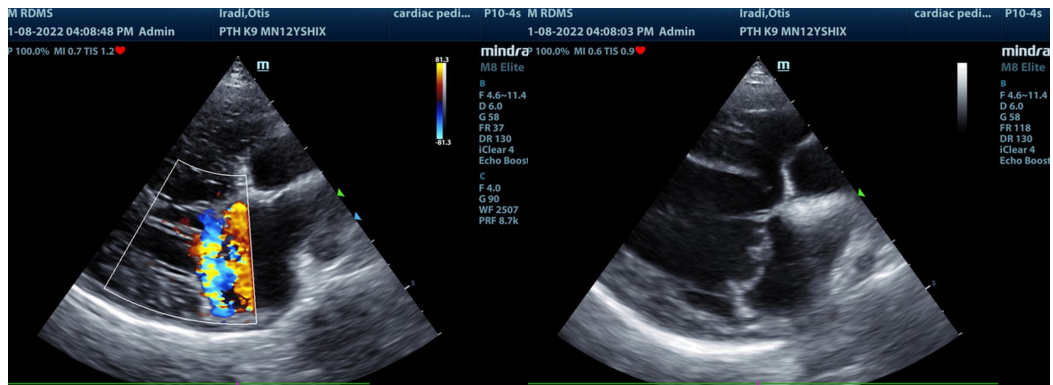
The heart is stable without clinical disease. No overt contraindication for anesthesia of brief to moderate duration. I suggest Torbutrol premed, Propofol induction, Isoflor maintenance or similar protocol if anesthesia is desired. Blood pressure recommended if not already performed and target white coat negative systolic pressure of < 160 mmHg. If higher than this ACE-inhibitor is suggested to reach this level. Recheck echocardiogram is recommended in 6 months, earlier if murmur grade increases or clinical signs initiate.

AGE

12 years

WEIGHT

9.5 lbs



INTERPRETED BY

Eric Lindquist, DMV
DABVP, Cert. IVUSS

IMAGING PERFORMED BY

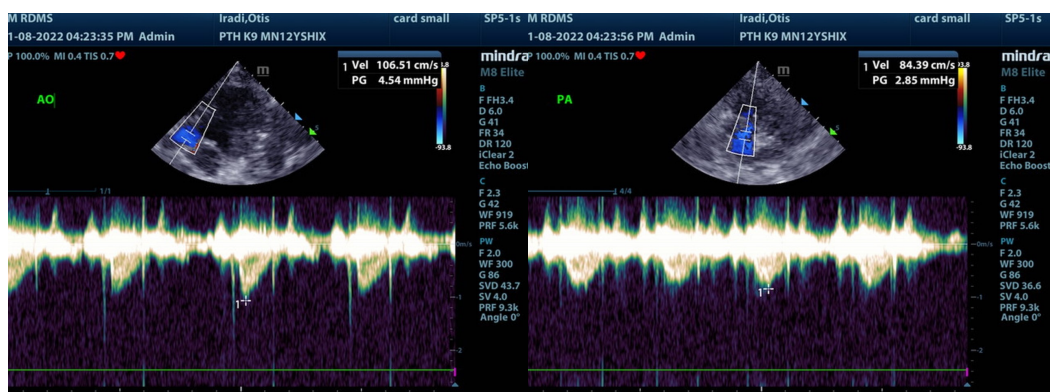
Jessica Miller, RDMS

HOSPITAL NAME

Parsiappany AH

REFERRING VET

Dr. Dulude

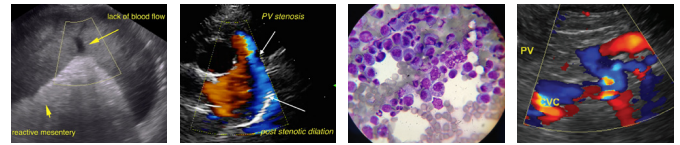


INVOICE

42392

DATE

11/8/22



PATIENT

Otis Iradi

SPECIES

Canine

BREED

Shih Tzu Mix

SEX

Neutered male

AGE

12 years

WEIGHT

9.5 lbs

INTERPRETED BY

Eric Lindquist, DMV
DABVP, Cert. IVUSS

IMAGING PERFORMED BY

Jessica Miller, RDMS

HOSPITAL NAME

Parsiappany AH

REFERRING VET

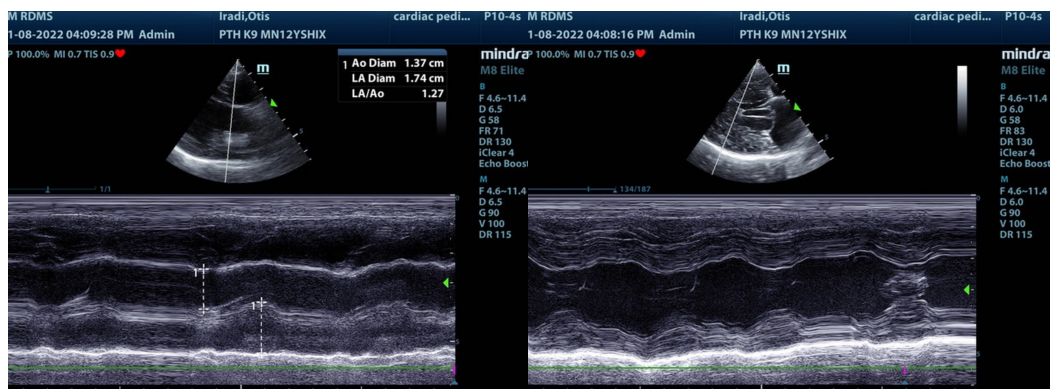
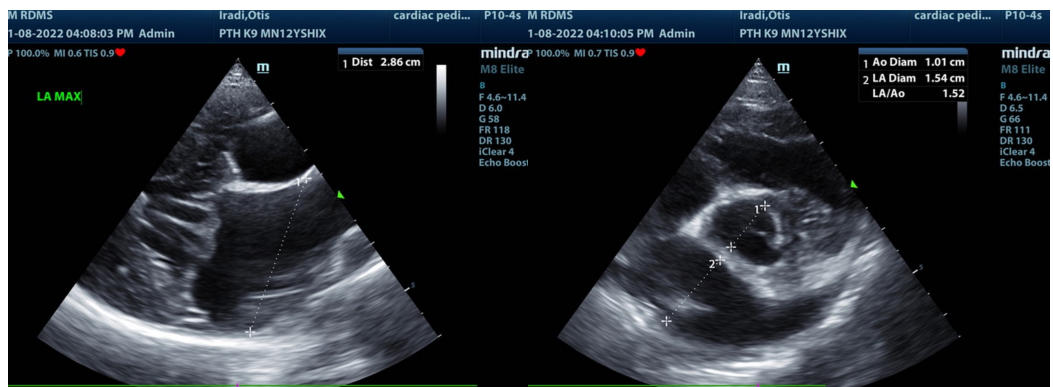
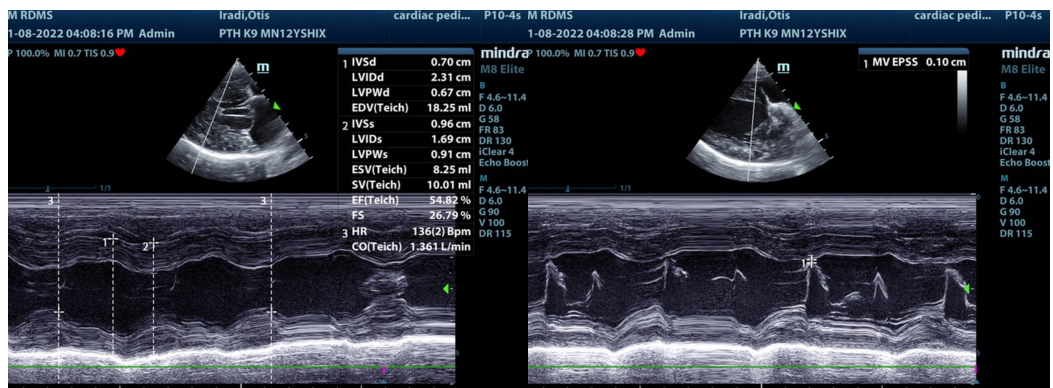
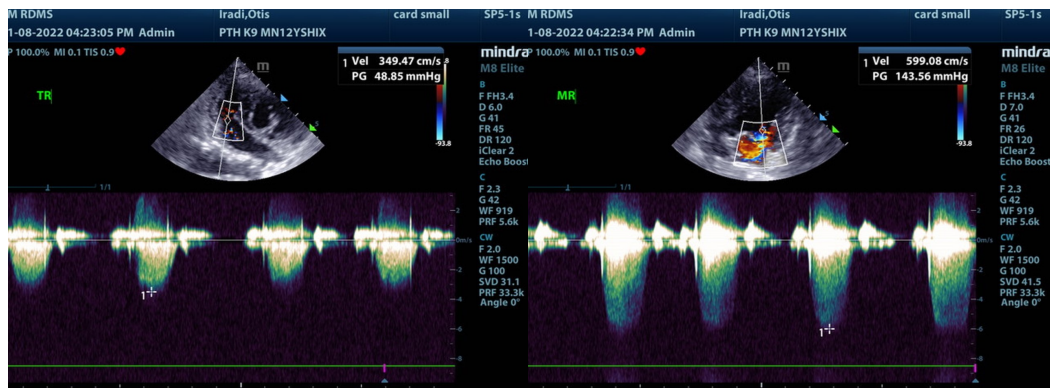
Dr. Dulude

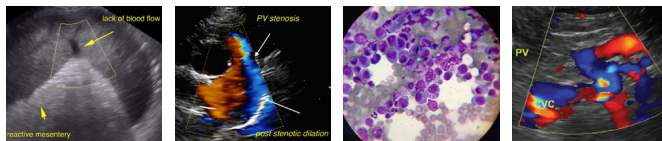
INVOICE

42392

DATE

11/8/22





PATIENT

Otis Iradi

The information and recommendations provided are based on the images presented by the referring veterinarian/sonographer. No evaluation can be communicated regarding pathology that was not visible in the image/video clips provided.

SPECIES

Canine

Thank you for this referral. If the clinical or image interpretation does not parallel your findings or if I can be of any further assistance please contact me.

Eric Lindquist, DMV, DABVP, Cert. IVUSS, CEO of SonoPath.com
info@SonoPath.com

BREED

Shih Tzu Mix

SEX

Neutered male

AGE

12 years

WEIGHT

9.5 lbs

INTERPRETED BY

Eric Lindquist, DMV
DABVP, Cert. IVUSS

**IMAGING
PERFORMED BY**

Jessica Miller, RDMS

HOSPITAL NAME

Parsiappany AH

REFERRING VET

Dr. Dulude

INVOICE

42392

DATE

11/8/22