



PATIENT PRESENTING CLINICAL SIGNS

Nala Mensah

History: Patient presented yesterday after vomiting food, fluid, and pieces of a dryer sheet. Ultrasound today to rule out possible FB. Radiographs yesterday did have a concerning gas pattern, but radiographs today look improved. Cat is QAR with a non-painful abdomen, she did eat a small amount last night with no further vomiting since then.

SPECIES

Feline

Abnormal PE/Chem/CBC/UA Results: RBC 13.47, HGB 16.7, MCV 37, MCH 12.4, reticulocyte HGB 14.6, bands 1638, lymphocytes 624, eosinophils 0, platelets 676, SDMA 18sodium 144, TCO2 23, creat. kin. 454. U/A: protein 2+, bacteria rare cocci <9 HPF.

BREED

Domestic Shorthair

ULTRASONOGRAPHIC EXAMINATION OF THE ABDOMEN

Urinary System

SEX

Spayed female

The **urinary bladder**, trigone, and pelvic urethra presented normal thicknesses and normal tone. The ureters were not visible which is normal. No uroliths or sediment were visualized and anechoic urine was present. No evidence of inflammatory or neoplastic changes was noted. Ureteral papillae were normal.

AGE

1 ½ years

The **kidneys** revealed normal size and structure, corticomedullary definition and ratio for this age. The cortices presented largely uniform texture with normal echogenic relationship to liver and spleen. Medullary structure differed distinctly from the cortex and no evidence of pelvic dilation was present. The capsules were acceptably uniform without significant irregularities. The right kidney measured 4.02 cm. The left kidney measured 3.72 cm. Power Doppler of the kidneys appeared to be slightly subnormal, yet this is subjective. Structurally the kidneys are unremarkable.

WEIGHT

15 lbs

INTERPRETED BY

Eric Lindquist, DMV,
DABVP, Cert. IVUSS,
CEO of SonoPath.com

Adrenal Glands

Both **adrenal glands** were visualized and recognized as having normal shape, size, position and echogenicity for this breed. The phrenic vasculature, glandular echogenicity and detail were unremarkable. Capsule, cortex, and medullary definition were normal for this age patient. The right adrenal gland measured 0.37 cm. The left adrenal gland measured 0.38 cm.

IMAGING PERFORMED BY

Kelly Vazquez, CVT

HOSPITAL NAME

Marsh AH

Spleen

The **spleen** presented a smooth homogeneous parenchyma hyperechoic to liver and renal cortical parenchyma. The capsule was smooth without noticeable expansion or deviation from within the spleen or adjacent pathology. The splenic vasculature demonstrated normal volume without signs of congestion or thrombosis. No sonographic evidence of acute or chronic inflammatory, neoplastic, or infarctual changes was noted.

REFERRING VET

Dr. Milwicki

INVOICE

42305

Liver

The **liver** images submitted revealed subjectively normal liver size, contour, and structure. Parenchymal echogenicity was naturally coarse and hypoechoic to the spleen. Vascular and biliary tracts were of normal volume with no evidence of congestion. The gallbladder presented acceptably thin walls with primarily anechoic content. The cystic and common bile ducts were normal. No pathological hepatic

DATE

11/3/22



PATIENT

lymphadenopathy was evident. No overt structural evidence of inflammatory, infiltrative or regenerative pathology was evident.

Nala Mensah

SPECIES

Gastrointestinal

Feline

Examination of the **gastrointestinal tract** revealed a stomach and intestine free of stasis, of normal wall thickness, acceptable curvilinear mural detail, and peristaltic activity. Small and large intestine demonstrated normal luminal chyme and stool consistency respectively. No obstructive or overt infiltrative disease was noted. No associated abnormal lymphatic activity was noted.

BREED

Domestic Shorthair

SEX

Spayed female

Pancreas

The base and limbs of the **pancreas** were observed to be largely isoechoic to surrounding omental fat. Pancreatic duct and capsular contour were acceptably normal and parenchyma respected normal curvilinear patterns. No overt evidence of active inflammatory or neoplastic disease was noted.

AGE

1 ½ years

ULTRASONOGRAPHIC EXAMINATION OF THE HEART

WEIGHT

15 lbs

The echocardiogram in this patient demonstrated normal **left atrial** size based on 3 separate LA measurements. The cranial and caudal **mitral** valve leaflets presented normal linear structure and kinetics. The **left ventricle** presented normal thicknesses with linear contour and was not dilated nor restricted. The **myocardium** presented normal echogenicity without subjective evidence of significant fibrotic or ischemic disease. **Contractility** of the ventricular walls was adequate and in normal range for this patient evidenced by the fractional shortening measurement and subjective evaluation of the different regions and angles of the myocardium. The **left ventricular outflow** tract demonstrated normal laminar flow and subjective structural integrity. The **right atrium** and auricle revealed normal size, structure and content. No evidence of masses was noted or chamber overload. **Tricuspid** valvular assessment demonstrated adequate linear morphology and kinetics. The **right ventricle** was of normal size (1/3 diameter of LV), chordae structure, myocardial echogenicity and thickness. **Pulmonic** tract assessment revealed normal valve structure, laminar flow, and diameter (approx. 1:1 pa/ao ratio). No visible **pericardial** or free pleura fluid was noted or extra cardiac pathology in the visible planes. The cranial **mediastinum and pericardial regions** were free of masses in the visible window.

INTERPRETED BY

Eric Lindquist, DMV,
DABVP, Cert. IVUSS,
CEO of SonoPath.com

IMAGING PERFORMED BY

Kelly Vazquez, CVT

HOSPITAL NAME

Marsh AH

REFERRING VET

Dr. Milwicki

INVOICE

42305

DATE

11/3/22



PATIENT
Nala Mensah

SPECIES
Feline

BREED
Domestic Shorthair

SEX
Spayed female

AGE
1 ½ years

FELINE CARDIAC PARAMETERS	BODY WEIGHT (kg)	HR (BPM)	IVSd (cm)	LVIDd (cm)	LVWd (cm)	FS (%)	EF (%)
NORMAL PARAMETER	-----	150-240	0.3-0.6	1.0-2.1	0.25-0.6	35-67	80-100
PATIENT		122	0.61	1.29	0.61	32	65
FELINE CARDIAC PARAMETERS	LA/AO (Boon)	LA/AO HEART BASE (Sisson)	LA 2D 4-chamber long axis AS to FW (Sisson) (cm)	LVOT VEL. (m/s)	RVOT VEL. (m/s)	IVRT (m)	
NORMAL PARAMETER	<1.5	0.88-1.79	0.7-1.7	<1.6	<1.3	40-60	
PATIENT	1.2	1.1	1.3	1.11	0.98	NM	
Adapted from June Boon, Veterinary Echocardiography, 1998 Sisson D et al. JVIM 1991; 5: 232, Jacobs et al. Am J Vet Res 1985; 46:1705							

ULTRASONOGRAPHIC FINDINGS

WEIGHT
15 lbs

Normal echocardiogram, no evidence of pathology.

Normal abdomen, no evidence of pathology and no evidence of foreign bodies.

INTERPRETED BY

Eric Lindquist, DMV,
DABVP, Cert. IVUSS,
CEO of SonoPath.com

INTERPRETATION OF THE FINDINGS & FURTHER RECOMMENDATIONS

Supportive care should prove effective.

IMAGING PERFORMED BY

Kelly Vazquez, CVT

HOSPITAL NAME

Marsh AH

REFERRING VET

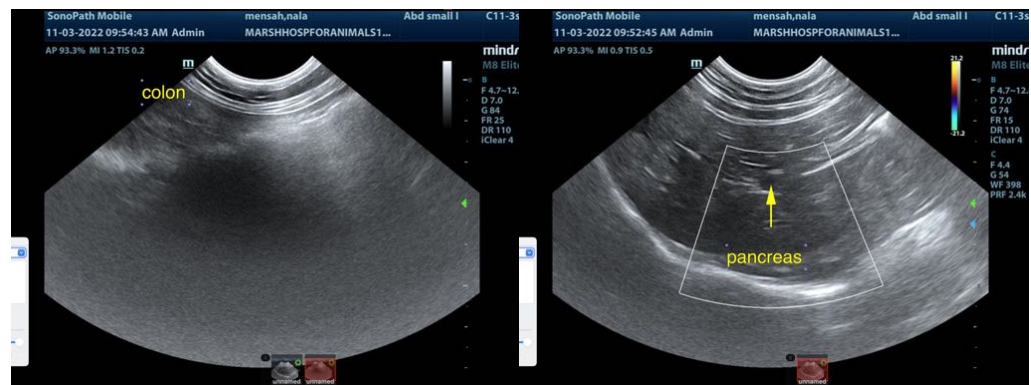
Dr. Milwicki

INVOICE

42305

DATE

11/3/22





PATIENT

Nala Mensah

SPECIES

Feline

BREED

Domestic Shorthair

SEX

Spayed female

AGE

1 ½ years

WEIGHT

15 lbs

INTERPRETED BY

Eric Lindquist, DMV,
DABVP, Cert. IVUSS,
CEO of SonoPath.com

IMAGING PERFORMED BY

Kelly Vazquez, CVT

HOSPITAL NAME

Marsh AH

REFERRING VET

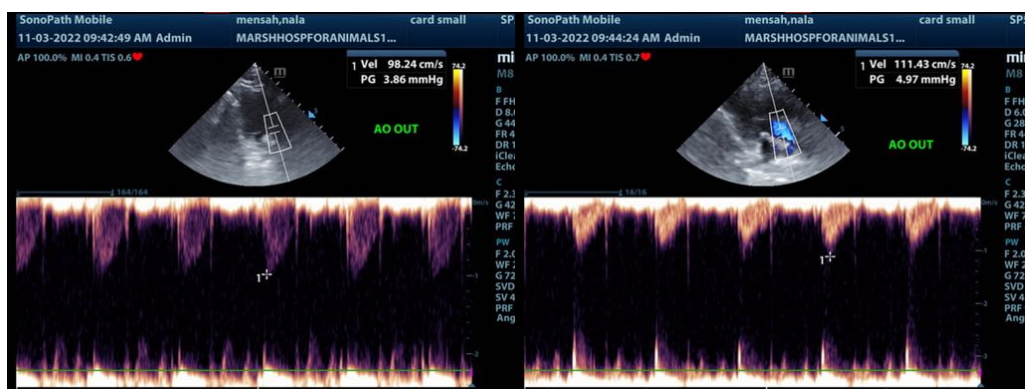
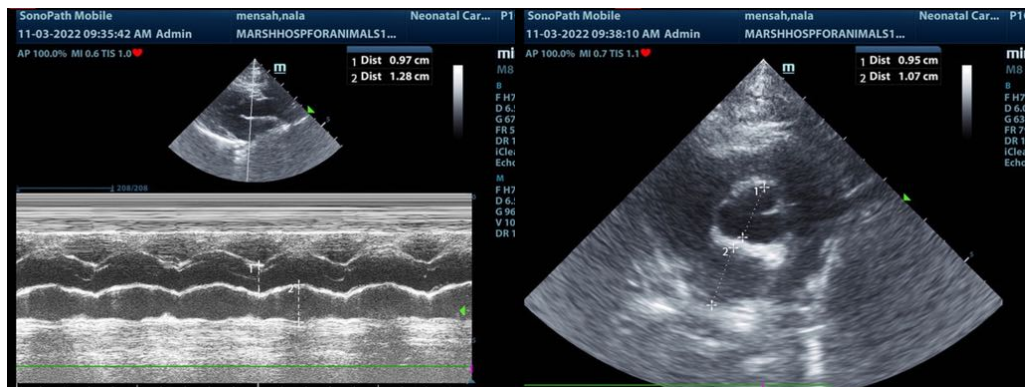
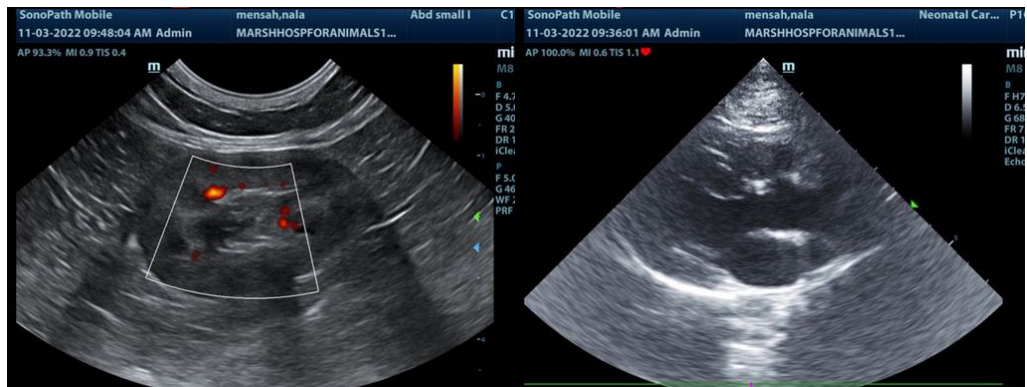
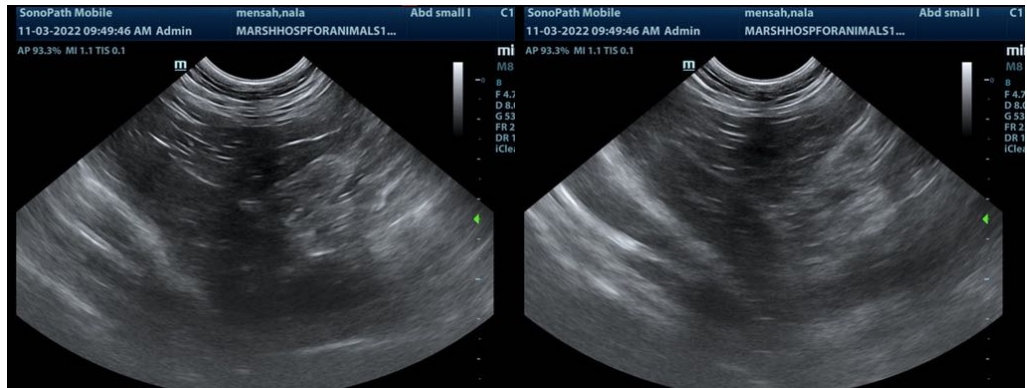
Dr. Milwicki

INVOICE

42305

DATE

11/3/22





PATIENT

Nala Mensah

SPECIES

Feline

BREED

Domestic Shorthair

SEX

Spayed female

AGE

1 ½ years

WEIGHT

15 lbs

INTERPRETED BY

Eric Lindquist, DMV,
DABVP, Cert. IVUSS,
CEO of SonoPath.com

IMAGING PERFORMED BY

Kelly Vazquez, CVT

HOSPITAL NAME

Marsh AH

REFERRING VET

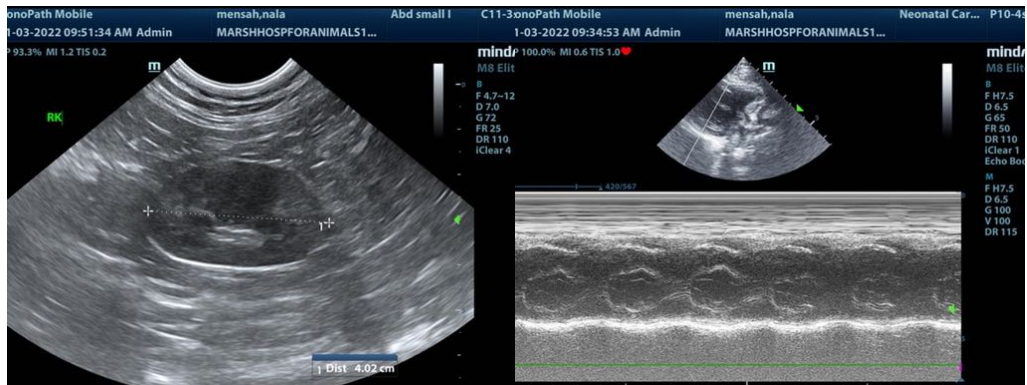
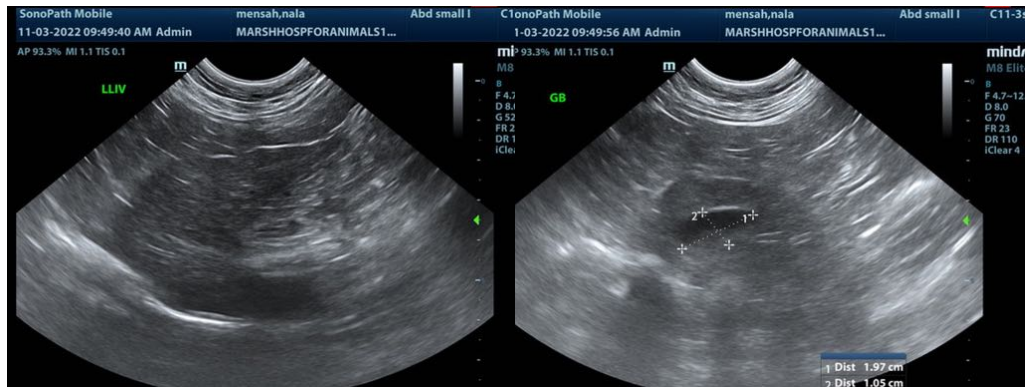
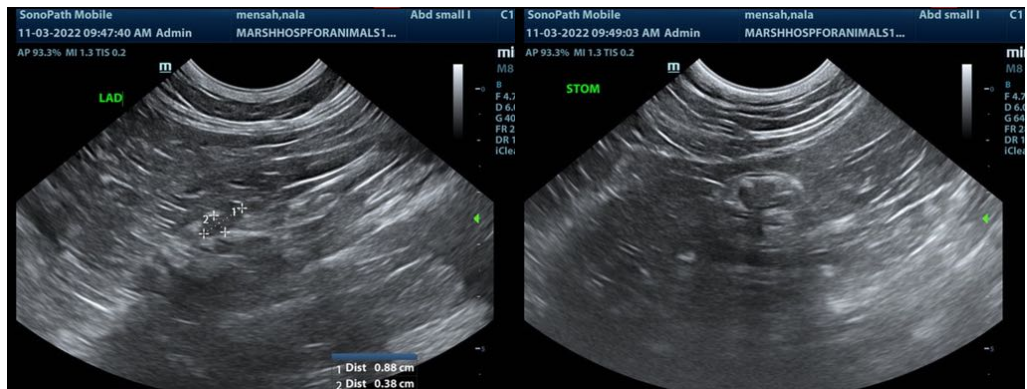
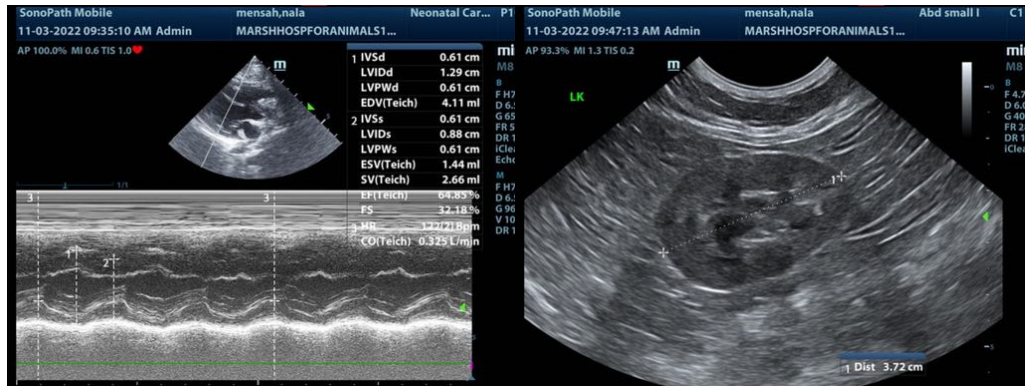
Dr. Milwicki

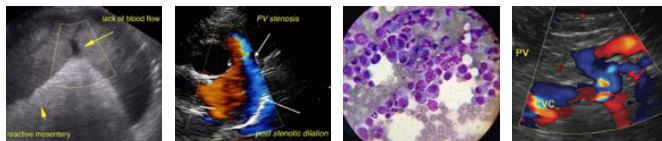
INVOICE

42305

DATE

11/3/22





PATIENT

Nala Mensah

SPECIES

Feline

The information and recommendations provided are based on the images presented by the referring veterinarian/sonographer. No evaluation can be communicated regarding pathology that was not visible in the image/video clips provided.

Thank you for this referral. If the clinical or image interpretation does not parallel your findings or if I can be of any further assistance please contact me.

BREED

Domestic Shorthair

Eric Lindquist, DMV, DABVP, Cert. IVUSS, CEO of SonoPath.com

Info@SonoPath.com

SEX

Spayed female

AGE

1 ½ years

WEIGHT

15 lbs

INTERPRETED BY

Eric Lindquist, DMV,
DABVP, Cert. IVUSS,
CEO of SonoPath.com

**IMAGING
PERFORMED BY**

Kelly Vazquez, CVT

HOSPITAL NAME

Marsh AH

REFERRING VET

Dr. Milwicki

INVOICE

42305

DATE

11/3/22